

**MENA BOULES, MD**Digestive Disease Institute,  
Cleveland Clinic**MADONNA MICHAEL, MD**Department of Internal Medicine,  
Cleveland Clinic**JULIETTA CHANG, MD**Digestive Disease Institute,  
Cleveland Clinic**BRUCE VROOMAN, MD**Department of Pain Management,  
Cleveland Clinic**MATTHEW KROH, MD**Digestive Disease Institute,  
Cleveland Clinic**MAGED RIZK, MD**Digestive Disease Institute,  
Cleveland Clinic

# Not all abdominal pain is gastrointestinal

A 31-YEAR-OLD WOMAN presents to the office with a chief complaint of right mid-abdominal pain that began 1 day ago. She says she did not seek medical attention earlier because she had to be at work that morning and she thought the pain would resolve on its own.

She reports no fever, headache, anorexia, nausea, vomiting, malaise, loss of weight, melena, or changes in bowel habits. She describes the pain as sharp, localized to the right side, and radiating to the vulva upon sitting up. She denies any association of pain with current dietary habits or bowel function. She has no recollection of precipitating or alleviating factors, including the use of analgesics to reduce the pain.

On further discussion, she mentions that 1 year ago she began experiencing chronic abdominal pain, which she says is sometimes exacerbated by coughing, by standing for extended periods of time, and during menses, and is alleviated upon lying down.

She has regular menstrual periods, and her last one ended 7 days ago.

Her surgical history includes two uncomplicated cesarean deliveries. She does not use tobacco, alcohol, or illicit substances. She is not aware of any allergies to drugs or foods.

She appears to be in no acute distress and has been sitting quietly thus far. She seems to have positioned her hand on her abdomen over the corresponding area of pain.

On physical examination, vital signs are within normal limits, and she is alert and oriented to person, place, and time. Her sclerae are anicteric, and the pupils are equal, round, and reactive to light.

Cardiovascular and pulmonary examinations are also within normal limits. Examination of the abdomen elicits tenderness and guarding along the lateral border of the rectus abdominis muscle on the right side at the level of umbilicus, with no rebound tenderness or rigidity. The liver and spleen are not enlarged, and no abdominal mass is detected. No skin rash, joint swelling, or peripheral edema is noted. A neurologic examination is normal.

**1** With the information provided, which of the following is least likely to be causing her symptoms?

- ☐ Chronic mesenteric ischemia
- ☐ Peptic ulcer
- ☐ Acute cholecystitis
- ☐ Slipping rib syndrome

**■ CHRONIC MESENTERIC ISCHEMIA**

Chronic mesenteric ischemia is the least likely diagnosis because the patient lacks risk factors for atherosclerosis and because she does not have postprandial pain, which is pathognomonic for chronic mesenteric ischemia. It is thought to be caused by a decrease in blood flow through the splanchnic vessels.<sup>1</sup> Symptoms tend to arise after eating because of a postprandial increase in metabolic demands.<sup>1</sup> These patients also often have atherosclerotic risk factors such as hypertension, hyperlipidemia, and smoking causing coronary artery disease, or a history of stroke.

The primary symptom is abdominal pain, most often described as achy, crampy, or spastic episodes of pain, usually occurring within 2 hours of eating.<sup>2</sup> Weight loss is common, as patients can develop a fear of eating. Post-

**Her complete blood cell count, metabolic panel, and initial imaging tests are normal**

doi:10.3949/ccjm.83a.14082

prandial pain may also be associated with nausea, vomiting, and bloating.

Findings on clinical examination are usually less severe than the actual symptoms. Visceral duplex or multidetector computed tomography (CT) is an excellent tool to detect blood flow in potential stenotic vessels.<sup>2</sup>

## ■ PEPTIC ULCER DISEASE

Peptic ulcer disease is not a likely diagnosis in this patient because she has no history of taking nonsteroidal anti-inflammatory drugs (NSAIDs).

A study of US patients between 1997 and 2007 reported an annual incidence of peptic ulcer disease of 0.05% to 0.19% depending on the method of diagnosis.<sup>3</sup> Peptic ulcer is thought to result from increased gastric acid secretion with a resultant inflammatory response, leading to erosion and ulceration.

The most common possible catalysts include *Helicobacter pylori* infection, NSAIDs, smoking, alcohol use, and hypersecretory states such as Zollinger-Ellison syndrome.<sup>4-6</sup> Complications include internal bleeding, perforation causing peritonitis, and penetration to adjacent organs.

## Pathophysiology

Peptic ulcer is the result of an increase in the normal level of gastric acid and a decrease in the protective ability of the gastric mucosa.<sup>7</sup> Cytoprotection may be lost through a decrease in the products of arachidonic acid metabolism (eg, prostaglandins, which have a protective effect) or an increase in leukotriene B<sub>4</sub> (LTB<sub>4</sub>), which has a damaging effect. Prostaglandins are thought not only to protect the normal gastric mucosa, but also to provide an antisecretory effect.

On the other hand, leukotrienes—specifically LTB<sub>4</sub> and LTC<sub>4</sub>—are proinflammatory agents and can damage the gastric mucosa. NSAIDs enhance the production of leukotrienes through the 5-lipoxygenase pathway. The ability of LTB<sub>4</sub> to cause degranulation and release of lysosomal enzymes may play a vital role in the inflammatory response to NSAIDs.<sup>8-10</sup> LTC<sub>4</sub> may promote gastric mucosal damage through a reduction of tissue perfusion resulting from the promotion of vascular stasis.<sup>8,11,12</sup>

## Symptoms help differentiate ulcer type

The classic symptom is burning epigastric pain after meals. Pain that occurs immediately after meals is a classic symptom of gastric ulcer. Pain that occurs 2 to 3 hours after meals and that is relieved by food or antacids is a strong indicator of duodenal ulcer.<sup>13</sup> Other symptoms include dyspepsia, bloating, distention, heartburn, and chest discomfort.<sup>13</sup>

Accurate diagnosis is vital in selecting the proper treatment. Diagnostic tests may include *H pylori* testing, upper-gastrointestinal endoscopy, and radiography with barium swallow.

## ■ CHOLECYSTITIS

In cholecystitis, the primary complaint is pain, usually in the right upper quadrant of the abdomen. Patients describe sudden, sharp, and intense pain that radiates to the back or shoulder. Patients may report pain after heavy meals, and some report nausea and vomiting. Cholecystitis is in the differential diagnosis of this patient because of the anatomic location of her pain.

The diagnosis is confirmed by imaging. Abdominal ultrasonography, technetium-99m hepatic iminodiacetic acid scanning, and CT are the most commonly used studies.<sup>14</sup>

Cholecystitis can be acute or chronic. Acute cholecystitis is categorized as calculous or acalculous. Calculous cholecystitis is multifactorial, but the primary cause is blockage of the cystic duct by gallstones.<sup>15</sup> Other factors include irritants such as lysolecithin (released during bile stasis), which can trigger gallbladder inflammation,<sup>15-17</sup> and infection.<sup>18</sup>

When the cystic duct is blocked, bile builds up inside the gallbladder, causing irritation and inflammation of the walls of the gallbladder.<sup>14</sup>

Acalculous cholecystitis, which resembles calculous cholecystitis but without the gallstones,<sup>19</sup> accounts for 2% to 15% of all cases of acute cholecystitis.<sup>19,20</sup> It has been observed in hospitalized critically ill patients, but it can also present in an outpatient setting, most often in elderly men with vascular disease.<sup>21</sup> Causes include infection, trauma, and tumor obstruction, resulting in endothelial injury, gallbladder stasis, ischemia, and eventually necrosis.<sup>14,20,22,23</sup>

A positive  
Carnett test  
helps rule out  
visceral  
involvement

## ■ SLIPPING RIB SYNDROME

Slipping rib syndrome, also known as Tietze syndrome, is believed to be caused by hypermobile costal cartilage. The affected rib slips behind the rib above on contraction of the abdominal wall. This displacement increases the probability of costal nerve impingement and tissue inflammation producing unilateral, sharp, subcostal and upper-abdominal pain.

In this patient, slipping rib syndrome is a possible diagnosis because of the location of the pain and because the pain described by the patient is highly suggestive of neuropathic pain.

Slipping rib syndrome is diagnosed clinically by a “hooking” maneuver: the clinician hooks his or her fingers at the patient’s subcostal area, reproducing the pain by movement of the ribs anteriorly.<sup>24</sup> When this test is performed in our patient the result is negative, ruling out slipping rib syndrome.

## ■ THE WORKUP CONTINUES

A complete blood cell count and comprehensive metabolic panel are within normal limits. Abdominal duplex ultrasonography reveals no celiac or mesenteric occlusions, thus ruling out chronic mesenteric ischemia.

Noncontrast CT shows no renal or ureteric stones and no evidence of bleeding in the urinary tract. CT with contrast shows no bowel distention, no evidence of hernia, and a normal appendix and ovaries.

**2** After exclusion of the previous choices, which of the following is the most likely cause of her symptoms?

- ☐ Anterior cutaneous nerve entrapment syndrome (ACNES)
- ☐ Ovarian cyst
- ☐ Renal stones
- ☐ Appendicitis
- ☐ Ventral hernia
- ☐ Median arcuate ligament syndrome

## ■ ANTERIOR CUTANEOUS NERVE ENTRAPMENT SYNDROME

ACNES is the most likely diagnosis. A study published in 2013 indicated that many cases of functional abdominal pain may actually be

undiagnosed cases of chronic abdominal wall pain such as ACNES.<sup>25</sup> The condition, first described in 1972,<sup>26</sup> is thought to be caused by thoracic cutaneous intercostal nerve entrapment between the abdominal muscles, causing pain at the point of entrapment.

The patient may present with pain that is either acute or chronic. Acute pain is localized more on the right side close to an old scar, or at the outer edge of the rectus abdominis muscle. The pain may vary from dull to burning to sharp; it can radiate horizontally in the upper half of the abdomen or obliquely in the lower half of the abdomen with movements such as twisting and sitting up.<sup>27</sup>

Despite the acute pain, patients are able to carry on daily functions. The pain may be alleviated by lying down.

The pain may be misdiagnosed as gynecologic or renal. In younger men, the pain may raise concern about hernia, and in older patients, cancer.<sup>27</sup> Patients may complain of chronic intermittent pain, usually unilateral, and to a lesser extent bilateral.<sup>27</sup>

The anatomic location of the pain usually reflects the intercostal nerve involved. The pain is not related to eating or to bowel movements.<sup>25</sup> Some patients report exacerbation upon coughing or standing, during menses, and with use of oral contraceptives.<sup>28,29</sup> When inquiring about surgical history, it is common to find that the patient has had multiple abdominal surgical procedures.

On examination, the patient has nondistressing pain, with a hand often placed over the painful area.<sup>27</sup> On firm palpation, a tender spot of less than 2 cm can be detected.

The diagnosis can be confirmed with a positive Carnett test. The patient lies supine on the examination table with the arms crossed over the chest, then elevates the head or the feet to tense the abdominal muscles.<sup>26,27</sup> If doing so reproduces the pain (ie, a positive test), this increases the suspicion of ACNES; if the pain decreases or is not reproducible, an intra-abdominal cause is more likely.

If the pain is difficult to localize, the “pinch test” can be done by using the thumb and index finger to pinch and lift the skin of the abdomen, including the subcutaneous layer of fat, first on one side and then on the other. This helps determine the side with greater pain.<sup>27</sup>

**If the pain is difficult to localize, the ‘pinch test’ can help determine the more painful side**

### ■ OVARIAN CYSTS

Ovarian cysts are fluid-filled sacs on the surface of or within the ovary. They are often benign and require no intervention. However, 5% to 10% of US women with a suspicious ovarian mass undergo a surgical procedure, and 13% to 21% of these are found to have a malignancy.<sup>30,31</sup>

Ovarian cysts are usually painless unless complicated by rupture or bleeding. Patients who present with pain describe it as dull and aching and in the abdomen or pelvis. In rare cases, ovarian cysts can be large enough to cause pain from torsion. Other symptoms may include delayed menses and bleeding outside of the menstrual period.<sup>32–34</sup>

Ovarian cysts are thought to be caused by hormonal changes during the menstrual cycle. They can be detected during pelvic examination or during pelvic ultrasonography. Cysts that are primarily fluid-filled are generally benign and require no intervention. On the other hand, cysts composed of solid material require intervention.

Treatment depends on several factors, including size and type of cyst, the patient's age, and whether torsion is present. Treatment can range from observation to medical or surgical management. Laparoscopic surgery is commonly used when surgical treatment is warranted.

### ■ RENAL STONES

From 10% to 15% of US adults develop a kidney stone at some time during their life.<sup>35</sup> There is no single cause, but one factor that promotes stone formation is a greater amount of crystal-forming substances in the urine, such as calcium, oxalate, and uric acid.<sup>36</sup> Most renal stones are calcium oxalate, uric acid, struvite, or cysteine.

Symptoms arise when the stone moves within the urinary tract. Patients present to the emergency room in severe distress, usually with flank pain that radiates to the lower abdomen or groin. The pain is episodic, fluctuates in intensity, and may present with dysuria, frequency, or urgency. It is also associated with nausea and vomiting.<sup>37</sup>

Renal stones are diagnosed through a series of laboratory and imaging studies. Imag-

ing studies include plain radiography (which can miss small stones), renal sonography, and computed tomography without contrast.

### ■ APPENDICITIS

In the United States, the lifetime risk of developing appendicitis is 8.6% in men and 6.7% in women.<sup>38</sup> Appendicitis is one of the most common reasons for emergency surgery.

Appendicitis is thought to result from obstruction by fecal matter blocking the opening of the appendix or from a viral infection (eg, with an adenovirus).<sup>39,40</sup> The resulting bacterial growth can cause the appendix to become inflamed and purulent.

Patients typically present with umbilical or epigastric pain radiating to the right lower quadrant of the abdomen. Over time, the pain becomes sharper. Certain movements can exacerbate the pain, and lying down may alleviate it. Other symptoms are nausea, vomiting, loss of appetite, and low-grade fever.

Findings on the abdominal examination that help to confirm the diagnosis include rigidity and tenderness, classically localized to a point two-thirds of the way from the umbilicus to the anterior superior iliac spine. Rebound tenderness is usually present. Up to 25% of cases in some series presented atypically, with variable location and findings on physical examination (eg, bowel irregularities, indigestion, flatulence, generalized malaise). In addition to the physical examination, laboratory testing and imaging (ultrasonography, CT) may aid in confirming the diagnosis of appendicitis or any other cause of the pain.<sup>38</sup>

### ■ VENTRAL HERNIA

Ventral hernia is a bulging of abdominal organs or other tissues through a defect of the musculature of the abdominal wall. Ventral hernia is categorized by its location as epigastric, abdominal, or incisional. An open abdominal procedure is the cause in nearly 10% of cases<sup>41</sup>; the herniation occurs with weakening of the surgical scar.

Ventral hernia is usually detected on physical examination, and patients may present after noting a bulge in the abdominal wall. Symptoms vary. Some patients have no symptoms, while others have mild abdominal

**A single injection may provide complete relief, but some patients require up to five**



discomfort or severe abdominal pain as well as nausea and vomiting. Imaging with CT, ultrasonography, or magnetic resonance imaging helps confirm the diagnosis. Complications of ventral hernia include incarceration and bowel strangulation.

### MEDIAN ARCuate LIGAMENT SYNDROME

Median arcuate ligament syndrome is a challenging diagnosis and a very rare cause of abdominal pain. It is thought to be caused by celiac artery compression by fibroligamentous bands. Pain fluctuates with respiration and is greater during expiration.

Patients may present with recurrent episodes of crampy postprandial pain that cause them to avoid eating, resulting in weight loss. The pain may be associated with nausea, vomiting, and bloating.

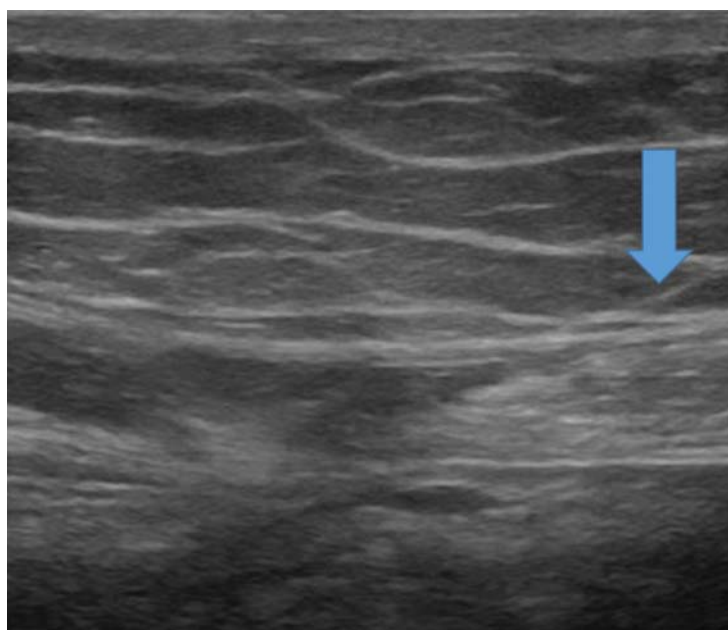
The diagnosis is confirmed by duplex ultrasonography, angiography, or magnetic resonance angiography. Treatment is surgical division of the fibroligamentous band and crus, and this is often done laparoscopically. In patients with severe persistent celiac artery stenosis, angioplasty and stenting may be considered.<sup>2</sup>

### CASE CONTINUED

Before the physical examination, our patient identifies the location of her pain. A Carnett test is performed, as for ACNES: the patient is placed in the supine position and is instructed to cross both arms over her chest. In an effort to promote muscle tension, she is asked to elevate her head off the examination table, as if performing a mini sit-up, and as she does this, pressure is applied to the identified tender area. The pain is easily reproduced, further confirming involvement of the abdominal wall rather than the viscera. After this, electromyography shows abnormal findings. The patient is then referred to the pain management clinic for a diagnostic nerve block.

**3** Which of the following is the first-line treatment of ACNES?

- ☐ Local injection of anesthetic
- ☐ Surgical neurectomy



**FIGURE 1.** After the needle is advanced just beyond the fascia and into the rectus abdominis muscle (arrow) under ultrasonographic guidance, 5 mL of 0.25% bupivacaine and 40 mg of triamcinolone are injected into the muscle, providing relief of the pain. An injection of 2% lidocaine may be done as a test block. Higher concentrations of anesthetic are to be avoided, as they may cause a motor block.

### LOCAL INJECTION OF ANESTHETIC

Local injection of anesthetic is the first-line treatment of ACNES.

Since ACNES is underdiagnosed, the patient may be less likely to be familiar with it. He or she should receive a detailed explanation of the condition and its management; this will help achieve a successful outcome.

Local anesthetic injection is used for both diagnosis and treatment; 2% lidocaine (or an equivalent) or dehydrated (absolute) alcohol or both can eliminate the pain caused by ACNES. The injection is commonly done under ultrasonographic guidance (**Figure 1**).<sup>42</sup>

Complete pain relief may be achieved with a single injection, but some patients require up to five injections.

The adjuvant use of corticosteroids in ACNES to reduce inflammation is controversial.

If anesthetic injections bring only minimal pain relief or if the patient has nerve entrapment in a scar, then surgical neurectomy is an

option.<sup>43</sup> The procedure is performed under local anesthesia, as the patient's response aids in identifying the specific nerve or nerves involved.

## RETURNING TO THE PATIENT

After a long discussion with our patient about ACNES and the treatment options, she agrees to undergo nerve block in the hope of relieving her pain. She receives a 0.5-mL injection of 2% lidocaine subcutaneously, and within minutes she reports relief of pain. She cannot believe that with a simple injection her pain was relieved. We advise her to return if her pain recurs or if new symptoms arise.

## REFERENCES

1. American Gastroenterological Association Medical Position Statement: Guidelines On Intestinal Ischemia. *Gastroenterology* 2000; 118:951–953.
2. Bobadilla JL. Mesenteric ischemia. *Surg Clin North Am* 2013; 93:925–940.
3. Sung JJ, Kuipers EJ, El-Serag HB. Systematic review: the global incidence and prevalence of peptic ulcer disease. *Aliment Pharmacol Ther* 2009; 29:938–946.
4. Najm WI. Peptic ulcer disease. *Prim Care* 2011; 38:383–394.
5. Malfertheiner P, Chan FK, McColl KE. Peptic ulcer disease. *Lancet* 2009; 374:1449–1461.
6. Chan FK, Leung WK. Peptic-ulcer disease. *Lancet* 2002; 360:933–941.
7. Bright-Asare P, Habte T, Yirgou B, Benjamin J. Prostaglandins, H2-receptor antagonists and peptic ulcer disease. *Drugs* 1988; 35(suppl 3):1–9.
8. Hudson N, Balsitis M, Everitt S, Hawkey CJ. Enhanced gastric mucosal leukotriene B4 synthesis in patients taking non-steroidal anti-inflammatory drugs. *Gut* 1993; 34:742–747.
9. Ford-Hutchinson AW, Bray MA, Doig MV, Shipley ME, Smith MJ. Leukotriene B, a potent chemokinetic and aggregating substance released from polymorphonuclear leukocytes. *Nature* 1980; 286:264–265.
10. Bokoch GM, Reed PW. Effect of various lipoxygenase metabolites of arachidonic acid on degranulation of polymorphonuclear leukocytes. *J Biol Chem* 1981; 256:5317–5320.
11. Whittle BJ, Oren-Wolman N, Guth PH. Gastric vasoconstrictor actions of leukotriene C4, PGF2 alpha, and thromboxane mimetic U-46619 on rat submucosal microcirculation in vivo. *Am J Physiol* 1985; 248:G580–G586.
12. Pihan G, Rogers C, Szabo S. Vascular injury in acute gastric mucosal damage. Mediator role of leukotrienes. *Dig Dis Sci* 1988; 33:625–632.
13. Ramakrishnan K, Salinas RC. Peptic ulcer disease. *Am Fam Physician* 2007; 76:1005–1012.
14. Parment S, Lynn C, Glass RM. JAMA patient page. Acute cholecystitis. *JAMA* 2003; 289:124.
15. Roslyn JJ, DenBesten L, Thompson JE Jr, Silverman BF. Roles of lithogenic bile and cystic duct occlusion in the pathogenesis of acute cholecystitis. *Am J Surg* 1980; 140:126–130.
16. Kaminski DL. Arachidonic acid metabolites in hepatobiliary physiology and disease. *Gastroenterology* 1989; 97:781–792.
17. Jivegård L, Thornell E, Svanvik J. Pathophysiology of acute obstructive cholecystitis: implications for non-operative management. *Br J Surg* 1987; 74:1084–1086.
18. Csendes A, Burdiles P, Maluenda F, Diaz JC, Csendes P, Mitru N. Simultaneous bacteriologic assessment of bile from gallbladder and common bile duct in control subjects and patients with gallstones and common duct stones. *Arch Surg* 1996; 131:389–394.
19. Barie PS, Fischer E. Acute acalculous cholecystitis. *J Am Coll Surg* 1995; 180:232–244.
20. Shapiro MJ, Luchtefeld WB, Kurzweil S, Kaminski DL, Durham RM, Mazuski JE. Acute acalculous cholecystitis in the critically ill. *Am Surg* 1994; 60:335–339.
21. Savoca PE, Longo WE, Zucker KA, McMillen MM, Modlin IM. The increasing prevalence of acalculous cholecystitis in outpatients. Results of a 7-year study. *Ann Surg* 1990; 211:433–437.
22. Gofrit O, Eid A, Pikarsky A, Lebensart PD, Pizov G, Rivkind A. Cholesterol embolisation causing chronic acalculous cholecystitis. *Eur J Surg* 1996; 162:243–245.
23. McChesney JA, Northup PG, Bickston SJ. Acute acalculous cholecystitis associated with systemic sepsis and visceral arterial hypoperfusion: a case series and review of pathophysiology. *Dig Dis Sci* 2003; 48:1960–1967.
24. Aeschlimann A, Kahn MF. Tietze's syndrome: a critical review. *Clin Exp Rheumatol* 1990; 8:407–412.
25. van Assen T, de Jager-Kievit JW, Scheltinga MR, Roumen RM. Chronic abdominal wall pain misdiagnosed as functional abdominal pain. *J Am Board Fam Med* 2013; 26:738–744.
26. Akhnikh S, de Korte N, de Winter P. Anterior cutaneous nerve entrapment syndrome (ACNES): the forgotten diagnosis. *Eur J Pediatr* 2014; 173:445–449.
27. Applegate WV. Abdominal cutaneous nerve entrapment syndrome (ACNES): a commonly overlooked cause of abdominal pain. *Perm J* 2002; 6:20–27.
28. Grover M. UNC Center for Functional GI & Motility Disorders. Chronic abdominal wall pain: a missed diagnosis. [www.med.unc.edu/ibs/files/educational-gi-handouts/Chronic%20Abdominal%20Pain.pdf](http://www.med.unc.edu/ibs/files/educational-gi-handouts/Chronic%20Abdominal%20Pain.pdf). Accessed September 9, 2015.
29. Greenbaum D, Dawson F, Watson R. Chronic abdominal wall pain (CAWP): a common but frequently overlooked disorder. Poster presented at the World Congress of Gastroenterology, Sydney, Australia, August 26–31, 1990.
30. National Institutes of Health Consensus Development Conference Statement. Ovarian cancer: screening, treatment, and follow-up. *Gynecol Oncol* 1994; 55:S4–S14.
31. Koonings PP, Campbell K, Mishell DR Jr, Grimes DA. Rela-

## KEEP ACNES IN MIND

ACNES is one of the most commonly misdiagnosed conditions of patients presenting to the outpatient clinic with acute or chronic abdominal pain. This is because the focus is directed to intra-abdominal causes. But if ACNES is kept in consideration from the beginning of the patient encounter, extensive testing, time, and patient anxiety may be reduced significantly. A simple physical examination and the Carnett test aid in raising suspicion of ACNES. If ACNES is confirmed, ultrasonographically guided local anesthetic injection is both diagnostic and therapeutic.

- tive frequency of primary ovarian neoplasms: a 10-year review. *Obstet Gynecol* 1989; 74:921–926.
32. **Givens V, Mitchell GE, Harraway-Smith C, Reddy A, Maness DL.** Diagnosis and management of adnexal masses. *Am Fam Physician* 2009; 80:815–820.
  33. **Goff BA, Mandel L, Muntz HG, Melancon CH.** Ovarian carcinoma diagnosis. *Cancer* 2000; 89:2068–2075.
  34. **Friedman GD, Skilling JS, Udaltsova NV, Smith LH.** Early symptoms of ovarian cancer: a case-control study without recall bias. *Fam Pract* 2005; 22:548–553.
  35. **Stamatelou KK, Francis ME, Jones CA, Nyberg LM, Curhan GC.** Time trends in reported prevalence of kidney stones in the United States: 1976–1994. *Kidney Int* 2003; 63:1817–1823.
  36. **Worcester EM, Coe FL.** Clinical practice. Calcium kidney stones. *N Engl J Med* 2010; 363:954–963.
  37. **Miller NL, Lingeman JE.** Management of kidney stones. *BMJ* 2007; 334:468–472.
  38. **Lewis SR, Mahony PJ, Simpson J.** Appendicitis. *BMJ* 2011; 343:d5976.
  39. **Lamps LW.** Infectious causes of appendicitis. *Infect Dis Clin North Am* 2010; 24:995–1018.
  40. **Reif RM.** Viral appendicitis. *Hum Pathol* 1981; 12:193–196.
  41. **Akkary E, Panait L, Roberts K, Duffy A, Bell R.** Sutureless laparoscopic ventral hernia repair in obese patients. *JSL* 2011; 15:154–159.
  42. **Boelens OB, Scheltinga MR, Houterman S, Roumen RM.** Randomized clinical trial of trigger point infiltration with lidocaine to diagnose anterior cutaneous nerve entrapment syndrome. *Br J Surg* 2013; 100:217–221.
  43. **Boelens OB, Scheltinga MR, Houterman S, Roumen RM.** Management of anterior cutaneous nerve entrapment syndrome in a cohort of 139 patients. *Ann Surg* 2011; 254:1054–1058.
- .....  
**ADDRESS:** Maged Rizk, MD, Digestive Disease Institute, A30, Cleveland Clinic, 9500 Euclid Avenue, Cleveland, OH 44195; e-mail: rizkm@ccf.org