

FARAYI MBUVAH, MD
Department of Internal Medicine,
Fairview Hospital, Cleveland, OH

VYSHAK ALVA VENUR, MD
Department of Internal Medicine,
Fairview Hospital, Cleveland, OH

GAURAV KISTANGARI, MD
Department of Hospital Medicine,
Cleveland Clinic

The Clinical Picture

An intravenous drug user with persistent dyspnea and lung infiltrates

A 58-YEAR-OLD MAN with a history of intravenous drug abuse, chronic hepatitis C, and anxiety presented to our emergency department twice in 4 weeks with progressive dyspnea and night sweats. He was a nonsmoker and had been an electrician for 15 years.

The first time he came in, chest radiography revealed bilateral reticulonodular infiltrates in the lung bases. He was treated with intravenous ceftriaxone (Rocephin) and azithromycin (Zithromax) for presumed community-acquired pneumonia and was then sent home on a 10-day course of oral amoxicillin-clavulanate (Augmentin). The antibiotics did not improve his symptoms, and 3 weeks later he presented again to the emergency department.

On his second presentation, he was in respiratory distress (oxygen saturation 78% on room air) and was afebrile and tachypneic. Physical examination revealed numerous injection marks or “tracks” on the skin of both arms, and auscultation revealed diminished intensity of breath sounds in both lung bases.

Repeat chest radiography demonstrated that the infiltrates were still there. Computed tomography was ordered and showed mild centrilobular emphysematous changes in both lungs, bibasilar opacifications, and a mass-like lesion (3.3 × 1.9 cm) in the right lower lobe (FIGURE 1).

He subsequently underwent bronchoscopy, which showed no endobronchial abnormalities. Transbronchial lung biopsy was performed, and histopathologic analysis of the specimen (FIGURE 2) revealed rodlike, birefringent crystals under polarized light, with an extensive foreign-body giant-cell reaction outside pulmonary capillaries, suggestive of intravascular pulmonary talcosis. Blood and sputum cultures were negative for pathologic organisms. Bronchoalveolar lavage samples were negative for pathologic organisms and malignant cells.

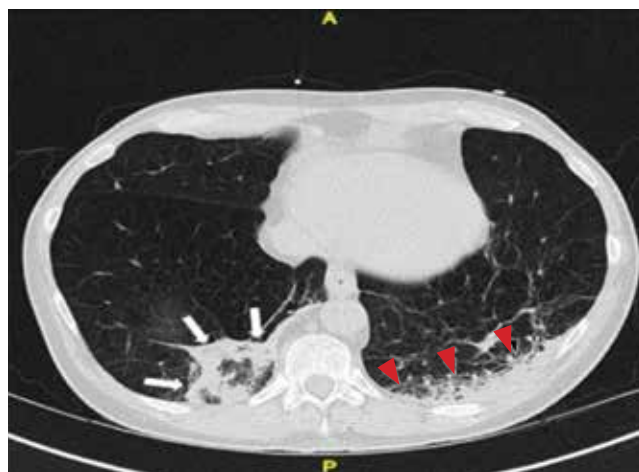


FIGURE 1. Computed tomography without contrast shows posterior focal opacification in the basilar segments of the right lower lobe (arrows). It has a mass-like appearance, with spiculated margins, and measures 3.3 × 1.9 cm. Focal opacification of the posterior medial basilar segments of the left lower lobe is also seen (red arrowheads). Both lungs show mild centrilobular emphysematous changes as well.

On further questioning, the patient revealed that he intravenously injected various drugs intended for oral use, such as crushed meperidine (Demerol), methyphenidate (Ritalin), and methadone tablets.

Pulmonary function tests indicated a severe obstructive pattern. The predicted forced expiratory volume in the first second of expiration (FEV₁) was 25%, and the ratio of FEV₁ to forced vital capacity was 27%.

Transthoracic echocardiography revealed mild pulmonary hypertension with a right ventricular systolic pressure of 28 mm Hg at rest.

Based on the results of the histologic examination, a diagnosis of intravascular pulmonary talcosis

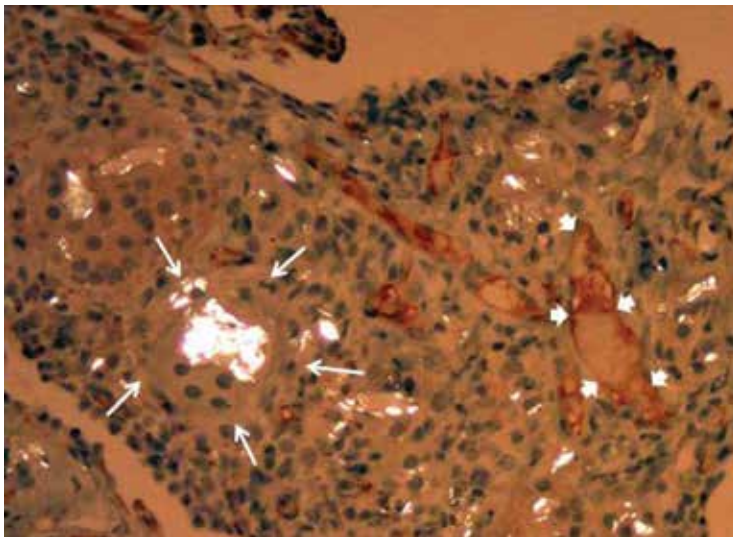


FIGURE 2. Movat pentachrome immunohistochemical staining (magnification $\times 200$) shows an extensive foreign-body giant-cell reaction to polarizable material (arrows) outside the pulmonary capillaries (arrowheads).

The patient revealed that he intravenously injected various drugs intended for oral use

was made. Antibiotics were discontinued, and treatment with albuterol and ipratropium bromide (Combivent) inhalers was started. The patient remained oxygen-dependent at the time of hospital discharge.

INTRAVASCULAR PULMONARY TALCOSIS

Intravascular pulmonary talcosis is seen predominantly in those who chronically inject intravenous drugs intended for oral use.^{1,2}

REFERENCES

1. Arnett EN, Battle WE, Russo JV, Roberts WC. Intravenous injection of talc-containing drugs intended for oral use. A cause of pulmonary granulomatosis and pulmonary hypertension. *Am J Med* 1976; 60:711–718.
2. Griffith CC, Raval JS, Nichols L. Intravascular talcosis due to intravenous drug use is an underrecognized cause of pulmonary hypertension. *Pulm Med* 2012; 2012:617531.
3. Chau CH, Yew WW, Lee J. Inhaled budesonide in the treatment of talc-induced pulmonary granulomatosis.

Many oral medications contain talc as a filler and lubricant to prevent the tablet from sticking to equipment during the manufacturing process. When oral medications containing talc are crushed, dissolved in water, and injected intravenously, the talc crystals and other particles lodge in the pulmonary vascular bed, resulting in microscopic pulmonary embolizations.

Over time, these particles migrate to the pulmonary interstitium and incite a foreign-body granulomatous reaction, which may be associated with progressive pulmonary fibrosis. The severity of this immune reaction and fibrosis may vary; hence, some patients remain asymptomatic, whereas some present with dyspnea from extensive fibrosis and pulmonary hypertension.

Persistent dyspnea along with persistent infiltrates on chest imaging in an intravenous drug abuser should prompt suspicion for intravascular pulmonary talcosis as well as consideration of other diagnoses, such as pneumonia, malignancy, and septic pulmonary emboli.

There is no established treatment for intravascular pulmonary talcosis; treatment is often supportive. A few studies and case reports have indicated varied success with systemic and inhaled corticosteroids.^{3–5} In extreme cases, lung transplantation may be necessary; however, this would require a comprehensive psychiatric assessment to minimize the risk of addiction relapse after transplantation.

Respiration 2003; 70:439.

4. Gysbrechts C, Michiels E, Verbeken E, et al. Interstitial lung disease more than 40 years after a 5 year occupational exposure to talc. *Eur Respir J* 1998; 11:1412–1415.
5. Marchiori E, Lourenço S, Gasparetto TD, Zanetti G, Mano CM, Nobre LF. Pulmonary talcosis: imaging findings. *Lung* 2010; 188:165–171.

ADDRESS: Farayi Mbuva, MD, Department of Internal Medicine, 18101 Lorain Avenue, Cleveland, OH 44111-5656; e-mail: mbuвахt@ccf.org