

TABLE OF CONTENTS

FROM THE EDITOR

Ebola—lessons still to be learned 708

So far, the disease has barely touched our country, but it has had a big impact on our health care system and our national psyche.

B.F. MANDELL

THE CLINICAL PICTURE

Sarcoidal infiltration of tattoos 717

Corticosteroid treatment resulted in clinical improvement after 3 months.

L. MIGUEL-GÓMEZ, S. VAÑO-GALVÁN, B. SIDO-AHMED,
C. MORENO GARCÍA DEL REAL, AND P. JAÉN-OLASOLO

SMART TESTING

When does an adult with headaches need central nervous system imaging? 719

Without red-flag symptoms, central nervous system imaging is unwarranted and may be harmful.

J. POST AND C. MORIATES

1-MINUTE CONSULT

Is antibiotic treatment indicated in a patient with a positive urine culture but no symptoms? 721

Some groups should be screened and treated, eg, pregnant women and patients undergoing an invasive urologic procedure.

M.T. HECKER AND C.J. DONSKEY

IM BOARD REVIEW

A 41-year-old man with abdominal pain 725

His symptoms and imaging findings suggested an infarction in the spleen, but what caused the infarction?

H. REHMAN

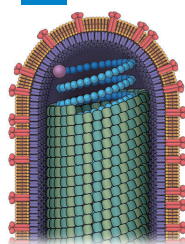


MEDICAL GRAND ROUNDS

Ebola virus: Questions, answers, and more questions 729

The clinical virology of Ebola virus, the reported proposed treatments, and an overview of the current outbreak.

K.D. BRIZENDINE



CONTINUED ON PAGE 707

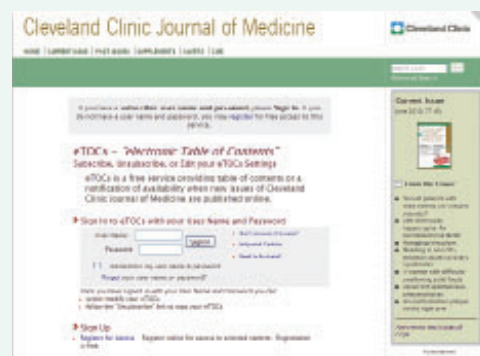CLEVELAND CLINIC JOURNAL OF MEDICINE

Online Features

Free e-mail alerts

To receive your free e-mail Table of Contents (eTOC) when a new issue of the *Cleveland Clinic Journal of Medicine* is released, just click on "Alerts" from any page at www.ccjm.org.

It is quick and easy. All you need is your e-mail address. No other registration information is required.



Social Networking

To post a *CCJM* article to Facebook or your favorite social networking site, just click on the icon at the bottom of any online article.



Scan with your mobile device to visit www.ccjm.org

Upcoming Features

- **Tuberculosis:**
Would you recognize it?
- **Cystic lung disease:**
Systematic diagnosis
- **Tobacco addiction:**
Helping your patients quit
- **Tailoring anticoagulation**
for atrial fibrillation
- **Denosumab:**
A newer osteoporosis drug
- **The genetics of hepatitis C**
- **When is it time**
to discuss driving
with older patients?
- **Is treating triglycerides**
worth the effort?



DEDICATED TO LIFELONG LEARNING
CLEVELAND
CLINIC
JOURNAL OF
MEDICINE

DECEMBER 2014

CONTINUED FROM PAGE 706

REVIEW 736

Identifying statin-associated autoimmune necrotizing myopathy

Unlike simple myalgia or myositis, this condition can persist or even arise de novo after the statin is stopped.

J. ALBAYDA AND L. CHRISTOPHER-STINE



REVIEW 742

Updated guidelines on cardiovascular evaluation before noncardiac surgery: A view from the trenches

The purpose is not to get clearance for surgery but to evaluate the patient's medical status and risk of complications.

S.L. COHN



EDITORIAL 752

Perioperative medicine: Combining the science and the art

Although we may wish for "cookbook" guidelines, often we must practice the "art" of medicine.

P.J. GRANT

REVIEW 755

Syncope: Etiology and diagnostic approach

There are three major types: neurally mediated, orthostatic, and cardiac. The goal is to rule out structural heart disease.

E.B. HANNA



PATIENT EDUCATION 767

Tilt-table testing

DEPARTMENTS 709

CME Calendar

Letters to the Editor 714

A reader comments on the risk of cancer with diabetes drugs (October 2014).

Directions for CME 768

To receive CME credit, read any or all of the CME-certified articles in this issue (those that carry the CME logo), then go to www.ccjm.org to take the test for the article or articles you select. It should take up to 1 hour to complete the activity for each article.

Release date: December 1, 2014

Expiration date: November 30, 2015