

TABLE OF CONTENTS

FROM THE EDITOR

A review of uncommon swelling provides useful reminders 261

Angioedema and the urticarias differ in their clinical manifestations and diagnostic and therapeutic implications.

B.F. MANDELL

THE CLINICAL PICTURE

Not all joint pain is arthritis 272

A 47-year-old man who was diagnosed with rheumatoid arthritis 5 years ago now has pleural effusions and abdominal pain.

G.S. KOCHHAR, M. RIZK, AND D.T. PATIL



IM BOARD REVIEW

A young woman with enlarged lymph nodes 276

A previously healthy 25-year-old woman presents with a "lump in the neck." How should she be assessed?

H. HUSSEINZADEH, C.V. COTTA, S. GORDON, AND A. LICHTIN

THE CLINICAL PICTURE

Hyperpigmented patches on the neck, shoulder, and back 290

A 17-year-old boy has had asymptomatic, unilateral hyperpigmented patches since birth. What is the diagnosis?

J.M. RIZZO, L.C. LOSS, AND I.L. ROTHMAN

CONTINUED ON PAGE 266

CLEVELAND CLINIC JOURNAL OF MEDICINE

Online Features

Free e-mail alerts

To receive your free e-mail Table of Contents (eTOC) when a new issue of the *Cleveland Clinic Journal of Medicine* is released, just click on "Alerts" from any page at www.ccm.org.

It is quick and easy. All you need is your e-mail address. No other registration information is required.

Social Networking

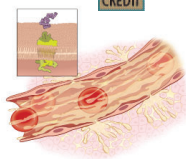
To post a *CCJM* article to Facebook or your favorite social networking site, just click on the icon at the bottom of any online article.



CONTINUED FROM PAGE 262



REVIEW



Recognizing and managing hereditary angioedema

297

Recognizing this rare but life-threatening disease is crucial, especially now that drugs are available to prevent and treat acute attacks.

K. TSE AND B.L. ZURAW



REVIEW

Preserving fertility in female cancer patients: A snapshot of the options

309

With the odds of surviving cancer improving, many young women facing therapy may first wish to take steps to ensure that they will still be able to bear children afterward.

I. SOAVE, G. LO MONTE, E. GIUGLIANO, A. GRAZIANO, AND R. MARCI



REVIEW

Aspirin: Its risks, benefits, and optimal use in preventing cardiovascular events

318

Aspirin's benefits in primary prevention are not as clear as in secondary prevention, particularly in people with diabetes, in women, and in the elderly.

K. PARK AND A.A. BAVRY

DEPARTMENTS

CME Calendar

317

Directions for taking CME tests online

327

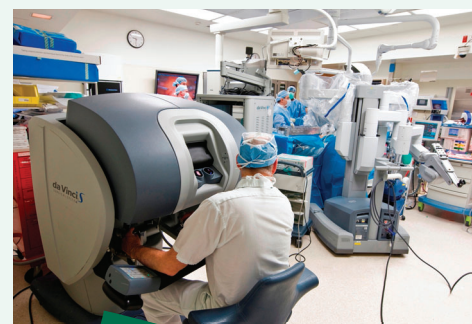To receive CME credit, read any or all of the CME-certified articles in this issue (those that carry the CME logo), then go to www.ccjm.org to take the test for the article or articles you select. It should take up to 1 hour to complete the activity for each article.

Release date: May 1, 2013

Expiration date: April 30, 2014

UPCOMING FEATURES

- **Calcium supplements and the guidelines: What do we tell patients?**
- **Incidental ovarian cysts: When to reassure, reassess, refer**
- **Does coronary calcification scoring still have a role?**
- **Managing severe acute pancreatitis**
- **What is the preferred revascularization strategy for patients with diabetes?**
- **Should all patients with portal vein thrombosis be anticoagulated?**
- **Is pharmacogenetic testing needed when prescribing warfarin?**



DEDICATED TO LIFELONG LEARNING

CLEVELAND
CLINIC
JOURNAL OF
MEDICINE