

# Functional anatomy of the facial nerve revealed by Ramsay Hunt syndrome

**V**ARICELLA-ZOSTER VIRUS (VZV) is a highly neurotropic and ubiquitous alpha-herpesvirus. Primary infection causes varicella (chickenpox), after which the virus becomes latent in ganglionic neurons along the entire neuraxis. Reactivation decades later usually results in zoster (shingles), pain with a dermatomal distribution, and rash. Unlike herpes simplex virus type 1 (HSV-1), which becomes latent exclusively in cranial nerve ganglia and reactivates to produce recurrent vesicular lesions around the mouth, and unlike HSV type 2, which becomes latent exclusively in sacral ganglia and reactivates to produce genital herpes, VZV may reactivate from any ganglia to cause zoster anywhere on the body.

---

*See related article, page 76*

---

Reactivation of VZV from the geniculate (facial nerve) ganglion leads to the Ramsay Hunt syndrome, ie, facial paralysis accompanied by a rash around the ear (zoster oticus). The syndrome is the second most common cause of atraumatic facial paralysis after Bell palsy (idiopathic facial paralysis). Importantly, virus reactivation from the geniculate ganglion may also be accompanied by zoster rash on the hard palate or on the anterior two-thirds of the tongue (**FIGURE 1**).<sup>1</sup> A rash in any of these three skin or mucosal sites in a patient with facial paralysis indicates geniculate ganglionitis. To his credit, Dr. J. Ramsay Hunt recognized that although there is no somatic sensory facial branch to the oropharynx or tongue, virus can still spread from a seventh cranial nerve element to the pharynx or, via special sensory fibers, to the tongue, thus providing an anatomic explanation for zoster rash in patients with

facial paralysis (geniculate zoster) not only around the ear, but also on the hard palate or on the anterior two-thirds of the tongue.<sup>2</sup>

In geniculate ganglionitis, a rash is usually seen in one but not all three of these skin and mucosal sites. Yet in this issue of the *Cleveland Clinic Journal of Medicine*, Grillo et al<sup>3</sup> describe a patient with facial palsy and rash in all three sites. This remarkable finding underscores the importance of distinguishing Ramsay Hunt syndrome from Bell palsy by checking for rash on the ear, tongue, and hard palate in any patient with acute unilateral peripheral facial weakness. Ramsay Hunt syndrome results from active VZV replication in the geniculate ganglion and requires treatment with antiviral drugs, whereas Bell palsy is usually treated with steroids. Steroid treatment of Ramsay Hunt syndrome misdiagnosed as Bell palsy can potentiate the viral infection. This may partially explain why the outcome of facial paralysis in Ramsay Hunt syndrome is not as good as in idiopathic Bell palsy, in which more than 70% of patients recover full facial function.

Although only cranial nerve VII (facial) was involved in their patient, Grillo et al correctly noted the frequent involvement of other cranial nerves in Ramsay Hunt syndrome. For example, dizziness, vertigo, or hearing loss indicative of involvement of cranial nerve VIII (acoustic) is most likely due to the close proximity of the geniculate ganglion and facial nerve to the vestibulocochlear nerve in the bony facial canal. Patients with this syndrome may also develop dysarthria or dysphagia indicative of lower cranial nerve involvement, reflecting the shared derivation of the facial, glossopharyngeal, and vagus nerves from the same branchial arch. Magnetic resonance imaging, not usually performed in patients with Ramsay Hunt syndrome, may show enhancement in the geniculate

ganglion as well as in the intracanalicular and tympanic segments of the facial nerve during its course through the facial canal.

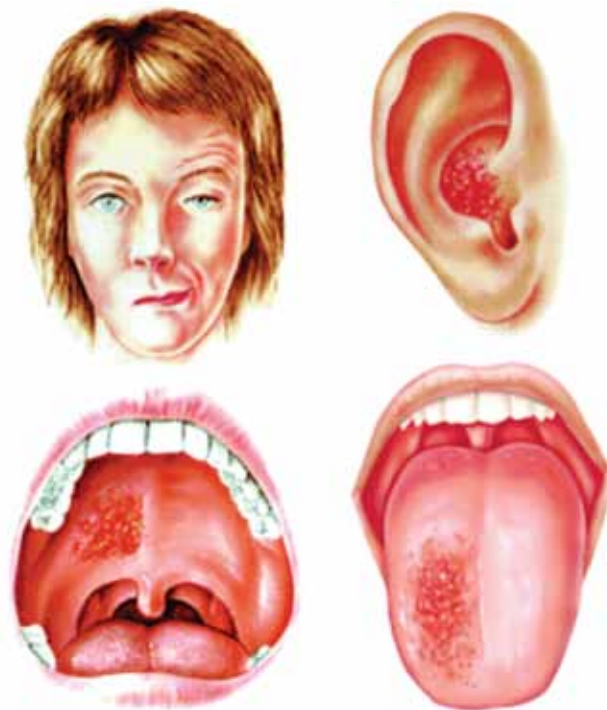
The report by Grillo et al comes at an auspicious time, 100 years after an enlightening series of papers by Dr. Hunt from 1907 to 1915 in which he described herpetic inflammation of the geniculate ganglion,<sup>4</sup> the sensory system of the facial nerve,<sup>5</sup> and ultimately the syndrome that bears his name.<sup>2,6</sup> Dr. Hunt received his doctorate from the University of Pennsylvania in 1893 and later became instructor at Cornell University School of Medicine. In 1924, he became full professor at Columbia University School of Medicine. A clinician of Olympian stature, he is also credited with describing two additional syndromes (clinical features produced by carotid artery occlusion and dyssynergia cerebellaris progressiva), although the best known is zoster oticus with peripheral facial palsy.

Importantly, some patients develop peripheral facial paralysis without any rash but with a fourfold rise in antibody to VZV or in association with the presence of VZV DNA in auricular skin, blood mononuclear cells, middle ear fluid, or saliva, indicating that a proportion of patients with Bell palsy have “Ramsay Hunt syndrome zoster sine herpete” or, more accurately, “geniculate zoster sine herpete.” Treatment of such patients with acyclovir-prednisone within 7 days of onset has been shown to improve the outcome of facial palsy.

Because it is now clear that geniculate ganglionitis may present with facial palsy and zoster rash in any or all of three sites, it may be time to call peripheral facial paralysis associated with zoster rash on the ear, tongue, or palate exactly what it is: geniculate zoster. After all, zoster rash on the face is called trigeminal zoster, and zoster rash on the chest is called thoracic zoster. Most important, however, is the recognition that facial paralysis in association with rash on the ear, tongue, or hard palate reflects geniculate zoster and requires immediate antiviral treatment. ■

## REFERENCES

1. Sweeney CJ, Gilden DH. Ramsay Hunt syndrome. *J Neurol Neurosurg Psychiatry* 2001; 71:149–154.
2. Hunt JR. The symptom-complex of the acute posterior poliomyelitis of the geniculate, auditory, glossopharyngeal and pneumogastric ganglia. *Arch Intern Med* 1910; 5:631–675.
3. Grillo E, Miguel-Morrondo A, Vano-Galvan S, Jaen P. A 54-year-old woman with odynophagia, peripheral facial nerve paralysis and mucocutaneous lesions. *Cleve Clin J Med* 2013; 80:76–77.
4. Hunt JR. On herpetic inflammations of the geniculate ganglion: a new syndrome and its complications. *J Nerv Ment Dis* 1907; 34:73–96.
5. Hunt JR. The sensory system of the facial nerve and its symptomatology. *J Nerv Ment Dis* 1909; 36:321–350.



**FIGURE 1.** Clinical features of Ramsay Hunt syndrome. Note peripheral facial weakness characterized by a widened palpebral fissure and decreased forehead wrinkling and smile on the right, associated with vesicles in the ipsilateral ear, on the hard palate, or on the anterior two-thirds of the tongue. Four nuclei are involved in facial nerve function: the motor nucleus of VII, the nucleus of the solitary tract, the superior salivatory nucleus, and the spinal nucleus of V. The solitary tract receives special visceral afferent taste fibers emanating from the anterior two-thirds of the tongue, cell bodies of which are in the geniculate ganglion, ie, the site of varicella-zoster virus reactivation when vesicles erupt on the tongue. The spinal nucleus of V receives general somatic afferent fibers from the geniculate zone of the ear via the chorda tympani. Cell bodies of those neurons are located in the geniculate ganglion and are the site of varicella-zoster virus reactivation in classic Ramsay Hunt syndrome, in which vesicular eruptions in geniculate zones are seen.

REPRINTED FROM SWEENEY CJ, GILDEN DH. RAMSAY HUNT SYNDROME. *J NEUROL NEUROSURG PSYCHIATRY* 2001; 71:149–154. WITH PERMISSION FROM BMJ PUBLISHING GROUP LTD.

6. Hunt JR. The sensory field of the facial nerve: a further contribution to the symptomatology of the geniculate ganglion. *Brain* 1915; 38:418–446.

**ADDRESS:** Don Gilden, MD, Department of Neurology, University of Colorado School of Medicine, 12700 E. 19th Avenue, Box B182, Aurora, CO 80045; e-mail don.gilden@ucdenver.edu.