

THE CLINICAL PICTURE

MOHAMMED A. R. CHAMSI-PASHA, MBBS

Department of Internal Medicine, Cleveland Clinic

ABDUL HAMID ALRAIYES, MD

Department of Pulmonary, Critical Care, and
Environmental Medicine, Tulane University
Health Sciences Center, New Orleans, LA

IHSAN MAMOUN, MD

Imaging Institute, Cleveland Clinic

M. CHADI ALRAIES, MD

Clinical Assistant Professor of
Medicine, Cleveland Clinic Lerner
College of Medicine of Case Western
Reserve University, Cleveland, OH,
and Department of Hospital Medicine,
Cleveland Clinic

The Clinical Picture

Peripheral opacity on plain chest radiography

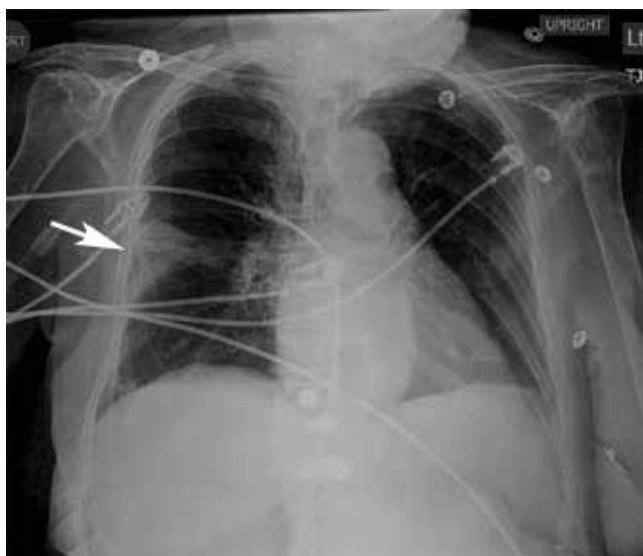


FIGURE 1. Anteroposterior chest radiography showed a Hampton hump (arrow), here a 3-cm wedge-shaped opacity in the right middle thorax.

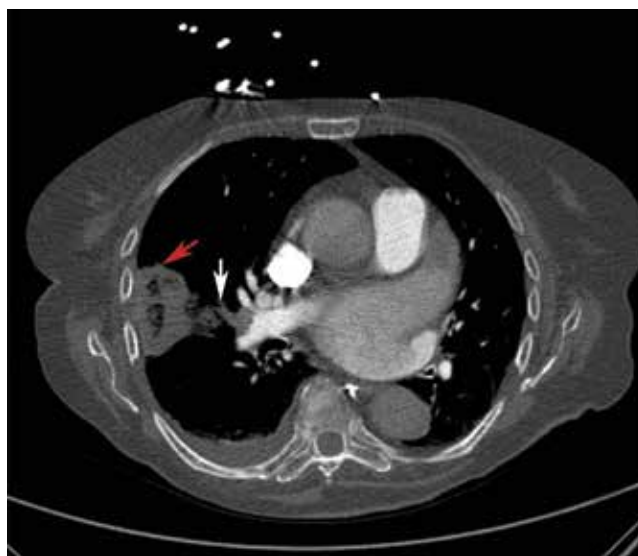

FIGURE 2. Computed tomography of the chest showed acute thromboembolism in the right interlobar artery (white arrow) and a wedge-shaped consolidation in the right-middle lobe (red arrow), consistent with pulmonary infarction.

AN 82-YEAR-OLD WOMAN was admitted to the hospital with dyspnea and chest discomfort over the past 24 hours. She was known to have paroxysmal atrial fibrillation and was taking warfarin, but that had been stopped 2 weeks earlier because of an acute ischemic stroke.

At the time of admission, she had no fever, cough, orthopnea, or leg swelling. Her physical activity was restricted, with residual right-sided weakness after her stroke. Her heart rate was 125 bpm; her oxygen saturation level was 98% on 2 L of oxygen per minute via nasal cannula. She had an irregularly irregular rhythm, a jugular venous pressure of 7 cm H₂O, and no cardiac murmurs. Lung sounds were reduced at the bases, with faint crepitations.

Her hemoglobin concentration and white blood cell count were normal. Her brain-natriuretic peptide level was elevated at 2,648 pg/mL (reference range < 167), but cardiac enzyme levels were normal.

Electrocardiography showed atrial fibrillation with rapid ventricular response.

Plain chest radiography showed a 3-cm wedge-shaped opacity in the right mid-thorax (FIGURE 1), a finding known as the Hampton hump—a sign of pulmonary infarction caused by embolism.

Contrast-enhanced computed tomography (CT) of the chest showed acute thromboembolism in the right interlobar artery and wedge-shaped consolidation in the right-middle lobe (FIGURE 2), indicating pulmonary infarction.

doi:10.3949/ccjm.80a.13006

Brain CT showed a stable infarction. Anticoagulation was restarted, and the patient was discharged in stable condition.

THE HAMPTON HUMP IN PULMONARY EMBOLISM

Because the lungs have a dual blood supply, pulmonary infarction is seen in only a minority of cases of pulmonary embolism. Infarction is more common in patients with peripheral pulmonary embolism, owing to the rapid inflow of bronchial blood, and in patients with medical comorbidities such as heart failure and chronic lung disease.²

The Hampton hump, first described by Aubrey Otis Hampton in 1940, is a peripheral (pleural-based) opacity that represents alveolar hemorrhage from underlying pulmonary infarction. It is one of several radiographic features that have been associated with pulmonary embolism; another is the Westermark sign, indicating oligemia.³

Worsley et al⁴ examined the diagnostic

value of these radiographic features and found that the Hampton hump had a sensitivity of 22% and a specificity of 82% for detecting pulmonary embolism in the right hemithorax, and 24% and 82%, respectively, in the left hemithorax. The prevalence of pleural-based opacities was not significantly different in patients with or without pulmonary embolism. The authors concluded that chest radiography has limited diagnostic value in excluding or diagnosing pulmonary embolism.

In contrast, computed tomographic pulmonary angiography is the first-line imaging test in patients with suspected pulmonary embolism, because of its high sensitivity and specificity.¹

We were not specifically looking for a pulmonary embolism when we found this new opacity on our patient's radiograph, but this prompted further imaging, which led to the diagnosis. Although a near-normal chest radiograph is the most common radiologic finding in pulmonary embolism, this case shows how careful observation can detect unusual signs. ■

REFERENCES

1. Mos IC, Klok FA, Kroft LJ, de Roos A, Huisman MV. Imaging tests in the diagnosis of pulmonary embolism. *Semin Respir Crit Care Med* 2012; 33:138–143.
2. Cha SI, Shin KM, Lee J, et al. Clinical relevance of pulmonary infarction in patients with pulmonary embolism. *Thromb Res* 2012; 130:e1–e5.
3. Algin O, Gökalp G, Topal U. Signs in chest imaging. *Diagn*

Interv Radiol 2011; 17:18–29.

4. Worsley DF, Alavi A, Aronchick JM, Chen JT, Greenspan RH, Ravin CE. Chest radiographic findings in patients with acute pulmonary embolism: observations from the PIOPED study. *Radiology* 1993; 189:133–136.

ADDRESS: M. Chadi Alraies, MD, Department of Hospital Medicine, A13, Cleveland Clinic, 9500 Euclid Avenue, Cleveland, OH 44195; e-mail: alraies@hotmail.com

The initial workup was negative; the radiographic finding of an opacity led to further imaging and the diagnosis