

TABLE OF CONTENTS

FROM THE EDITOR

Examine before ordering: 234

An algorithm unchanged by new tests

I have always been irked when doctors reflexively order panels of immunologic tests when evaluating patients with "arthritis."

B.F. MANDELL

1-MINUTE CONSULT

Should I order an anti-CCP antibody test to diagnose rheumatoid arthritis? 249

This test is highly specific, though it may be redundant for a patient who has documented rheumatoid arthritis and who is seropositive for rheumatoid factor.

N. BOSE AND L.H. CALABRESE

THE CLINICAL PICTURE.....

Purpuric lesion on the elbow 253

A 75-year-old man developed a painful lesion on the elbow several days after starting warfarin therapy. What is the most likely diagnosis?

N.K. VOORE, A. RAHMAN, S. SANNA, AND H. BAHRAIN

THE CLINICAL PICTURE.....

Purple urine in a woman with chronic kidney disease 255

Although purple urine itself is usually considered benign, it should prompt an evaluation for urinary tract infection.

Y.-C. CHEN



REVIEW

Synthetic legal intoxicating drugs: The 'incense' and 'bath salt' phenomenon 258

These products are gaining in popularity among drug abusers, because they are cheap and produce a powerful high. They may not be detectable on standard urine drug screening.

J. JERRY, G. COLLINS, AND D. STREEM

CONTINUED ON PAGE 231

CLEVELAND CLINIC JOURNAL OF MEDICINE

Online Features

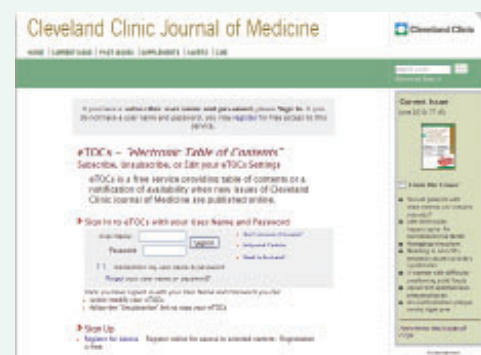Free e-mail alerts

To receive your free e-mail Table of Contents (eTOC) when a new issue of the *Cleveland Clinic Journal of Medicine* is released, just click on "Alerts" from any page at www.ccm.org.

It is quick and easy. All you need is your e-mail address. No other registration information is required.

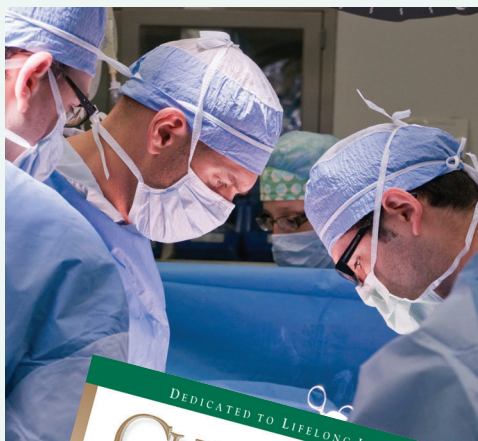Social Networking

To post a *CCJM* article to Facebook or your favorite social networking site, just click on the icon at the bottom of any online article.



UPCOMING FEATURES

- **CT screening for lung cancer: How to do it rationally**
- **Acute community-acquired bacterial meningitis in adults**
- **Disparities in prostate cancer in African American men: What you can do**
- **Family history: A useful tool in personalized care**
- **Avoiding UV damage: Sunscreens and smoke screens**
- **Dengue fever: A reemerging concern among travelers**
- **Advanced heart failure: Present and future**



DEDICATED TO LIFELONG LEARNING
CLEVELAND
CLINIC
JOURNAL OF
MEDICINE

CONTINUED FROM PAGE 228

REVIEW 265

Factor V Leiden: How great is the risk of venous thromboembolism?

The risk of a first episode of thromboembolism is two to five times higher with the heterozygous factor V Leiden mutation, but the absolute risk is still low.

K. SHAHEEN, M.C. ALRAIES, A.H. ALRAIYES, AND R. CHRISTIE

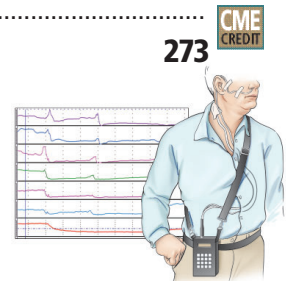
CME
CREDIT

REVIEW 273

Antireflux surgery in the proton pump inhibitor era

Although drug therapy with a proton pump inhibitor is the first-line treatment for gastroesophageal reflux disease, surgery still has several specific indications.

W.J. BULSIEWICZ AND R.D. MADANICK



CME
CREDIT

THE CLINICAL PICTURE..... 282

A nodule on a woman's face

It is firm, pink, 10 mm in diameter, with surrounding telangiectasias. What is it?

S. ARIAS-SANTIAGO, J. ANEIRO-S-FERNÁNDEZ, A. CUTANDO, A. BUENDÍA-EISMAN, R. NARANJO-SINTES, A. CAMPOS, AND M. ALAMINOS-MINGORANCE

REVIEW 285

Nonallergic rhinitis: Common problem, chronic symptoms

Allergic and nonallergic rhinitis have similar symptoms, but their mechanisms and treatment differ.

B. SCHROER AND L.C. PIEN

CME
CREDIT

DEPARTMENTS 236

Letters to the Editor

Readers comment on previous articles about glucocorticoid-induced diabetes and adrenal failure (November 2011), essential tremor (December 2011), and Parkinson disease (January 2012).

CME Calendar

Directions for taking CME tests online

To receive CME credit, read any or all of the CME-certified articles in this issue (those that carry the CME logo), then go to www.ccjm.org to take the test for the article or articles you select. It should take up to 1 hour to complete the activity for each article. Release date: April 1, 2012. Expiration date: March 31, 2013.