

## Online Features

Let us alert you to timely articles that appear in *Cleveland Clinic Journal of Medicine*

eTOCs is a free service that provides the Table of Contents or a notification of availability when new issues of *Cleveland Clinic Journal of Medicine* are published online

Sign up for *Cleveland Clinic Journal of Medicine* eTOCs (electronic Table of Contents)

To sign up, go to [www.ccjm.org](http://www.ccjm.org) and click on "E-MAIL ALERTS (FREE)"



JUNE 2011

## TABLE OF CONTENTS

### FROM THE EDITOR .....

#### The pain of cholesterol-lowering therapy 354

It seems that everyone "knows" that statins cause muscle pain, including many patients with hypercholesterolemia.

B.F. MANDELL

### MEDICAL GRAND ROUNDS .....

#### Immune thrombocytopenia: No longer 'idiopathic' 358

Once regarded as idiopathic, immune thrombocytopenia is now understood to involve both accelerated platelet destruction and impaired platelet production.

K. McCRAE

### THE CLINICAL PICTURE .....

#### Scar reactivation and dry cough 375

A 52-year-old woman has swelling and redness of seven old scars and a dry cough. What diagnostic test should be performed?

G. RECH, R. BALESTRI, F. BARDAZZI, B.M. PIRACCINI, AND A. PATRIZI

### THE CLINICAL PICTURE .....

#### Subphrenic abscess from a perforated duodenal ulcer 377

A 55-year-old man presents after 3 weeks of sharp epigastric pain radiating to the right upper quadrant, fever, and generalized weakness.

Y. SHEN, P. ONG, N. GANDHI, AND A. DEGIROLAMO

### MEDICAL GRAND ROUNDS .....

#### How to manage type 2 diabetes in medical and surgical patients in the hospital 379

Many patients admitted to the hospital have diabetes mellitus—diagnosed or undiagnosed—and others develop hyperglycemia from the stress of hospitalization.

G.E. UMPIERREZ

CONTINUED ON PAGE 350



CONTINUED FROM PAGE 349



IM BOARD REVIEW

**Progressive muscle weakness:  
More there than meets the eye**

385

A 56-year-old woman presents with proximal weakness in all four limbs. What are the possible causes?

S. ALBASHIR, L. OLANSKY, AND M. SASIDHAR



REVIEW

**Statin myopathy:**

393

**A common dilemma not reflected in clinical trials**

When a patient taking a statin complains of muscle aches, is he or she experiencing statin-induced myopathy or some other problem? Should the statin be discontinued?

G. FERNANDEZ, E.S. SPATZ, C. JABLECKI, AND P.S. PHILLIPS



REVIEW

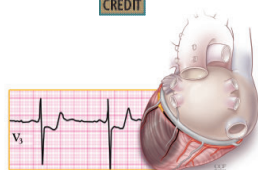
**ST-segment depression**

404

**and T-wave inversion:  
Classification, differential diagnosis,  
and caveats**

Knowing the characteristic patterns is critical for a timely diagnosis of life-threatening disorders.

E.B. HANNA AND D.L. GLANCY



DEPARTMENTS

**Letters to the Editor**

355

Readers comment on iron therapy and infection (March 2011), and managing bloodstream infections (January 2011).

**Correction**

356

There was an error in the caption for **FIGURE 2** in: Villa-Forte A. Giant cell arteritis: Suspect it, treat it promptly. *Cleve Clin J Med* 2011; 78:265–270.

**CME Calendar**

392

**Directions for taking CME tests online**

415

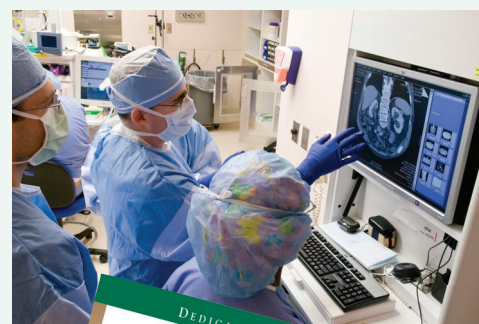To receive CME credit, read any or all of the CME-certified articles in this issue (those that carry the CME logo), then go to [www.ccjm.org](http://www.ccjm.org) to take the test for the article or articles you select. It should take up to 1 hour to complete the activity for each article.

Release date: June 1, 2011

Expiration date: May 31, 2012

# UPCOMING FEATURES

- **Therapeutic hypothermia:**  
Why cooling helps survivors of cardiac arrest
- **Does loss of sleep**  
cause diabetes?
- **Bronchial thermoplasty,**  
a new treatment for asthma
- **Managing cancer pain:**  
Frequently asked questions
- **Infections from cardiovascular**  
implantable electronic devices
- **Vancomycin:**  
Old drug, persistent issues
- **For how long should**  
bisphosphonates be taken?
- **Hospital medicine update:**  
Studies likely to affect  
inpatient practice



DEDICATED TO LIFELONG LEARNING  
**CLEVELAND  
CLINIC  
JOURNAL OF  
MEDICINE**