

TABLE OF CONTENTS

FROM THE EDITOR

Recognizing the unusual: The diagnostic epiphany 277

We have all experienced the sudden recognition of an unexpected diagnosis, such as the case of visceral angioedema due to angiotensin-converting enzyme therapy reported by Korniyenko et al in this issue of the *Journal*.

B.F. MANDELL

THE CLINICAL PICTURE.....

A 46-year-old man with fever, ST-segment elevation 286

ST-segment elevation commonly represents acute myocardial infarction, but it is also associated with other conditions.

A. SINGLA, W. COATS, AND G.C. FLAKER

THE CLINICAL PICTURE.....

Facial swelling and ulceration with nasal destruction 289

A 12-year-old boy presents with painless swelling and ulceration on and around his nose. What is the diagnosis?

S.K. GHOSH, D. BANDYOPADHYAY, AND L. GHOSHAL

REVIEW

Visceral angioedema due to angiotensin-converting enzyme inhibitor therapy 297

If a middle-aged woman taking an angiotensin-converting enzyme inhibitor presents with abdominal pain and emesis, the differential diagnosis should include this uncommon but serious complication.

A. KORNIYENKO, C.L. ALVIAR, J.P. CORDOVA, AND F.H. MESSERLI



IM BOARD REVIEW.....

Ulcerative colitis and an abnormal cholangiogram 306

The patient, who has had ulcerative colitis for more than 30 years, now has mild, intermittent pain in his right upper quadrant. What is the diagnosis?

D.L. NGUYEN AND K.N. LAZARIDIS

CONTINUED ON PAGE 282

CLEVELAND CLINIC JOURNAL OF MEDICINE

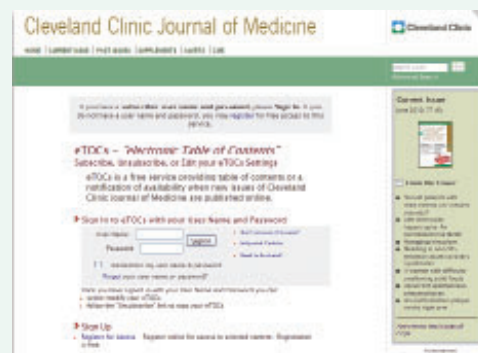Online Features

Let us alert you to timely articles that appear in *Cleveland Clinic Journal of Medicine*

eTOCs is a free service that provides the Table of Contents or a notification of availability when new issues of *Cleveland Clinic Journal of Medicine* are published online

Sign up for *Cleveland Clinic Journal of Medicine* eTOCs (electronic Table of Contents)

To sign up, go to www.ccm.org and click on "E-MAIL ALERTS (FREE)"



CONTINUED FROM PAGE 278



REVIEW

Tinnitus: Patients do not have to 'just live with it' 312

Physicians should actively listen to the patient and provide hope and encouragement, balanced with realistic expectations. Specialists can help.

C.W. NEWMAN, S.A. SANDRIDGE, S.M. BEA, K. CHERIAN, N. CHERIAN, K.M. KAHN, AND J. KALTENBACH

PATIENT INFORMATION

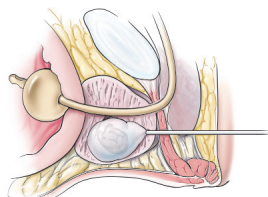
Tinnitus relief: Suggestions for patients 320

CANCER DIAGNOSIS AND MANAGEMENT

A practical guide to prostate cancer diagnosis and management 321

Screening, diagnosis, and management of prostate cancer can be complicated, with no clear consensus about key issues. Our approach reflects the guidelines from the American Urological Association.

M.N. SIMMONS, R.K. BERGLUND, AND J.S. JONES



CURRENT DRUG THERAPY

Insulin treatment for type 2 diabetes: When to start, which to use 332

Many patients with type 2 diabetes eventually need insulin. This review addresses practical approaches.

M. HAMATY

DEPARTMENTS

Letters to the Editor 284

A reader comments on the interaction between clopidogrel (Plavix) and proton pump inhibitors (January 2011).

CME Calendar 296**Directions for taking CME tests online** 343

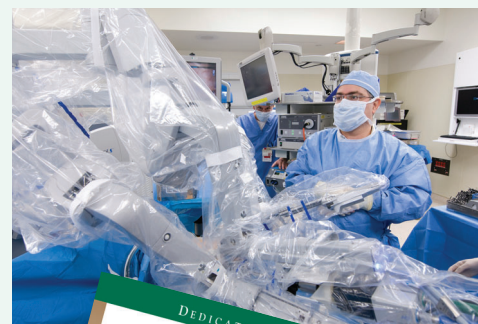To receive CME credit, read any or all of the CME-certified articles in this issue (those that carry the CME logo), then go to www.ccjm.org to take the test for the article or articles you select. It should take up to 1 hour to complete the activity for each article.

Release date: May 1, 2011

Expiration date: April 30, 2012

UPCOMING FEATURES

- **Statin-induced myopathy:**
A common dilemma, not reflected in trials
- **Cancer pain:**
Frequently asked questions
- **ST-segment depression, T-wave inversion:**
Sorting out the causes
- **Therapeutic hypothermia:**
Chilling the patient to save the brain
- **Dabigatran:**
How will it change our practice?
- **Does loss of sleep cause diabetes?**
- **How to manage diabetes in the hospital**
- **Bronchial thermoplasty, a new treatment for asthma**



DEDICATED TO LIFELONG LEARNING
CLEVELAND
CLINIC
JOURNAL OF
MEDICINE