

TABLE OF CONTENTS

FROM THE EDITOR

LVH and hypertension: Is treating the pressure not enough? 344

I am not sure the weight of current evidence supports routinely screening hypertensive patients for left ventricular hypertrophy using echocardiography, but the concept warrants consideration and study.

B.F. MANDELL

THE CLINICAL PICTURE

Recurrent spontaneous pneumothorax 345

The patient, a 26-year-old woman, also has many nodular lesions on her face, a hypopigmented lesion on her thigh, and a fleshy plaque on her back. What is the diagnosis?

A. GUPTA, B. PATEL, K. ALMOOSA, AND B.J. MCKELVY

THE CLINICAL PICTURE

An erythematous plaque on the arm 351

A 68-year-old farmer presents with an asymptomatic lesion that appeared spontaneously 5 months ago and has grown progressively. What is the diagnosis?

S. ARIAS-SANTIAGO, J. ANEIROS-FERNÁNDEZ, H. HUSEIN EL-AHMED,
P. BURKHARDT-PÉREZ, AND R. NARANJO-SINTES

IM BOARD REVIEW

Difficulty swallowing solid foods; food 'getting stuck in the chest' 354

A 61-year-old woman has had alarming symptoms for the last 4 weeks. Which test will you order now?

M.A. KHAN, B.K. JOHN, B.A. LASHNER, AND D.F. KIRBY



1-MINUTE CONSULT

Should patients with mild asthma use inhaled steroids? 364

Yes—but only if we consider the severity of the asthma, the goals of therapy, and the benefits and risks.

S.R. ABOUHASSAN AND D.M. LANG

CONTINUED ON PAGE 343

CLEVELAND CLINIC JOURNAL OF MEDICINE

EDITORIAL STAFF

BRIAN F. MANDELL, MD, PhD *Editor-in-Chief*
TIMOTHY GILLIGAN, MD, MS *Deputy Editor*
PHILLIP E. CANUTO *Executive Editor*
RAY BORAZANIAN *Managing Editor*
DAVID A. HUDDLESTON *Manuscript Editor*
ROSS PAPALARDO, CMI *Medical Art Director*
AMY SLUGG MOORE *Patient Education Editor*

PUBLISHING OPERATIONS

PETER G. STUDER *Executive Publisher*
KRISTI THOMSEN *Exec. Editor, Special Assignments*
BRUCE M. MARICH *Production Manager*
IRIS TRIVILINO *Department Coordinator*
LAURIE WEISS *Accountant (Billing)*

CUSTOM PROGRAMS

GLENN R. CAMPBELL *Executive Editor*
KATHY DUNASKY *Production Manager*

FINANCIAL DISCLOSURES

Cleveland Clinic Journal of Medicine's staff disclose the following financial relationships that may be relevant to their editorial roles: Dr. Brian F. Mandell (editor-in-chief) reports that he has received fees for consulting and speaking (CME lectures) from Takeda Pharmaceuticals, was a paid independent contractor (clinical trials) for Savient Pharmaceuticals, and consulted for URL Pharma. He also serves as section editor (rheumatology and immunology) for *The Merck Manual*. Phillip E. Canuto (executive editor) has an ownership interest (common stock) in Merck and Medco. Dr. Timothy Gilligan (deputy editor) and all other CCJM staff report no relevant financial relationships.

ASSOCIATE EDITORS

ALEJANDRO C. ARROLIGA, MD
DANIEL J. BROTMAN, MD
WILLIAM D. CAREY, MD
JEREMIAH P. DEPTA, MD
RUTH M. FARRELL, MD, MA
GARY FRANCIS, MD
KATHLEEN FRANCO-BRONSON, MD
STEVEN M. GORDON, MD
BRIAN GRIFFIN, MD
AMIR JAFFER, MD
MANDY C. LEONARD, PharmD
ANGELO A. LICATA, MD, PhD
ATUL C. MEHTA, MD
FRANKLIN A. MICHOTA, MD
CHRISTIAN NASR, MD
JOSHUA D. PENFIELD, MD
DAVID D. K. ROLSTON, MD
BERNARD J. SILVER, MD
TYLER STEVENS, MD
THEODORE SUH, MD, PhD, MHSc
ALEXANDRA VILLA-FORTE, MD, MPH

DONALD G. VIDT, MD
WILLIAM S. WILKE, MD
MARC WILLIAMS, MD

EDITORS EMERITI

JOHN D. CLOUGH, MD
HERBERT P. WIEDEMANN, MD
JAMES S. TAYLOR, MD

CLEVELAND CLINIC

DELOS M. COSGROVE, MD
President and Chief Executive Officer

CLEVELAND CLINIC

EDUCATION INSTITUTE
JAMES K. STOLLER, MD, MS
Chairman

PHILLIP R. GARD
Administrator

REPRINTS: Hope Robinson, Sheridan Content Services
800-635-7181 ext. 8065; E-mail hrobinson@tsp.sheridan.com

Cleveland Clinic Journal of Medicine (ISSN 0891-1150 (print), ISSN 1939-2869 (online)) is published monthly by Cleveland Clinic from editorial offices at 9500 Euclid Avenue, NA32, Cleveland, OH 44195-0001. POSTMASTER: Send address changes to the *Cleveland Clinic Journal of Medicine*, 9500 Euclid Avenue, NA32, Cleveland, OH 44195-0001.

STATEMENTS AND OPINIONS expressed in the *Cleveland Clinic Journal of Medicine* are those of the authors and not necessarily of Cleveland Clinic or its Board of Trustees.

SUBSCRIPTION RATES: U.S. and possessions: personal \$115; institutional \$143; single copy/back issue \$20. Foreign: \$160; single copy/back issue \$20. Institutional (multiple-reader rate) applies to libraries, schools, hospitals, and federal, commercial, and private institutions and organizations. Individual subscriptions must be in the names of, billed to, and paid by individuals.

SUBSCRIPTIONS, EDITORIAL, BILLING/ACCOUNTING, AND PRODUCTION: (same address as above) • Phone (216) 444-2661 • Fax (216) 444-9385

• E-mail ccjm@ccf.org • Web site www.ccjm.org

ADVERTISING: Joseph Dennehy, Director, Sales and Marketing, 120 Castle Ridge Rd, Manhasset, NY 11030 • Phone (516) 365-8640 • Fax (516) 365-0587
• E-mail joedennehy@verizon.net

AUTHORIZATION TO PHOTOCOPY items for internal or personal use is granted by the *Cleveland Clinic Journal of Medicine* (ISSN 0891-1150 (print), ISSN 1939-2869 (online)), published by Cleveland Clinic, provided that the appropriate fee is paid directly to Copyright Clearance Center, 222 Rosewood Drive, Danvers, MA 01923 USA 978-750-8400. Prior to photocopying items for educational classroom use, please contact Copyright Clearance Center, Inc., at the address above. For permission to reprint material, please fax your request with complete information to the Reproduction department at CCC, fax (978) 750-4470. For further information visit CCC online at www.copyright.com. To order bulk reprints, see above.

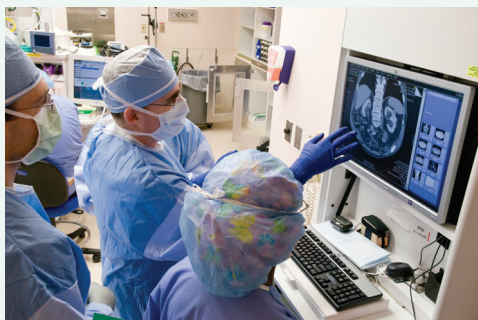DISCLAIMER: The information in this educational activity is provided for general medical education purposes only and is not meant to substitute for the independent medical judgment of a physician relative to diagnostic and treatment options of a specific patient's medical condition. The viewpoints expressed in this CME activity are those of the authors. They do not represent an endorsement by The Cleveland Clinic Foundation. In no event will The Cleveland Clinic Foundation be liable for any decision made or action taken in reliance upon the information provided through this CME activity.

COPYRIGHT© 2010 THE CLEVELAND CLINIC FOUNDATION. ALL RIGHTS RESERVED. PRINTED IN U.S.A.



UPCOMING FEATURES

- **Bariatric surgery:**
A cure for type 2 diabetes?
- **Do new tests make**
liver biopsy obsolete?
- **Menstrual manipulation:**
Options for suppressing
the cycle
- **Electronic medical records:**
Do they really improve care?
- **Can asthma patients**
take beta-blockers?
- **Managing coronary risk**
in HIV patients
- **Does coenzyme Q**
lower blood pressure,
prevent statin myalgia?
- **Drug-resistant epilepsy:**
When to refer



DEDICATED TO LIFELONG LEARNING
CLEVELAND
CLINIC
JOURNAL OF
MEDICINE

REVIEW

Incidence, outcomes, and management of bleeding in non-ST-elevation acute coronary syndromes 369



Powerful antithrombotic and antiplatelet drugs and percutaneous interventions pose risks of bleeding. Fortunately, the risk can be managed.

A. GUTIERREZ AND S.V. RAO

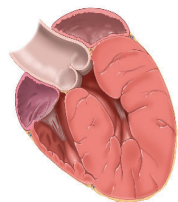
REVIEW

Left ventricular hypertrophy: An overlooked cardiovascular risk factor 381



Antihypertensive treatment that causes left ventricular hypertrophy to regress also decreases rates of cardiovascular morbidity and death, independently of how much the blood pressure is lowered.

M.A. BAUML AND D.A. UNDERWOOD



REVIEW

Update on the management of hirsutism 388



Hirsutism causes considerable anxiety in women. Although it is itself benign, it is often the sign of an underlying and possibly serious endocrine condition.

S. HARRISON, N. SOMANI, AND W.F. BERGFELD

DEPARTMENTS

CME calendar 339

Financial disclosure for associate editors 347

Directions for taking CME tests online 399

To receive CME credit, read any or all of the CME-certified articles in this issue (those that carry the CME logo), then go to www.ccjm.org to take the test for the article or articles you select. It should take up to 1 hour to complete the activity for each article.

Release date: June 1, 2010

Expiration date: May 31, 2011