

# CLEVELAND CLINIC JOURNAL OF MEDICINE

## EDITORIAL STAFF

BRIAN F. MANDELL, MD, PhD *Editor-in-Chief*  
TIMOTHY GILLIGAN, MD, MS *Deputy Editor*  
PHILLIP E. CANUTO *Executive Editor*  
RAY BORAZANIAN *Managing Editor*  
DAVID A. HUDDLESTON *Manuscript Editor*  
JOSEPH A. PANGRACE *Medical Art Director*  
AMY SLUGG MOORE *Patient Education Editor*

## PUBLISHING OPERATIONS

PETER G. STUDER *Executive Publisher*  
KRISTI THOMSEN *Exec. Editor, Special Assignments*  
BRUCE M. MARICH *Production Manager*  
IRIS TRIVILINO *Department Coordinator*  
LAURIE WEISS *Accountant (Billing)*

## CUSTOM PROGRAMS

GLENN R. CAMPBELL *Executive Editor*  
KATHY DUNASKY *Production Manager*

## ASSOCIATE EDITORS

ALEJANDRO C. ARROLIGA, MD  
ARMAN T. ASKARI, MD  
DANIEL J. BROTMAN, MD  
WILLIAM D. CAREY, MD  
RUTH M. FARRELL, MD, MA  
GARY FRANCIS, MD  
KATHLEEN FRANCO-BRONSON, MD  
STEVEN M. GORDON, MD  
BRIAN GRIFFIN, MD  
AMIR JAFFER, MD  
MANDY C. LEONARD, PharmD  
ANGELO A. LICATA, MD, PhD  
ATUL C. MEHTA, MD  
FRANKLIN A. MICHOTA, MD  
CHRISTIAN NASR, MD  
ROBERT M. PALMER, MD  
HATAYA POONYAGARIYAGORN, MD  
DAVID D. K. ROLSTON, MD  
BERNARD J. SILVER, MD  
TYLER STEVENS, MD  
THEODORE SUH, MD, PhD, MHS

RACHEL M. TALIERCIO, DO  
ALEXANDRA VILLA-FORTE, MD, MPH  
DONALD G. VIDT, MD  
WILLIAM S. WILKE, MD  
MARC WILLIAMS, MD

## EDITORS EMERITI

JOHN D. CLOUGH, MD  
HERBERT P. WIEDEMANN, MD  
JAMES S. TAYLOR, MD

## CLEVELAND CLINIC

DELOS M. COSGROVE, MD  
*President and Chief Executive Officer*

## CLEVELAND CLINIC

EDUCATION INSTITUTE  
JAMES K. STOLLER, MD, MS  
*Chairman*  
PHILLIP R. GARD  
*Administrator*

REPRINTS: Laurie Weiss 216-444-2661 E-mail [ccjm@ccf.org](mailto:ccjm@ccf.org)

*Cleveland Clinic Journal of Medicine* [ISSN 0891-1150 (print), ISSN 1939-2869 (online)] is published monthly by Cleveland Clinic from editorial offices at 9500 Euclid Avenue, Cleveland, OH 44195. Periodicals postage paid at Cleveland, OH, and at additional mailing offices. POSTMASTER: Send address changes to the *Cleveland Clinic Journal of Medicine*, NA32, 9500 Euclid Avenue, Cleveland, OH 44195.

STATEMENTS AND OPINIONS expressed in the *Cleveland Clinic Journal of Medicine* are those of the authors and not necessarily of Cleveland Clinic or its Board of Trustees.

SUBSCRIPTION RATES: U.S. and possessions: personal \$115; institutional \$143; single copy/back issue \$20. Foreign: \$160; single copy/back issue \$20. Institutional (multiple-reader rate) applies to libraries, schools, hospitals, and federal, commercial, and private institutions and organizations. Individual subscriptions must be in the names of, billed to, and paid by individuals.

SUBSCRIPTIONS, EDITORIAL, BILLING/ACCOUNTING, AND PRODUCTION: (same address as above) • Phone (216) 444-2661 • Fax (216) 444-9385 • E-mail [ccjm@ccf.org](mailto:ccjm@ccf.org) • Web site [www.ccjm.org](http://www.ccjm.org)

ADVERTISING: Joseph Dennehy, Director, Sales and Marketing, 120 Castle Ridge Rd, Manhasset, NY 11030 • Phone (516) 365-8640 • Fax (516) 365-0587 • E-mail [joe.dennehy@verizon.net](mailto:joe.dennehy@verizon.net)

AUTHORIZATION TO PHOTOCOPY items for internal or personal use is granted by the *Cleveland Clinic Journal of Medicine* [ISSN 0891-1150 (print), ISSN 1939-2869 (online)], published by Cleveland Clinic, provided that the appropriate fee is paid directly to Copyright Clearance Center, 222 Rosewood Drive, Danvers, MA 01923 USA 978-750-8400. Prior to photocopying items for educational classroom use, please contact Copyright Clearance Center, Inc., at the address above. For permission to reprint material, please fax your request with complete information to the Reproduction department at CCC, fax (978) 750-4470. For further information visit CCC online at [www.copyright.com](http://www.copyright.com). To order bulk reprints, see above.

DISCLAIMER: The information in this educational activity is provided for general medical education purposes only and is not meant to substitute for the independent medical judgment of a physician relative to diagnostic and treatment options of a specific patient's medical condition. The viewpoints expressed in this CME activity are those of the authors. They do not represent an endorsement by The Cleveland Clinic Foundation. In no event will The Cleveland Clinic Foundation be liable for any decision made or action taken in reliance upon the information provided through this CME activity.

COPYRIGHT © 2009 THE CLEVELAND CLINIC FOUNDATION. ALL RIGHTS RESERVED. PRINTED IN U.S.A.

AMM



JULY 2009

# TABLE OF CONTENTS

## FROM THE EDITOR

### The blade, the flea, and the colon 384

Ischemic colitis often gives the internist and surgeon a chance to commiserate on the power of informed watchful waiting.

B.F. MANDELL

## 1-MINUTE CONSULT

### What is the role of probiotics in the treatment of acute *Clostridium difficile*-associated diarrhea? 391

Overall, the evidence does not support using probiotics to treat *Clostridium difficile*-associated diarrhea. More studies are needed to determine if they are helpful and, if so, which ones and at what dosages.

K. MILLER AND T. FRASER

## REVIEW

### Back pain made simple: An approach based on principles and evidence 393

Low back pain is a common and costly medical condition with only a weak correlation between symptoms and pathologic changes. The authors offer a simple, evidence-based approach.

S.D. BHANGLE, S. SAPRU, AND R.S. PANUSH

## THE CLINICAL PICTURE

### Black esophagus 400

A 60-year-old man with gastrointestinal bleeding due to alcoholic cirrhosis has necrosis of the distal esophagus.

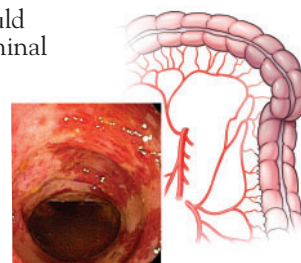
S. AKKINEPALLY, V. POREDDY, AND A. MORENO

## REVIEW

### Clinical approach to colonic ischemia 401

Ischemic colitis is one of the diagnoses that should be considered when patients present with abdominal pain, diarrhea, and intestinal bleeding.

K. ELDER, B.A. LASHNER, AND F. AL SOLAIMAN



CONTINUED ON PAGE 380

CONTINUED FROM PAGE 379

**THE CLINICAL PICTURE.....**

**Painful eye with a facial rash 410**

Six days ago, the patient had an intense headache; 4 days ago, painful herpetiform lesions appeared on his face. What is the diagnosis?

J.L. VALLEJO-GARCÍA, S. VAÑO-GALVÁN, O. RAYWARD, AND P. MORENO-MARTIN

**CME CREDIT IM BOARD REVIEW.....**

**A 48-year-old man with uncontrolled diabetes 413**

His type 2 diabetes has been well controlled for 6 years. Now, his blood sugar levels have been rising for the past week, and he has large amounts of glucose and ketones in the urine. What has happened?

M. HU AND J.H. ISAACSON

**CME CREDIT REVIEW.....**

**Alternative modes of mechanical ventilation: A review for the hospitalist 417**

Newer ventilators can be set to modes other than the pressure-control and volume-control modes of older machines. We review how they work and contrast their theoretical benefits and actual evidence of benefit.

E. MIRELES-CABODEVILA, E. DIAZ-GUZMAN, G.A. HERESI, AND R.L. CHATBURN

**DEPARTMENTS.....**

**Letters to the editor 385**

A reader comments about an article on the radiologic workup of a palpable breast mass (March 2009).

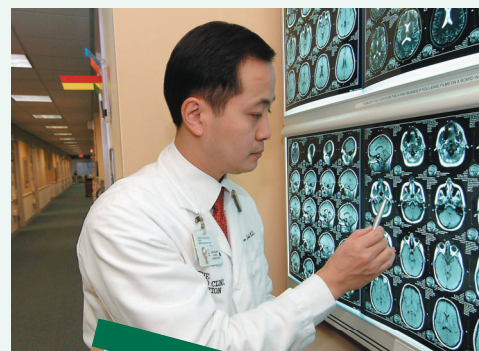**CME calendar 390**

**About our CME self-test online 431**

To receive CME credit, read the selected articles in this issue and then go online to take the test. It should take about 1 hour and 30 minutes to complete this activity. Release date: July 1, 2009. Expiration date: June 30, 2010

# UPCOMING FEATURES

- Should BNP be measured in chronic kidney disease?
- Treating atrial fibrillation with catheter ablation
- An Asian man with jaundice and very high enzyme levels
- Influenza in long-term care: Preventable, detectable, treatable
- When is MRI indicated to diagnose breast cancer?
- Managing osteoporosis: Challenges and strategies
- What's new in prostate cancer screening and prevention?
- How menopause affects oral health



DEDICATED TO LIFELONG LEARNING  
**CLEVELAND CLINIC JOURNAL OF MEDICINE**