

## THE CLINICAL PICTURE

**DEEPAK ASUDANI, MD**  
Assistant Clinical Professor of  
Medicine, Tufts University School  
of Medicine—Baystate Medical  
Center, Springfield, MA

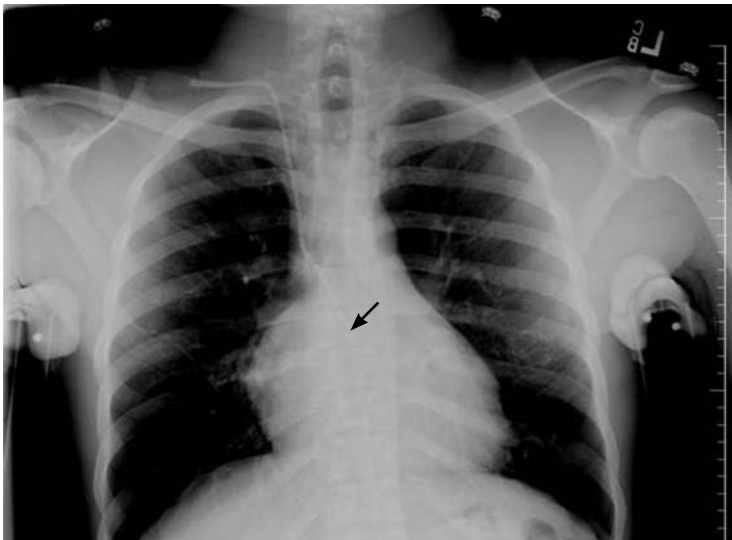**SHARON WRETZEL, MD**  
Baystate Medical Center, Tufts  
University School of Medicine,  
Springfield, MA

**RUCHITA PATEL, MD**  
Beverly Hospital and Addison  
Gilbert Hospital, Beverly, MA

**AARON STAYMAN, MD**  
Department of Medicine,  
Vanderbilt University Medical  
Center, Nashville, TN

# The Clinical Picture

## A judgment call



**FIGURE 1**

**A** 22-YEAR-OLD African American man with sickle cell disease comes to the emergency department with worsening pain in his joints and chest—a presentation similar to those of his previous sickle cell crises. He is given intravenous fluids for dehydration and morphine sulfate for pain via a peripheral line, and he is admitted to the hospital.

Shortly afterward, the peripheral line becomes infiltrated. After failed attempts at peripheral cannulation, central venous cannulation via an internal jugular site is considered.

The patient alerts us that he has had multiple “neck lines” in the past and that these had been difficult to place. With this in mind, we attempt to place a triple-lumen catheter under ultrasonographic guidance and with the use of sterile precautions and the Seldinger technique. On the first attempt, the guidewire cannot be advanced beyond 4 cm, and the at-

tempt is terminated. On the second attempt, the guidewire advances freely, but as the catheter is advanced, slight resistance is felt at 4 cm and again at 10 cm. This resistance is overcome with slight pressure, and subsequent advancement meets with no further resistance. After confirming nonpulsatile blood return in all three lumens, we suture the catheter at 14 cm from the insertion site. A chest radiograph (FIGURE 1) is requested to confirm placement.

### ■ WHERE IS THE CATHETER TIP?

At first look, the catheter appears to broadly follow an expected trajectory. However, a closer look shows that the catheter is not properly positioned: although it is difficult to see, the tip appears to project beyond the main carina (see arrow), an important landmark to identify catheter tip placement. It appears to go beyond the expected site of the junction of the superior vena cava and the right atrium. Also, at the level of the right main-stem bronchus, the catheter appears to curve with an infero-lateral convexity. To confirm the placement, a lateral view is obtained (FIGURE 2). As evident in this view, the internal jugular catheter does not terminate at the desirable level, but rather turns posteriorly to extend into the azygos vein (see arrow). The lateral view was required in this patient to ascertain the exact location of the catheter tip.

### ■ HAZARDS OF ABERRANT LINE PLACEMENT

Central venous catheters are commonly used to give various infusions (eg, parenteral nutrition), to draw blood, and to monitor the central venous pressure.<sup>1</sup> The internal jugular

vein is one of the preferred veins for central venous access.<sup>1,2</sup> Normally, the anatomy of the jugular venous system and the design of the catheter facilitate proper insertion. Occasionally, however, despite proper technique, the tip of the catheter may not terminate at the desired level, resulting in aberrant placement in the internal thoracic vein, superior vena cava, azygos vein, accessory hemiazygos vein, or axillary vein.<sup>1-8</sup>

The use of chest radiographs to establish the correct placement of internal jugular and subclavian lines has been advocated and is routinely practiced.<sup>6,7</sup> Obtaining a chest x-ray to confirm line placement is particularly important in patients with prior multiple and difficult catheterizations. The lateral view is seldom obtained when confirming central neck line placement, but when the anteroposterior view is not reassuring, it may be prudent to obtain this alternate view.

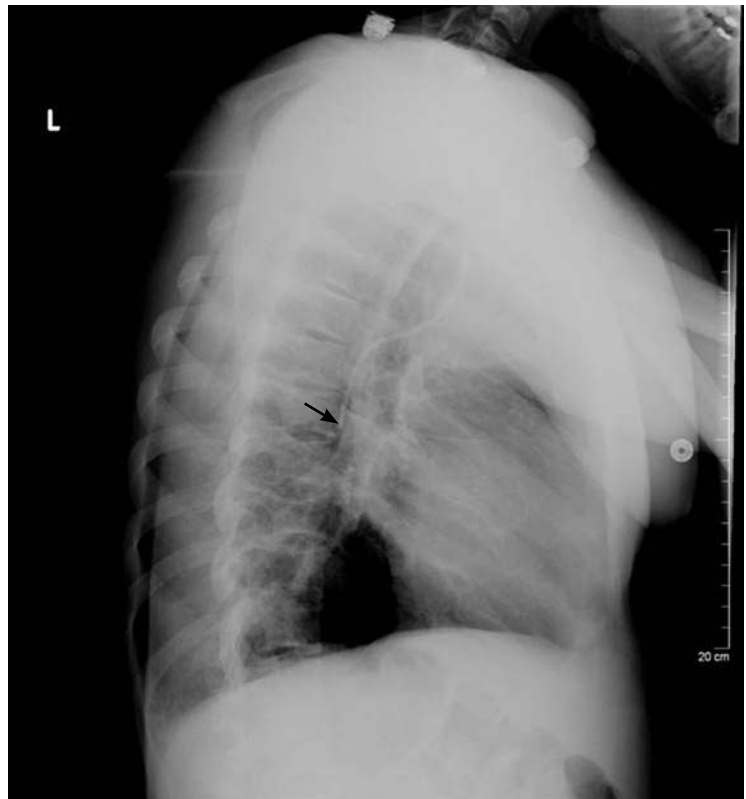
In a large retrospective analysis,<sup>9</sup> cannulation of the azygos arch occurred in about 1.2% of insertions, and the rate was about seven times higher when the left jugular vein was used than when the right one was used. A smaller study gave the frequency of azygos arch cannulation as 0.7%.<sup>10</sup>

All procedure-related complications of central line insertion in the neck can also occur with aberrant azygos vein cannulation. These include infection, bacteremia, pneumothorax, hemothorax, arterial puncture, and various other mechanical complications. It should be noted that aberrant cannulation of the azygos arch is particularly hazardous, and that complication rates are typically higher. These complications are mainly due to the smaller vascular lumen and to the direction of blood flow in the azygos venous system.

### ■ KNOWING THE ANATOMY IS CRUCIAL

Knowledge of venous anatomy and its variants is crucial both for insertion and for ascertaining the correct placement of central venous lines.

The azygos vein has a much smaller lumen than the superior vena cava. Although the lumen size may vary significantly, the maximum diameter of the anterior arch of the azygos vein is about 6 to 7 mm,<sup>11</sup> whereas the superior vena cava lumen is typically 1.5 to 2 cm



**FIGURE 2**

in diameter.<sup>12</sup> In addition, when a catheter is inserted into the superior vena cava, the direction of blood flow and the direction of the infusion are the same, but when the catheter is inserted into the azygos system, the directions of blood flow and infusion are opposite, contributing to local turbulence.

Both these factors increase the chance of puncturing the vein when the azygos arch is aberrantly cannulated for central venous access.<sup>9</sup> Venous perforation has been reported in as many as 19% of cases in which the azygos arch was inadvertently cannulated. Venous perforation can lead to hemopericardium, hemomediastinum, and hemorrhagic pleural effusions, which can lead to significant morbidity and even death. Perforation, thrombosis, stenosis, and complete occlusion have been reported subsequent to catheter malposition in the azygos vein.<sup>13</sup>

Patients in whom the azygos vein is inadvertently cannulated may tolerate infusions and blood draws, but this does not mean that inadvertent azygos vein cannulation is acceptable, especially given the late complications of

**Azygos placement occurs in up to 1.2% of central neck line insertions**

vascular perforation that can occur.<sup>9</sup>

The cannulation of the azygos vein in our patient was completely unintentional; nevertheless, the line was kept in and used for a short period for the initial rehydration and pain control and was subsequently removed without any complications.

## ■ WHEN IS CANNULATION OF THE AZYGOS VEIN AN OPTION?

In patients with previous multiple central vein cannulations, the rates of thrombosis and of fibrotic changes in these veins are high. In patients with thrombosis of both the superior vena cava and the inferior vena cava, direct insertion of a catheter into the azygos vein has been suggested as an alternate route to obtain access for dialysis.<sup>8</sup> This approach has also been used successfully to administer total parenteral nutrition for a prolonged time in pediatric patients.<sup>14</sup> In short, the azygos vein is never preferred for central venous access, but it can occasionally serve as an alternate route.<sup>5–9</sup>

## ■ REFERENCES

1. McGee DC, Goud MK. Preventing complications of central venous catheterization. *N Engl J Med* 2003; 348:1123–1133.
2. Pittiruti M, Malerba M, Carriero C, Tazza L, Gui D. Which is the easiest and safest technique for central venous access? A retrospective survey of more than 5,400 cases. *J Vasc Access* 2000; 1:100–107.
3. Towers MJ. Preventing complications of central venous catheterization. *N Engl J Med* 2003; 348:2684–2686; author reply 2684–2686.
4. Langston CS. The aberrant central venous catheter and its complications. *Radiology* 1971; 100:55–59.
5. Smith DC, Pop PM. Malposition of a total parenteral nutrition catheter in the accessory hemiazygos vein. *JPEN J Parenter Enteral Nutr* 1983; 7:289–292.
6. Abood GJ, Davis KA, Esposito TJ, Luchette FA, Gamelli RL. Comparison of routine chest radiograph versus clinician judgment to determine adequate central line placement in critically ill patients. *J Trauma* 2007; 63:50–56.
7. Gladwin MT, Slonim A, Landucci DL, Gutierrez DC, Cunnion RE. Cannulation of the internal jugular vein: is postprocedural chest radiography always necessary? *Crit Care Med* 1999; 27:1819–1823.
8. Meranze SG, McLean GK, Stein EJ, Jordan HA. Catheter placement in the azygos system: an unusual approach to venous access. *Am J Roentgenol* 1985; 144:1075–1076.
9. Bankier AA, Mallek R, Wiesmayr MN, et al. Azygos arch cannulation by central venous catheters: radiographic detection of malposition and subsequent complications. *J Thorac Imaging* 1997; 12:64–69.
10. Langston CT. The aberrant central venous catheter and its complications. *Radiology* 1971; 100:55–59.
11. Heitzman ER. Radiologic appearance of the azygos vein in cardiovascular disease. *Circulation* 1973; 47:628–634.
12. McGowan AR, Pugatch RD. Partial obstruction of the superior vena cava. BrighamRAD. Available at: <http://brighamrad.harvard.edu/Cases/bwh/hcache/58/full.html>. Accessed 9/4/2008.
13. Granata A, Figueroa M, Castellino S, Logias F, Basile A. Azygos arch cannulation by central venous catheters for hemodialysis. *J Vasc Access* 2006; 7:43–45.
14. Malt RA, Kempster M. Direct azygos vein and superior vena cava cannulation for parenteral nutrition. *JPEN J Parenter Enteral Nutr* 1983; 7:580–581.

ADDRESS: Deepak Asudani, MD, Baystate Medical Center, Tufts University School of Medicine, 759 Chestnut Street, Springfield, MA 01199; e-mail [deepak.asudani@bhs.org](mailto:deepak.asudani@bhs.org).

## ■ TAKE-HOME POINTS

The radiographic assessment of an internal jugular or subclavian line may occasionally be deceptive if based solely on the anteroposterior view; confirmation may require a lateral view. We found no guidelines for using the azygos vein for central venous access. The options in cases of aberrant cannulation include leaving the line in, removing and reinserting it at the same or another site under fluoroscopy, and attempting to reposition it after changing the catheter over a guidewire.

The use of central lines found to be in an aberrant position should be driven by clinical judgment based on the urgency of the need of access, the availability or feasibility of other access options, and the intended use. The use of the azygos vein is fraught with procedural complications, as well as postprocedural complications related to vascular perforation. If the position of the catheter tip on the anteroposterior radiographic view is not satisfactory, obtaining a lateral view should be considered. ■

**Azygos placement may be an option in some situations**