

Subarachnoid hemorrhage: A model for heart-brain interactions

Research on the brain-heart connection has traditionally focused on intentionally altering the brain and observing the effect on the heart, but natural brain injury also confers a specific signal to the heart and causes observable effects. Subarachnoid hemorrhage serves as a good model for how brain injury affects the heart because it causes characteristic cardiac responses, including arrhythmias, contraction band necrosis, and ischemia-like changes.

This article summarizes research relating to the cardiac effects of subarachnoid hemorrhage, proposes a physiologic model of how brain injury leads to cardiac damage, and suggests future directions for research.

■ POSSIBLE BRAIN-HEART MODELS

Epilepsy. The seminal study of brain-heart interaction was done by Oppenheimer et al,¹ who found that stimulating the insula in patients with epilepsy produced cardiovascular changes. Other authors have investigated the phenomenon of sudden unexpected death in epilepsy for possible cardiac involvement, but evidence is lacking. In the absence of death, cardiac arrhythmias during epilepsy are uncommon, making this a poor model of heart-brain interaction.

Stroke. Patients with strokes, especially strokes involving the insula, tend to have cardiac conduction abnormalities. Eckardt et al² found that QT dispersion was present in 82.6% of patients who had a stroke involving the insula vs 40.7% of those without insular involvement. Because the origin of stroke is diverse (ie, lesions can exist in many areas of the brain), requiring evaluation of many patients to find an adequate study sample, stroke does not serve as a good human model for heart-brain interactions.

Traumatic brain injury is associated with cardiac injury, but because trauma usually involves systemic injury, a resultant cardiac abnormality rarely can be

attributed directly to the brain. Traumatic brain injury serves as a good model, therefore, only when a specific injury can be induced in an animal model.

Neurodegenerative disease frequently involves autonomic dysfunction but causes a low incidence of cardiac problems. Typical autonomic sequelae of neurodegenerative diseases are hypotension and gastric abnormalities. Direct conduction or myocardial involvement is far less likely.

■ SUBARACHNOID HEMORRHAGE: A GOOD MODEL

Subarachnoid hemorrhage serves as a good model to study heart-brain interactions for two major reasons—its association with a high incidence of arrhythmias and a low prevalence of coronary artery disease. The occurrence of heart abnormalities in patients with subarachnoid hemorrhage has been recognized since the 1950s: much of the initial work centered on classifying the associated arrhythmias. More recently, Lanzino et al³ reviewed five major retrospective studies involving interventions for nontraumatic subarachnoid hemorrhage and found that 91% of patients had evidence of cardiac abnormalities (atrial and ventricular arrhythmias) observed on electrocardiography (ECG). At the same time, in a prospective study involving 223 patients with subarachnoid hemorrhage, Tung et al⁴ found a low prevalence of cardiac disease (5%), an ideal situation that limits confounding of the data.

■ CARDIAC ARRHYTHMIAS

Cardiac arrhythmias associated with subarachnoid hemorrhage are common and have been well classified by Sakr et al.⁵ Sinus bradycardia occurs most frequently, at nearly twice the rate of sinus tachycardia. Multifocal ventricular tachycardia (torsades de pointes) is associated with a high mortality rate and is a feared complication of subarachnoid hemorrhage. The importance of torsades de pointes has been called into question recently. Although Machado et al,⁶ in a retrospective review of the literature, found that tor-

* Dr. Provencio reported that he has no financial relationships that pose a potential conflict of interest with this article.

sades de pointes occurred in 5 of 1,139 patients (0.4%) with subarachnoid hemorrhage, they were unable to rule out confounding factors (ie, hypokalemia and hypomagnesemia) as the cause of the arrhythmia. In support of this, van den Bergh et al⁷ found that QT intervals are actually shorter with lower serum magnesium levels (prolonged intervals are thought to be indicative of patients at risk for multifocal ventricular tachycardia).

Current research: Long-term cardiac outcome after subarachnoid hemorrhage

Current clinical research at the Cleveland Clinic involves assessing patients at the time of hospitalization for subarachnoid hemorrhage with a battery of tests, including computed tomography, angiography, prolonged inpatient Holter monitoring, and biochemical tests. Further comprehensive testing is also performed at 3 months and 6 months following discharge to discover whether cardiac changes persist past the acute stage, when most studies that evaluate patients with subarachnoid hemorrhage end. It is too early in the study to report results.

CARDIAC CHANGES THAT RESEMBLE ISCHEMIA

Certain ECG changes are referred to as ischemic changes, although no evidence exists that ischemia is actually present. The myocardial changes associated with subarachnoid hemorrhage do not appear to be due to coronary artery disease. Repolarization abnormalities are common in subarachnoid hemorrhage. Sakr et al⁵ found that 83% of patients with subarachnoid hemorrhage developed repolarization abnormalities, with most being T-wave changes (39%) or the presence of U waves (26%). Deep, symmetric inverted T waves, usually without much ST-segment elevation or depression, are the typical abnormality. Prolonged QT intervals were found in 34% of patients. Left bundle branch block, which is sometimes considered a marker of acute, large-vessel ischemia, was present in only 2%.

Contraction band necrosis, a pathological pattern indicating that injury to the heart has occurred from muscles that have been energy-deprived from prolonged contraction, is a classic finding in subarachnoid hemorrhage. Transient low ejection fraction is the physiologic parameter that correlates with the pathologic finding. Despite the pattern of ECG changes commonly seen in patients with subarachnoid hemorrhage, until recently there was little evidence that they are independently associated with poor neurologic outcomes. Naidech and colleagues

found in a retrospective analysis that cardiac abnormalities were associated with worsened outcome in subarachnoid hemorrhage patients.⁸ Owing to the retrospective nature of the study, causal relationships could not be established.

At the Cleveland Clinic, we typically see approximately five patients each month with subarachnoid hemorrhage. We evaluate almost all of them with echocardiography, and typically find one patient each month with an ejection fraction in the range of 20% to 25%, which is much lower than we would expect in a relatively young, healthy population. On cardiac catheterization, which is performed infrequently in this population, the typical finding is normal coronary arteries. In almost all cases, the ejection fraction returns to almost normal in 1 week to 3 months.

In older patients, ECG changes occur with more severe events. In a retrospective study, Zaroff et al⁹ identified 439 patients with subarachnoid hemorrhage, 58 of whom had ECG findings indicative of ischemia or myocardial infarction within 3 days of presentation and before surgery to correct an aneurysm. The mean age of patients with ECG findings was higher than that of patients without ECG abnormalities (62 vs 53 years, respectively), indicating that heart disease was more likely to be present and could contribute to a confounding effect. The Hunt and Hess grade—a clinical scale for evaluating subarachnoid hemorrhage, which ranges from 1 (mild headache, alert, and oriented) to 5 (comatose, signs of severe neurologic damage)—was also higher in patients with ECG abnormalities than in those without (3.1 vs 2.5, respectively). Surprisingly, the location of the aneurysm did not differ significantly between the two groups.

Based on the findings of Oppenheimer, we would expect that posterior communicating artery aneurysms, which originate between the middle cerebral artery and the posterior communicating artery which is in close proximity to the insular cortex and hypothalamus, would be more likely to be associated with ECG abnormalities.

The importance of cardiac troponin levels in subarachnoid hemorrhage is controversial. Some argue that high levels are proof that cardiac damage originates in the heart and not from the brain. Deibert et al¹⁰ found that the troponin level is routinely elevated in patients with subarachnoid hemorrhage. Troponin levels do not correlate well with the amount of cardiac damage as measured by ejection fraction or contractility.¹¹ Among 39 patients with aneurysmal subarachnoid hemorrhage, the mean

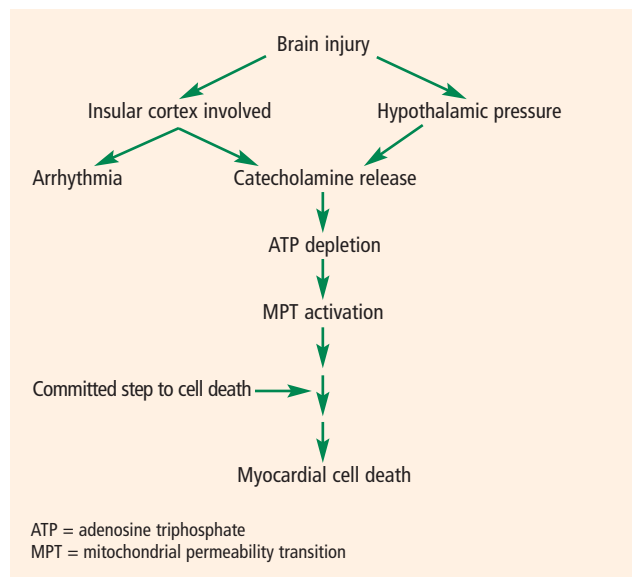


FIGURE 1. Schematic diagram of the possible mechanism of myocardial injury after acute brain injury. The theory suggests that catecholamine excess leads to myocardial death through a cascade of cellular damage. Insular cortical dysfunction likely contributes to arrhythmias. Adapted from reference 12.

ejection fraction was lower among patients who had elevated troponin I levels relative to normal troponin I levels (53% vs 72%), but the range of ejection fractions was wide (< 30% to > 80%) in patients with raised levels of troponin.¹¹

■ HOW MIGHT SUBARACHNOID HEMORRHAGE LEAD TO CARDIAC DAMAGE?

A model of how subarachnoid hemorrhage can cause cardiac damage has been proposed.¹² Brain injury can damage the insula or cause hypothalamic pressure, either of which causes catecholamine release, either systemically or at the nerve terminal at the heart. The heart contracts, leading to adenosine triphosphate depletion, mitochondrial dysfunction, and myocardial cell death (**Figure 1**).

Arrhythmias appear to be more likely to occur from insular involvement rather than generalized damage caused by hypothalamic pressure, although differentiating between effects caused by specific areas of aneurysm involvement requires further study.

■ PARASYMPATHETIC ACTIVITY AND INFLAMMATION ALSO INCREASE

The above model, however, is likely too simplistic. In the body, the sympathetic system and the parasympathetic system work as the yin and yang in controlling many bodily functions. Inflammation and cardiac con-

trol are importantly modulated by both the sympathetic and parasympathetic systems. I believe that the parasympathetic system may play an important role in cardiac injury from acute subarachnoid hemorrhage.

Evidence of parasympathetic dysfunction in subarachnoid hemorrhage is now becoming more abundant. Kawahara et al¹³ measured heart rate variability in patients with an acute subarachnoid hemorrhage and determined that enhanced parasympathetic activity occurs acutely. This acute activation could potentially contribute to ECG abnormalities and cardiac injury.

The parasympathetic response may also affect the inflammatory response. The “neuroinflammatory reflex” (a term coined by Tracey¹⁴) is a vagally mediated phenomenon that relates to parasympathetic nervous system activation that suppresses inflammation. Thus, parasympathetic dysfunction resulting from subarachnoid hemorrhage could result in enhanced inflammation.

Previous theories (as depicted in **Figure 1**) speculate that norepinephrine is the sole cause of heart injury in acute brain injury, but this notion is doubtful. In fact, patients given large doses of intravenous norepinephrine for the treatment of sepsis or hypovolemic shock typically do not develop cardiomyopathy. Cardiomyopathies of the type seen in patients with subarachnoid hemorrhage only develop from an excess of catecholamines when exposure occurs over weeks or months, such as in patients with pheochromocytoma. The cardiac abnormalities seen in subarachnoid hemorrhage develop in a matter of hours, which is unheard of in other disease processes involving only sympathetic activation.

Evidence of inflammation at transplant

Data indicate that the cause of death in an organ donor has an impact on the organ recipient’s course of transplantation. Tsai et al¹⁵ compared outcomes among 251 transplant recipients who received hearts either from donors who died of atraumatic intracranial bleeding (group 1; n = 80) or from donors who died from other causes (group 2; n = 171). Mortality among transplant recipients was higher in group 1 (14%) than in group 2 (5%).

Yamani et al¹⁶ performed cardiac biopsies 1 week after transplantation and then performed serial coronary intravascular ultrasonography over 1 year in 40 patients, half of whom received hearts from donors who died from intracerebral hemorrhage (ICH) and half from donors who died of trauma. At 1 week, heart biopsies from the ICH group had greater expression of

matrix metalloproteinases, enzymes that are responsible for matrix remodeling and associated with proinflammatory states, compared with biopsies from the trauma group. The injury in the ICH group translated into an increase in vasculopathy and myocardial fibrosis. At 1 year, hearts from donors who died of trauma had much less fibrosis and less progression of coronary vasculopathy (as measured by the change in maximal intimal thickness on intravascular ultrasonography) compared with hearts from donors who died from ICH, even after correcting for differences in age.

Yamani et al¹⁷ also found that mRNA expression of angiotensin II type 1 receptor (AT1R), a receptor that becomes upregulated during acute inflammation, was elevated 4.7-fold in biopsies of transplanted hearts from donors who had ICH compared with those from donors who died of trauma. A 2.6-fold increase was also found in AT1R mRNA expression in spleen lymphocytes from donors who died of ICH compared with donors who died from trauma, indicating that systemic activation of inflammation occurred before transplantation. AT1R mRNA expression has also been found to be seven times greater in the cerebrospinal fluid of patients with subarachnoid hemorrhage than in a control population (unpublished data).

INSIGHTS FROM ANIMAL RESEARCH

Animal research of subarachnoid hemorrhage has traditionally been difficult because of a lack of suitable models. Recently, a successful mouse model was developed at the University of Virginia using injected blood from a genetically identical sibling into the cisterna magna following microsurgery to mimic a subarachnoid hemorrhage.¹⁸ A study done by the same group found that suppressing brain inflammation by injecting an antibody to E-selectin (a necessary protein for inflammatory cell traffic into the brain) into the blood of mice diminished the inflammatory side effects of subarachnoid hemorrhage, especially a condition of delayed stroke after subarachnoid hemorrhage called vasospasm.¹⁹ In preliminary data from our laboratory, we have found that another anti-inflammatory antibody can also diminish the cardiac pathology seen after subarachnoid hemorrhage (unpublished work).

These recent data have caused us to rethink the previous model of the mechanisms of cardiac injury from subarachnoid hemorrhage. We believe that parasympathetic dysfunction also plays an important role and, coupled with catecholamine release, allows unchecked inflammation, which leads to myocardial dysfunction and cell death (Figure 2).

We hope that with better understanding of these

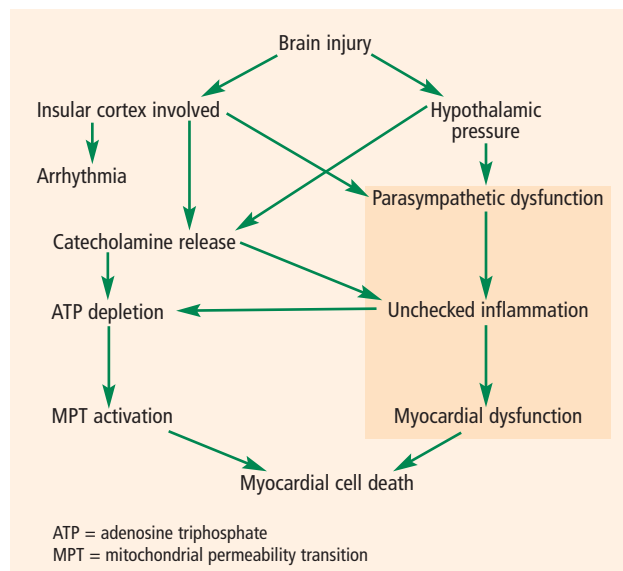


FIGURE 2. A new model of heart-brain interaction based on combined sympathetic hyperactivity and parasympathetic dysfunction (shaded area).

two processes—parasympathetic dysfunction and catecholamine release—we will be able to mitigate harm to the heart. If agents can be found that can suppress sympathetic activation or heighten parasympathetic activation, it might be possible to improve outcomes in this patient population. This line of research will likely shape our future efforts to understand the system further and look for targets for clinical intervention.

REFERENCES

- Oppenheimer SM, Gelb A, Girvin JP, Hachinski VC. Cardiovascular effects of human insular cortex stimulation. *Neurology* 1992; 42:1727–1732.
- Eckardt M, Gerlach L, Welter FL. Prolongation of the frequency-corrected QT dispersion following cerebral strokes with involvement of the insula of Reil. *Eur Neurol* 1999; 42:190–193.
- Lanzino G, Kongable GL, Kassell NF. Electrocardiographic abnormalities after nontraumatic subarachnoid hemorrhage. *J Neurosurg Anesthesiol* 1994; 6:156–162.
- Tung P, Kopelnik A, Banki N, et al. Predictors of neurocardiogenic injury after subarachnoid hemorrhage. *Stroke* 2004; 35:548–551.
- Sakr YL, Lim N, Amaral AC, et al. Relation of ECG changes to neurological outcome in patients with aneurysmal subarachnoid hemorrhage. *Int J Cardiol* 2004; 96:369–373.
- Machado C, Baga JJ, Kawasaki R, Reineohl J, Steinman RT, Lehmann MH. Torsade de pointes as a complication of subarachnoid hemorrhage: a critical reappraisal. *J Electrocardiol* 1997; 30:31–37.
- van den Bergh WM, Algra A, Rinkel GJ. Electrocardiographic abnormalities and serum magnesium in patients with subarachnoid hemorrhage. *Stroke* 2004; 35:644–648.
- Naidech AM, Kreiter KT, Janjua N, et al. Cardiac troponin elevation, cardiovascular morbidity, and outcome after subarachnoid hemorrhage. *Circulation* 2005; 112:2851–2856.
- Zaroff JG, Rordorf GA, Newell JB, Ogilvy CS, Levinson JR. Cardiac outcome in patients with subarachnoid hemorrhage and electrocardiographic abnormalities. *Neurosurgery* 1999; 44:34–40.
- Deibert E, Barzilai B, Braverman AC, et al. Clinical significance

- of elevated troponin I levels in patients with nontraumatic subarachnoid hemorrhage. *J Neurosurg* 2003; 98:741–746.
11. **Parekh N, Venkatesh B, Cross D, et al.** Cardiac troponin I predicts myocardial dysfunction in aneurysmal subarachnoid hemorrhage. *J Am Coll Cardiol* 2000; 36:1328–1335.
 12. **Provencio JJ, Bleck TP.** Cardiovascular disorders related to neurological and neurosurgical emergencies. In: Cruz J, ed. *Neurological and Neurosurgical Emergencies*. Philadelphia, PA: WB Saunders Co; 1998:39–50.
 13. **Kawahara E, Ikeda S, Miyahara Y, Kohno S.** Role of autonomic nervous dysfunction in electrocardiographic abnormalities and cardiac injury in patients with acute subarachnoid hemorrhage. *Circ J* 2003; 67:753–756.
 14. **Tracey KJ.** The inflammatory reflex. *Nature* 2002; 420:853–859.
 15. **Tsai FC, Marelli D, Bresson J, et al; UCLA Heart Transplant Group.** Use of hearts transplanted from donors with atraumatic intracranial bleeds. *J Heart Lung Transplant* 2002; 21:623–628.
 16. **Yamani MH, Starling RC, Cook DJ, et al.** Donor spontaneous intracerebral hemorrhage is associated with systemic activation of matrix metalloproteinase-2 and matrix metalloproteinase-9 and subsequent development of coronary vasculopathy in the heart transplant recipient. *Circulation* 2003; 108:1724–1728.
 17. **Yamani MH, Cook DJ, Tuzcu EM, et al.** Systemic up-regulation of angiotensin II type 1 receptor in cardiac donors with spontaneous intracerebral hemorrhage. *Am J Transplant* 2004; 4:1097–1102. Erratum in: *Am J Transplant* 2004; 4:1928–1929.
 18. **Lin CL, Calisaneller T, Ukita N, Dumont AS, Kassell NF, Lee KS.** A murine model of subarachnoid hemorrhage-induced cerebral vasospasm. *J Neurosci Methods* 2003; 123:89–97.
 19. **Lin CL, Dumont AS, Calisaneller T, Kwan AL, Hwong SL, Lee KS.** Monoclonal antibody against E selectin attenuates subarachnoid hemorrhage-induced cerebral vasospasm. *Surg Neurol* 2005; 64:201–205.

Address: J. Javier Provencio, MD, Neuroinflammation Research Center, Departments of Neurology and Neurosciences, Cleveland Clinic, 9500 Euclid Avenue, S90, Cleveland, OH 44195; provenj@ccf.org.