

**LTC EMIL P. LESH0, MC, USA**

Walter Reed Army Medical Center, Washington, DC

**RONALD NEAFIE, MS**

Armed Forces Institute of Pathology, Washington, DC

**LTC GLENN WORTMANN, MC, USA**

Walter Reed Army Medical Center, Washington, DC

**COL NAOMI ARONSON, MC, USA**Uniformed Services University of the Health Sciences,  
Bethesda, MD

# Nonhealing skin lesions in a sailor and a journalist returning from Iraq

**A** 37-YEAR-OLD MAN in the Naval Reserve and a 25-year-old woman who is a photojournalist have returned from an extended stay in Kuwait and Iraq and were referred to you because of pleomorphic, nonhealing skin lesions on their faces, arms, and thumbs (**FIGURE 1**). They stayed at the same campsites, villages, and cities. The lesions have been present for 6 to 8 weeks and have not responded to a 10-day course of cephalexin followed by a similar course of amoxicillin-clavulanate. The lesions are painless and do not readily bleed. The patients' complete blood cell counts and basic metabolic panels are normal.

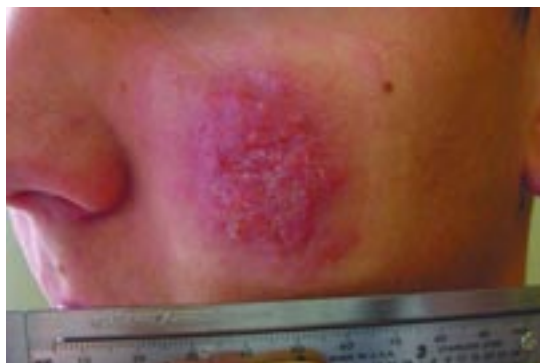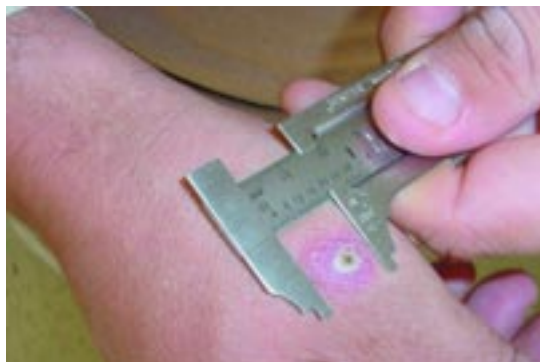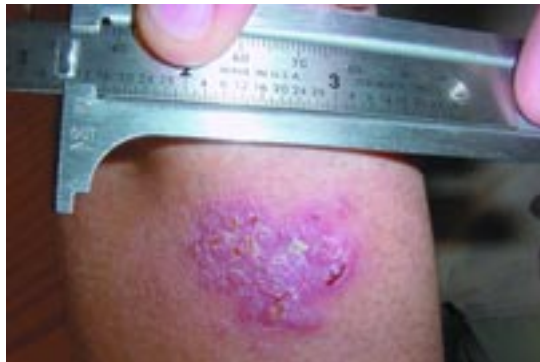
## DIFFERENTIAL DIAGNOSIS

**1** Your differential diagnosis includes all of the following except which one?

- ☐ Fungal infections such as sporotrichosis or blastomycosis
- ☐ Allergic response to arthropod bites
- ☐ Bacillary angiomatosis
- ☐ Old World cutaneous leishmaniasis

**TABLE 1** lists the differential diagnosis of a chronic ulcerative or nodular skin lesion in a returned traveler. Not on the list is bacillary angiomatosis (caused by *Bartonella* species), which tends to cause elevated lesions that are vascular and friable, rather than flat or depressed ulcers. In addition, it tends to occur in immunosuppressed persons and is not related to travel.

This paper discusses therapies that are experimental or that are not approved by the US Food and Drug Administration for the use under discussion. The views expressed herein are solely those of the authors and not to be construed as official or representing those of the US Army or the Department of Defense.



**The US Army  
has had more  
than 600 cases  
of leishmaniasis**

**FIGURE 1.** Top, psoriaform plaque on extensor surface of knee; middle, central eschar on thumb; bottom, papular eruption on cheek.

TABLE 1

### Differential diagnosis of nodular-ulcerative skin lesions in returned travelers

#### Infections

Staphylococcal or streptococcal pyoderma  
Cutaneous anthrax, diphtheria, tularemia  
Cutaneous leishmaniasis  
Treponemal infections  
Cutaneous tuberculosis  
*Mycobacterium marinum*, or mycobacteria other than tubercle  
*Mycobacterium leprae*  
Blastomycosis  
Sporotrichosis  
Paracoccidioidomycosis

#### Infestations

Myiasis

#### Noninfectious causes

Sarcoidosis  
Skin cancer  
Ecthyma  
Pyogenic granuloma  
Allergic response to arthropod bites  
Brown recluse spider bites

Inside macrophages, the organism is called an amastigote

In a series of 269 travelers who returned with skin lesions,<sup>1</sup> the most common diagnoses were cutaneous larva migrans (25%), pyoderma (18%), arthropod reactive dermatitis (10%), myiasis (infestation by larvae of flies) (9%), tungiasis (bites from the sand flea *Tunga penetrans* (6%), and cutaneous leishmaniasis (3%).

#### Cutaneous leishmaniasis is increasing in US troops

Leishmaniasis acquired in the Eastern hemisphere is referred to as "Old World" leishmaniasis, and that acquired in the Western hemisphere is referred to as "New World" leishmaniasis. Among 1,096 patients with localized cutaneous leishmaniasis in Iran, the clinical appearances varied and included hyperkeratotic, zosteriform, erysipeloid, sporotrichoid, eczematoid, and verrucous lesions.<sup>2</sup>

Persistent skin lesions following travel to endemic areas (particularly Iraq, Iran, Afghanistan, the Middle East, southern

Europe, and Latin America) should raise suspicion for the diagnosis of cutaneous leishmaniasis. Travelers can contract cutaneous leishmaniasis in nearly 90 countries on four continents.<sup>3</sup> It has an estimated annual incidence of 1.5 to 2 million.<sup>3</sup>

As the global war on terrorism required US troops and government contractors to deploy to endemic areas, the number of cases seen by military health care providers has markedly increased.<sup>4</sup> As new troops deploy to the Middle East and as activated reservists, National Guardsmen, and civilian contractors return home, more civilian health care providers across the country are likely to encounter returned travelers with such lesions and to become involved in the diagnosis and management of leishmaniasis. The US Army has had more than 600 confirmed cases of leishmaniasis and an additional 200 unconfirmed cases.<sup>5</sup> Since leishmaniasis is not a reportable disease, the number of new civilian cases in the United States is difficult to determine.

**Clues** that should raise one's suspicion for cutaneous leishmaniasis in this case include:

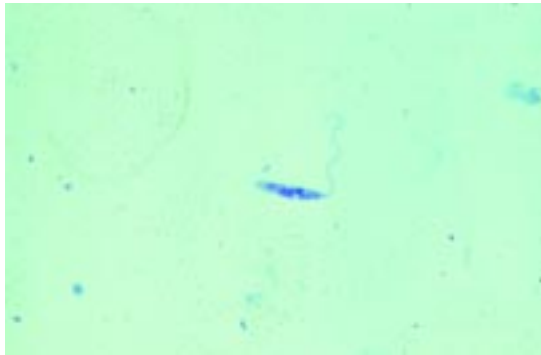
- Travel to an area where the disease is endemic or prevalent
- Lesions that are typical of cutaneous leishmaniasis, ie, papular eruption or well-circumscribed elevated lesions with central crusting or cratering and concentric desquamation
- No response to a course of antibiotics that should have been adequate for most bacterial skin infections.

The diagnosis is confirmed by culturing the parasite or demonstrating its DNA from sampling the lesions.

#### ■ HOW IS LEISHMANIASIS TRANSMITTED?

**2** *Leishmania* infection is most often transmitted by which of the following vectors?

- ☐ A deer tick infected with a spirochete
- ☐ An *Anopheles* mosquito infected with a protozoan
- ☐ An *Aedes* mosquito infected by a virus
- ☐ A phlebotomine sand fly infected with a dimorphic parasite
- ☐ A wood tick infected by intracellular bacteria



**FIGURE 2.** Promastigote, the flagellated form of the parasitic protozoan *Leishmania* (Giemsa stain,  $\times 1000$ ).

Leishmaniasis is spread by the bite of a sand fly infected with a dimorphic parasite.

The parasite exists as two distinct forms, depending on the location. In the gut of the fly, the flagellated form is known as the promastigote (FIGURE 2). In the macrophages of mammalian reservoirs (mostly rodents and dogs) its flagellum is lost, and it is known as an amastigote (FIGURE 3).

There are many species of sand flies, but those most often implicated in the transmission of leishmaniasis are *Phlebotomus* species in the Middle East, Mediterranean basin, Iraq, and Afghanistan (Old World), and *Lutzomyia* in the Americas (New World).

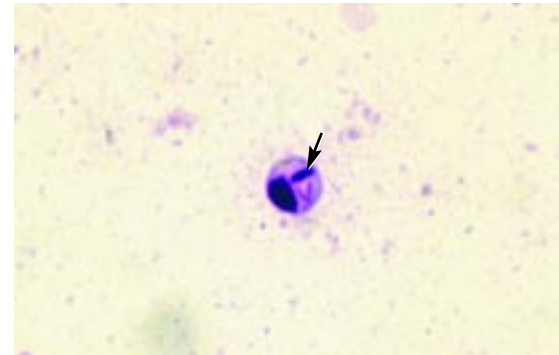
Humans are incidental hosts. Person-to-person transmission of cutaneous leishmaniasis is unusual; however, anthroponotic transmission (meaning that humans are the reservoir) has been noted.<sup>6</sup> The visceral form of leishmaniasis can be acquired from an infected blood transfusion or during needle sharing in intravenous drug users.

### ■ THREE CLINICAL SYNDROMES

**3** Leishmaniasis is usually divided into three clinical syndromes. What are they?

- ☐ Cerebral, pulmonary, and hepatosplenic
- ☐ Cutaneous, mucosal, and visceral
- ☐ Ulcerative, psoriaform, and granulomatous
- ☐ Nodular, superficial spreading, and deep tissue

Leishmaniasis syndromes are cutaneous, mucosal, or visceral (kalaazar). The syn-



**FIGURE 3.** Unflagellated form of *Leishmania*, known as an amastigote. Arrow points to the kinetoplast structure (hematoxylin-eosin,  $\times 1000$ ).

drome that develops depends on the species of *Leishmania* (TABLE 2), the interplay between the host and parasite, and the immune response of the host. Murine studies suggest that people with a cell-mediated immune response (ie, with a predominance of Th1 helper T cells) may have a milder form of cutaneous leishmaniasis than those with an antibody-mediated response (ie, with a Th2 predominance).<sup>7</sup>

Variations on the species-syndrome associations sometimes occur. Notably, *L. infantum* has been associated with localized cutaneous infection, and *L. tropica* with a mild visceral form referred to as viscerotropic leishmaniasis.<sup>8</sup>

### ■ CLINICAL PICTURE IN MIDDLE EAST

**4** What is the most common form of leishmaniasis acquired by US troops stationed in Iraq and Afghanistan?

- ☐ Localized cutaneous due to *L. major*
- ☐ Mucosal due to *L. braziliensis*
- ☐ Visceral due to *L. donovani*

Leishmaniasis of the skin can occur as five distinct forms: localized, disseminated, or diffuse cutaneous, leishmaniasis recidivans, and post-kalaazar dermal. To date, most cases of leishmaniasis acquired in Afghanistan and Iraq have been localized cutaneous and caused by *L. major*.

Localized cutaneous leishmaniasis (also known as Oriental sore or Baghdad boil) is usually a slowly developing inflammatory skin sore. The sore appears on the site of the sand

**Localized cutaneous leishmaniasis ('Baghdad boil') develops slowly over 2–8 weeks**

TABLE 2

## Species-syndrome associations in leishmaniasis

SPECIES	PREDOMINANT LOCATION	USUAL SYNDROME*
<i>L donovan</i>	India, sub-Saharan Africa, China, Pakistan	Visceral
<i>L infantum</i>	Mediterranean, Middle East, northern and sub-Saharan Africa, Balkans, China	Visceral
<i>L major</i>	Middle East, Africa, India, China	Cutaneous "wet ulcer"
<i>L tropica</i>	Middle East, India, southern Europe, western Asia	Cutaneous "dry ulcer"
<i>L aethiopica</i>	Ethiopia, Kenya, Yemen	Cutaneous
<i>L chagasi</i>	Latin America	Visceral
<i>L venezuelensis</i>	Venezuela	Cutaneous
<i>L mexicana</i>	Mexico, Central America, Texas, Oklahoma	Cutaneous
<i>L amazonensis</i>	Amazon basin, Brazil	Cutaneous
<i>L braziliensis</i>	Latin America	Cutaneous, mucocutaneous
<i>L peruviana</i>	Peru and Argentina (highlands)	Cutaneous
<i>L guyanensis</i>	Northern Amazon basin, Guyanas	Cutaneous
<i>L panamensis</i>	Panama, Costa Rica, Columbia	Cutaneous

\*Overlaps exist

ADAPTED FROM DEDET JP, PRATLONG F. LEISHMANIASIS. IN: COOK AND ZUMLA, EDITORS. MANSON'S TROPICAL DISEASES. 21ST EDITION. ELSEVIER SCIENCE LIMITED. LONDON; 2003:1339–1364 AND NEVA F, SACKS D. LEISHMANIASIS. IN: WARREN AND MAHMOUD, EDITORS. TROPICAL AND GEOGRAPHICAL MEDICINE. 2ND ED. MCGRAW-HILL, INC. NEW YORK 1990:296–308.

**Most recent cases of cutaneous leishmaniasis were due to *L major***

fly bite after approximately 2 to 8 weeks, usually on the most exposed body areas (arms, legs, face, neck, ears). The lesions may be nodular, plaque-like, or ulcerative. Old World cutaneous leishmaniasis often has a dry hyperkeratotic crust. Single or multiple lesions may occur: in our experience with returning members of the Armed Forces, the median number of lesions was 3 (range 1–47).

The leishmanial lesion begins as an asymptomatic erythematous papule—non-specific and easily confused with any insect bite—which slowly enlarges. Usually the center softens and may ooze (often with crusting that comes off and is then recurrently replaced) and forms a well-circumscribed shallow ulcer, sometimes with a raised violaceous border, or concentric surrounding rings of desquamation. Often the patient relates having had many bites, but most bites resolve

and only a few develop further. The sore is usually painless but can be painful if large or secondarily infected.

## HEALING

**5** True or false? Most lesions of Old World cutaneous leishmaniasis heal spontaneously.

True. Most lesions heal from the center outward in less than a year, leaving an atrophic, pigmented, and sometimes depressed scar. Lesions from *L major* are generally the quickest to heal (5 months on average), followed by *L mexicana* (8 months), and *L tropica* and *L braziliensis* (approximately 1 year).<sup>9</sup> However, the organism can disseminate and the lesion may not heal spontaneously; signs are multiple satellite circumferential "daughter" nodules, sporotrichoid subcutaneous

nodules tracking toward regional lymphatics, and localized adenopathy.

## ■ CONFIRMATION

**6** The diagnosis of cutaneous leishmaniasis is best confirmed by which test or tests?

- ☐ Leishmanin skin test (Montenegro reaction)
- ☐ Acute and convalescent serology with enzyme-linked immunosorbent assay
- ☐ Characteristic cytopathic effect on viral shell culture or Tzanck preparation
- ☐ Parasite culture or polymerase chain reaction (PCR)
- ☐ Dark-field microscopy

Visualizing or culturing the parasite or demonstrating its DNA by PCR confirms the diagnosis of cutaneous leishmaniasis.

### Obtaining a specimen

Specimens can be collected by skin scraping, saline-injected needle aspiration, slit-skin smear, or punch biopsy with touch-impression smears made by blotting the biopsy and then repeatedly touching it to a clean glass slide.<sup>10</sup> We have found that the use of skin scraping rather than full-thickness punch biopsy provides for a more easily interpreted microscopic examination. Since punch biopsy can also diagnose other conditions, it is recommended as a follow-up procedure if initial scrapings are unrevealing.

The lesion edge is traditionally considered the most fruitful location for biopsy; however, a study in Guatemala suggested that the middle of the lesion yields similar results.<sup>11</sup> Newer lesions in cutaneous leishmaniasis and those of diffuse cutaneous leishmaniasis contain the most amastigotes,<sup>12,13</sup> while chronic cutaneous lesions and those of mucosal leishmaniasis contain the fewest.<sup>12</sup>

### Microscopy

For microscopy, some of the collected sample is smeared onto glass slides and stained with Diff-Quik (Dade Behring, Newark, DE) or Giemsa stain and examined for amastigotes under oil immersion. The amastigote is a round-to-oval body about 1.5 to 4 µm in

diameter with an internal nucleus and a rod-shaped kinetoplast (a mitochondrial structure) (FIGURE 3). The kinetoplast distinguishes *Leishmania* from *Histoplasma capsulatum*, which otherwise has a similar appearance. With Giemsa staining, the amastigote cytoplasm is blue, the nucleus violet-blue, and the kinetoplast reddish to violet.<sup>9</sup> Sometimes the Brown Hopps tissue Gram stain accentuates the kinetoplast.<sup>14</sup>

### Culture

Culture of *Leishmania* requires special media: Novy-MacNeal-Nicolle biphasic media or supplemented Schneider insect medium. Cultures become positive between 1 and 30 days. The Leishmaniasis Diagnostic Laboratory at Walter Reed Army Institute of Research (Silver Spring MD; 301-319-9956) can assist those eligible for benefits through the Department of Defense. For civilians or those who are not Department of Defense beneficiaries, assistance is available at the Centers for Disease Control and Prevention (CDC) ([www.dpd.cdc.gov/dpdx/HTML/Contactus.htm](http://www.dpd.cdc.gov/dpdx/HTML/Contactus.htm)).

### PCR

PCR can be useful,<sup>15</sup> and when adapted to the TaqMan platform (Applied Biosystems, Foster City, CA) can yield results in a few hours.<sup>16</sup> If PCR is to be done, the sample (usually a skin scraping) should be placed in ethanol.

### Skin tests

Leishmanin skin tests (Montenegro reaction) use intradermal injection of killed promastigotes to assess cutaneous delayed hypersensitivity to *Leishmania*. They cannot distinguish between active and past infections and are not used in the United States.

## ■ TREATMENT

**7** Treatments for cutaneous leishmaniasis include all of the following except which one?

- ☐ Curettage or wide-margin surgical excision
- ☐ Parenteral pentavalent antimony compounds such as sodium stibogluconate

**Leishmania culture requires special media; the Army or CDC can help**





TABLE 3

### Characteristics of Old World cutaneous leishmaniasis for which parenteral treatment should be considered

Lesions over joints where scar would impede future range of motion  
 Multiple or large lesions  
 Cosmetically unacceptable  
 Lesions associated with evidence of potential local dissemination (adenopathy, subcutaneous nodules, satellite lesions)  
 Chronic lesion not healed for many months  
 Mucosal involvement  
 Immunocompromised host

THIS TABLE WAS REPRINTED FROM LESHO EP, WORTMANN G, NEAFIE RC, ARONSON NE. CUTANEOUS LEISHMANIASIS: BATTLING THE BAGHDAD BOIL. FEDERAL PRACTITIONER 2004; 21(10):59–67. COPYRIGHT 2004 BY FEDERAL PRACTITIONER, QUADRANT HEALTHCOM INC. IT APPEARS HERE WITH THE PERMISSION OF QUADRANT HEALTHCOM INC. THIS TABLE MAY NOT BE REPRODUCED WITHOUT THE PRIOR WRITTEN PERMISSION OF QUADRANT HEALTHCOM INC.

- ☐ or meglumine antimoniate
- ☐ Oral imidazole compounds (for certain species, but not all)
- ☐ Local thermal therapies
- ☐ Topical paromomycin
- ☐ No treatment for small or single lesions if not on the face or ears, or over joints

Physical methods such as scraping, curettage, cauterization, or surgical excision have been employed to treat cutaneous leishmaniasis with varying degrees of success, but there is some concern about the possibility of lymphatic dissemination.<sup>17</sup> Therefore, these should not be considered first-line treatments.

#### Treatment vs no treatment

Although cutaneous leishmaniasis is usually self-limited and heals without any intervention, there are situations in which treatment should be considered or offered because of the potential for cosmetically unacceptable scarring or loss of joint mobility (TABLE 3).

#### Pentavalent antimony compounds

The therapeutic mainstays for over 60 years for both New World and more-severe Old World cutaneous leishmaniasis are pentavalent antimony compounds—either **meglumine antimoniate** (Glucantime; Specia Rhone Poulenc, France) or **sodium stibogluconate** (Pentostam; GlaxoSmithKline, United Kingdom). Both are

given parenterally.

**Availability.** Neither drug is approved by the US Food and Drug Administration (FDA), and therefore both must be used under a research investigational new-drug protocol.

Only sodium stibogluconate is available in the United States. Military patients can get it at two leishmaniasis treatment centers: Walter Reed Army Medical Center, Washington, DC, or Brooke Army Medical Center, San Antonio, TX. Physicians can acquire sodium stibogluconate for civilian patients from the CDC Drug Services section; in the past year the CDC has released it for three civilian patients with Old World cutaneous leishmaniasis.<sup>18</sup>

**Side effects.** Elevations of pancreatic and liver-associated enzymes are very common side effects of sodium stibogluconate, as are arthralgias and myalgias.<sup>19,20</sup> All are usually reversible.<sup>19</sup> However, fatal pancreatitis has been reported.<sup>21</sup> Thrombocytopenia, leukopenia, anemia, rash, anorexia, headache, fatigue, gastrointestinal symptoms, and reactivated herpes zoster have also been reported.<sup>19,22,23</sup>

The most common electrocardiographic changes are ST-segment and T-wave changes; prolongation of the corrected QT interval to more than 0.5 seconds is an indication to temporarily discontinue therapy.<sup>19,24</sup>

**Efficacy.** At the currently recommended dosage of 20 mg/kg/day for 20 days, the report-

**Sodium stibogluconate is available only from the Army or the CDC**

ed efficacy of pentavalent antimony ranges from 45% to 100%, depending on the species of *Leishmania*.<sup>13,19,25–27</sup>

### Lipid-associated amphotericin compounds

Lipid-associated amphotericin compounds might in theory target *Leishmania* because the amphotericin B-lipid complexes are cleared from the blood by monocytes and macrophages, where the parasite persists. However, whether these drugs achieve sufficient concentration in the skin to be effective is questionable.<sup>28</sup> None of them has been compared with conventional amphotericin B, and furthermore, they are FDA-approved only for visceral leishmaniasis at this time.

### Liposome-entrapped antimony

Liposome-entrapped antimony has shown promising results in vitro, but may have the same problem achieving adequate concentration in the skin as the lipid-associated amphotericin compounds do.<sup>29</sup>

### Oral imidazole compounds

Oral imidazole compounds have been used for cutaneous leishmaniasis with varying degrees of success depending on the *Leishmania* species.

Ketoconazole has been used for cutaneous leishmaniasis caused by *L major* and *L mexicana* but was less effective against *L tropica*, *L aethiopica*, and *L braziliensis*.<sup>30,31</sup>

A randomized controlled trial using itraconazole 7 mg/kg/day for 3 weeks for *L major* showed no significant difference from placebo (59% healing vs 44%).<sup>32</sup>

In a randomized controlled trial of treatment of *L major*, oral fluconazole 200 mg daily for 6 weeks reduced the time to healing by 3 weeks and resulted in a 59% healing rate at 3 months vs 22% in the placebo group.<sup>33</sup>

### Local or topical treatments

Since parenteral antimony injections may be inconvenient and toxic, investigators have sought alternatives such as topical or local treatments of cutaneous lesions. These can be considered if there are no signs of localized dissemination, the lesion is of modest size and number, and the species is not associated with late mucosal or visceral complications.

#### Topical paromomycin (aminosidine)

mixed with methylbenzethonium chloride (Leshcutan; Teva Pharmaceuticals, Israel) has been used to treat *L major*; the reported efficacy was 74% at 10 to 20 days.<sup>34</sup> In subsequent randomized controlled trials, other paromomycin preparations without methylbenzethonium chloride were not as effective.<sup>35</sup> Currently, topical paromomycin is not FDA-approved in the United States, although paromomycin capsules are.

**Intralesional injection of pentavalent antimony** delivers high concentrations of antimony directly to the infected lesions, uses less of the drug, and avoids systemic toxicity. However, results show inconsistent efficacy, and the treatment is time-consuming and painful. In one study,<sup>36</sup> intralesional injection was as effective as daily intramuscular therapy and led to faster improvement.

**Heat and cold.** Because *Leishmania* parasites are thermosensitive, clinical investigators have also attempted both heat and cold application.<sup>37–42</sup>

A placebo-controlled trial of heat in New World cutaneous leishmaniasis showed similar healing after three treatment sessions compared with parenteral pentavalent antimony.<sup>42</sup> A large randomized controlled trial in Afghanistan showed that topical therapy using an FDA-cleared device (ThermoMed) was as effective as a 20-day course of parenteral pentavalent antimony.<sup>26</sup>

Cryotherapy with liquid nitrogen has been used with variable success (27% to 92%) but can result in skin hypopigmentation.<sup>41</sup> Efficacy was improved when it was used in combination with intralesional pentavalent antimony.<sup>38</sup>

## ■ PREVENTING LEISHMANIASIS

**8** All of the following are effective in preventing leishmaniasis except which one?

- ☐ Standard mosquito netting
- ☐ Repellents that contain N,N-diethyl-3-methylbenzamide (DEET)
- ☐ Minimizing or eliminating exposure with garments
- ☐ Vaccination by leishmanization
- ☐ Permethrin impregnation of clothing

**Local or topical treatment can be considered in selected cases**

Sand flies are smaller than most mosquitoes and so may pass through some standard larger-weave mosquito netting, particularly if it has not been treated with insect repellent (eg, permethrin). Effective netting must be a fine mesh (at least 18 holes to the linear inch, which limits air flow) and must be treated with permethrin. Sand flies feed mostly at night.

Helpful measures for individual protection include wearing long sleeves and trousers, using insect repellents, and impregnating mosquito nets and clothing with permethrin.

Insect repellents containing DEET are effective. On average, products containing 100% DEET are effective for 9.5 hours, 30% DEET for 6.5 hours, 15% DEET for 5 hours, 10% DEET for 3 hours, and 5% DEET for 2 hours.<sup>43</sup> Controlled-release preparations containing 20% to 35% DEET may be effective for 8 to 12 hours or more. High temperature and humidity may reduce the duration of a repellent's effectiveness.<sup>43</sup> In general, adults and children older than 12 years should use preparations containing 25% to 35% DEET.<sup>43</sup>

Reservoir control measures include bulldozing gerbil burrows, destroying infected dogs, and providing the dog population with deltamethrin-impregnated collars.

Vaccines against *Leishmania* are being investigated, but there are no products available in the United States. In general, recovery from leishmaniasis provides protection from reinfection with the same type. This is the rationale for the practice of scarification with small doses of *L major* in body sites usually covered by clothes as an immunoprophylactic strategy in some parts of the world. Although this method (leishmanization) resulted in total or partial protection against a subsequent infection,<sup>44,45</sup> it has been generally abandoned due to the risk of occasional severe or persis-

tent lesions and concern about introducing a live virulent organism into humans.

## ■ PREVENTING TRANSMISSION

**9** The reservist has been a committed regular blood donor. Since his disease was limited to the cutaneous form of leishmaniasis, he will be able to resume donations after a 1-year deferment, but his diagnosis must be reported to the local health authorities. True or false?

False. Members of the US Armed Forces with leishmaniasis of any type are subject to a life-long deferment of blood donation.<sup>46</sup> However, a patient is of no risk to family or friends. Sand flies in the United States can potentially transmit leishmaniasis, yet there appear to be relationships specific to species and vector, resulting in no reports of secondary US transmission from cutaneous cases. There is no requirement to report cases to public health authorities.

## ■ SUMMARY

US health care providers who are not familiar with cutaneous leishmaniasis may now begin to encounter more patients with this challenging entity as military personnel return from rotations in Iraq or Afghanistan.

Diagnosis requires a skin scraping, aspiration, or biopsy, followed by examination by an experienced microscopist or pathologist. Demonstration of the parasite DNA by PCR or culture in special media can also be used to confirm the diagnosis.

Sodium stibogluconate is the mainstay of therapy, but other options for selected cases include topical thermal or cryotherapy treatment and oral triazole compounds. Assistance is available through the CDC and, for Department of Defense beneficiaries, certain military facilities.

**Leishmaniasis patients pose no risk to family or friends**

## ■ REFERENCES

1. **Caumes E, Carriere J, Guernonprez G, Bricaire F, Danis M, Gentilini M.** Dermatoses associated with travel to tropical countries: a prospective study of the diagnosis and management of 269 patients presenting to a tropical disease unit. *Clin Infect Dis* 1995; 20:542–548.
2. **Dowlati Y.** Cutaneous leishmaniasis: clinical aspect. *Clin Dermatol* 1996; 14:425–431.
3. **Desjeux P.** Leishmaniasis: public health aspects and control. *Clin Dermatol* 1996; 14:417–423.
4. **Centers for Disease Control and Prevention.** Update: cutaneous leishmaniasis in U.S. military personnel—Southwest/Central Asia, 2002–2004. *MMWR* 2004; 53(12):264–265.
5. **Weina PJ, Neafie RC, Wortmann G, Polhemus M, Aronson NE.** Old World leishmaniasis: an emerging infection among deployed US military and civilian workers. *Clin Infect Dis* 2004; 39:1674–1680.





6. Reithinger R, Mohsen M, Addil K, et al. Anthroponotic cutaneous leishmaniasis, Kabul Afghanistan. *Emerg Infect Dis* 2003; 9:727–729.
7. Locksley RM, Heinzel FP, Sadick MF, Holaday BJ, Gardner KD Jr. Murine cutaneous leishmaniasis: susceptibility correlates with differential expansion of helper T-cell subsets. *Ann Inst Pasteur Immunol* 1987; 138:744–749.
8. Magill AJ, Grogl M, Gasser RA, Sun W, Oster CN. Visceral infection caused by *Leishmania tropica* in veterans of Operation Desert Storm. *N Engl J Med* 1993; 328:1383–1387.
9. Herwaldt BL. Leishmaniasis. *Lancet* 1999; 354:1191–1199.
10. Armed Forces Institute of Pathology. Cutaneous leishmaniasis (CL). [www.afip.org/Departments/infectious/index.html](http://www.afip.org/Departments/infectious/index.html). Accessed December 1, 2004.
11. Navin TR, Arana FE, de Merida AM, Arana BA, Castillo AL, Silvers DN. Cutaneous leishmaniasis in Guatemala: comparison of diagnostic methods. *Am J Trop Med Hyg* 1990; 42:36–42.
12. Dedet JP, Pratlong F. Leishmaniasis. In: Cook G, Zumla A, editors. *Manson's Tropical Diseases*. 21st ed. London; Elsevier Science Limited; 2003:1339–1364.
13. Neva F, Sacks D. Leishmaniasis. In: Warren K, Mahmoud AAF, editors. *Tropical and Geographical Medicine*. 2nd ed. New York; McGraw-Hill, Inc; 1990:296–308.
14. Personal communication. P. McEvoy, Armed Forces Institute of Pathology, Washington, DC; April 2004.
15. Vega-Lopez F. Diagnosis of cutaneous leishmaniasis. *Curr Opin Infect Dis* 2003; 16:97–101.
16. Wortmann G, Sweeney C, Hough HS, et al. Rapid diagnosis of leishmaniasis using fluorogenic polymerase chain reaction. *Am J Trop Med Hyg* 2001; 65:583–587.
17. Griffiths WAD, Croft SL. Cutaneous leishmaniasis. *Postgrad Doctor Med East* 1980; 3:388–394.
18. Personal communication. Dr. Barbara Herwaldt, CDC. December 3, 2004.
19. Aronson NE, Wortmann GW, Johnson SC, et al. Safety and efficacy of intravenous sodium stibogluconate in the treatment of leishmaniasis: recent U.S. military experience. *Clin Infect Dis* 1998; 27:1457–1464.
20. Gasser RA Jr, Magill AJ, Oster CN, Franke ED, Grogl M, Berman JD. Pancreatitis induced by pentavalent antimonial agents during treatment of leishmaniasis. *Clin Infect Dis* 1994; 18:83–90.
21. McBride MO, Linney M, Davidson RN, Weber JN. Pancreatic necrosis following treatment of leishmaniasis with sodium stibogluconate. *Clin Infect Dis* 1995; 21:710.
22. Centers for Disease Control and Prevention. Informational Material for Physicians from the Centers for Disease Control and Prevention about Pentostam (Sodium Stibogluconate). Atlanta, GA: CDC Drug Services; August 19, 1995. CDC publication 0303.
23. Pentostam [package insert]. Uxbridge, UK; GlaxoSmithKline. 2003.
24. Chulay JD, Spencer HG, Mugambi M. Electrocardiographic changes during treatment of leishmaniasis with pentavalent antimony (sodium stibogluconate). *Am J Trop Med Hyg* 1985; 34:702–709.
25. Wortmann G, Miller R, Oster C, et al. A randomized, double-blind study of the efficacy of a 10- or 20-day course of sodium stibogluconate for treatment of cutaneous leishmaniasis in United States military personnel. *Clin Infect Dis* 2002; 35:261–267.
26. Reithinger R, Mohsen M, Kolaczinski J, Davies CR, David JR. A randomized controlled trial to test the efficacy of thermotherapy against *Leishmania tropica* in Kabul, Afghanistan. Abstract #776 in vol 69, No 3 Program and Abstracts of the 52nd Annual Meeting of the American Society of Tropical Medicine and Hygiene. Philadelphia, PA. December 3–7, 2003.
27. Ballou WR, McClain JB, Gordon DM, et al. Safety and efficacy of high-dose sodium stibogluconate therapy of American cutaneous leishmaniasis. *Lancet* 1987; 2(8549):13–16.
28. Wortmann GW, Fraser SL, Aronson NE, et al. Failure of amphotericin B lipid complex in the treatment of cutaneous leishmaniasis. *Clin Infect Dis* 1998; 26:1006–1007.
29. Tempone AG, Perez D, Rath S, Vilarinho AL, Mortara RA, de Andrade HF Jr. Targeting *Leishmania (L.) chagasi* amastigotes through macrophage scavenger receptors: the use of drugs entrapped in liposomes containing phosphatidylserine. *J Anticancer Chemother* 2004; 54:60.
30. Alkhawajah A. Recent trends in the treatment of cutaneous leishmaniasis. *Ann Saudi Med* 1998; 18:412–416.
31. Navin TR, Arana BA, Arana FE, Berman JD, Chajon JF. Placebo-controlled clinical trial of sodium stibogluconate (Pentostam) versus ketoconazole for treating cutaneous leishmaniasis in Guatemala. *J Infect Dis* 1992; 165:528–534.
32. Momeni AZ, Jalayer T, Emamjomeh M. Treatment of cutaneous leishmaniasis with itraconazole. Randomized double-blind study. *Arch Dermatol* 1996; 132:784–786.
33. Alrajhi AA, Ibrahim EA, De Vol EB, Khairat M, Faris RM, Maguire JH. Fluconazole for the treatment of cutaneous leishmaniasis caused by *Leishmania major*. *N Engl J Med* 2002; 346:891–894.
34. El-On J, Livshin R, Even-Pas Z, Hamburger D, Weinrauch L. Topical treatment of cutaneous leishmaniasis. *J Invest Dermatol* 1986; 87:284–288.
35. Soto J, Fuya P, Herera R, Berman J. Topical paromomycin/methylbenzethonium chloride plus parenteral meglumine antimonite as treatment for American cutaneous leishmaniasis: controlled study. *Clin Infect Dis* 1998; 26:56–58.
36. Alkhawaja AM, Larbi E, Al-Gindan Y, Abahusseine A, Jain S. Treatment of cutaneous leishmaniasis with antimony: intramuscular vs. intralesional administration. *Ann Trop Med Parasitol* 1997; 91:899–905.
37. Asilian A, Sadeghinia A, Faghihi G, Momeni A, Amini Harndi A. The efficacy of treatment with intralesional meglumine antimoniate alone, compared with that of cryotherapy combined with the meglumine antimoniate or intralesional sodium stibogluconate, in the treatment of cutaneous leishmaniasis. *Ann Trop Med Parasitol* 2003; 97:493–498.
38. Asilian A, Sadeghinia A, Faghihi G, Momeni A. Comparative study of the efficacy of combined cryotherapy and intralesional meglumine antimoniate (Glucantime) vs. cryotherapy and intralesional meglumine antimoniate (Glucantime) alone for the treatment of cutaneous leishmaniasis. *Int J Dermatol* 2004; 43:281–283.
39. Berman JD. Human leishmaniasis: clinical, diagnostic and chemotherapeutic developments in the last 10 years. *Clin Infect Dis* 1997; 24:684–703.
40. Bassiony A, El-Mashad M, Talaat M, Kutty K, Metaawa B. Cryotherapy in cutaneous leishmaniasis. *Br J Dermatol* 1982; 107:467–474.
41. Al-Gindan Y, Kubba R, Omer AH, el-Hassan AM. Cryosurgery in old world cutaneous leishmaniasis. *Br J Dermatol* 1988; 188:851–854.
42. Navin TR, Arana BA, Arana FE, de Merida AM, Castillo AL, Pozuelos JL. Placebo-controlled clinical trial of meglumine antimonate (Glucantime) vs. localized controlled heat in the treatment of cutaneous leishmaniasis in Guatemala. *Am J Trop Med Hyg* 1990; 42:43–50.
43. Fradin MS. Mosquitoes and mosquito repellents—a clinician's guide. *Ann Intern Med* 1998; 120:931–940.
44. Greenblatt CL. Cutaneous leishmaniasis: the prospects for a killed vaccine. *Parasitol Today* 1988; 4:53–54.
45. Modabber F. Development of vaccines against leishmaniasis. *Scand J Infect Dis* 1990; 76:72–78.
46. Sylvester RD. Blood donor deferral for leishmaniasis in Iraq. [www.nehc.med.navy.mil/downloads/prevmed/leishmanAug03.pdf](http://www.nehc.med.navy.mil/downloads/prevmed/leishmanAug03.pdf). Accessed December 1, 2004.

ADDRESS: LTC Emil P. Lesho, Walter Reed Army Medical Center, Washington, DC.