



Diagnosis and evaluation of pulmonary hypertension

MARIE M. BUDEV, DO, MPH; ALEJANDRO C. ARROLIGA, MD; AND CONSTANCE A. JENNINGS, MD

■ ABSTRACT

The diagnosis of pulmonary hypertension (PH) relies on a high index of suspicion. In patients with symptoms or chest radiographic findings suggestive of PH, a detailed history and physical examination followed by early assessment with a transthoracic echocardiogram, ventilation-perfusion scanning, chest computed tomography, pulmonary function testing, and nocturnal oximetry screening can provide valuable information about etiology and severity. Right heart catheterization should follow in patients who are symptomatic or who demonstrate moderate to severe PH by echocardiography and are candidates for treatment. Patients at risk for developing PH should undergo serial echocardiography and pulmonary function testing to assess for disease development and progression. Genetic testing is not currently recommended in the routine evaluation of patients with a diagnosis of primary pulmonary hypertension.

Pulmonary hypertension (PH) often presents in an insidious manner, requiring a high index of suspicion by the clinician making the diagnosis. In many cases the diagnosis

may be delayed because of the nonspecificity of symptoms and the relative rarity of PH. The National Institutes of Health's Primary Pulmonary Hypertension Patient Registry noted that the mean interval from the onset of symptoms to diagnosis is about 2 years.¹ Patient evaluation for PH should be directed to establish the etiology and the severity of the disease (**Table 1, Figure 1**), both of which will influence the selection of treatment strategies. This article reviews the diagnostic workup and evaluation for patients with known or suspected PH and the role of genetic testing and screening.

■ HISTORY-TAKING: THOROUGHNESS IS KEY

The symptoms of PH are nonspecific and often are difficult to differentiate from those of other pulmonary or cardiovascular diseases, so a thorough clinical history should be taken for all patients with suspected PH. Dyspnea on exertion is by far the most common complaint. Up to one third of patients with PH and normal coronary arteries report chest pain, which probably is attributable to increased myocardial oxygen demand caused by elevated right ventricular wall stress from dilation or hypertrophy or by reduced oxygen supply from decreased myocardial blood flow.² Syncope or presyncope may occur in one third of patients with PH owing to a reduced, fixed cardiac output, atrial or ventricular arrhythmias, or right ventricular ischemia.³ Syncope is an ominous sign and usually indicates severe PH with marked elevation of right heart pressures. Rarely, patients may complain of hoarseness (Ortner syndrome) attributable to impingement of the left recurrent laryngeal nerve between the aorta and a dilated left pulmonary artery.⁴

The composite effect of elevated pulmonary

From the Department of Pulmonary and Critical Care Medicine, The Cleveland Clinic Foundation, Cleveland, Ohio.

Address: Constance A. Jennings, MD, Department of Pulmonary and Critical Care Medicine, A90, The Cleveland Clinic Foundation, 9500 Euclid Avenue, Cleveland, OH 44195; e-mail: jenninc@ccf.org.

Disclosure: All of the authors have indicated that they have no commercial affiliations or interests that pose a potential conflict of interest with this article.

TABLE 1**Hemodynamic classification
of pulmonary hypertension****Precapillary pulmonary hypertension**

Primary pulmonary hypertension
 Pulmonary arterial hypertension due to collagen
 vascular disease
 Eisenmenger syndrome
 Portopulmonary hypertension
 HIV-associated pulmonary arterial hypertension
 Pulmonary arterial hypertension due to appetite
 suppressants
 Pulmonary hypertension induced by high altitude,
 obstructive sleep apnea, or hypoxia
 Thromboembolic pulmonary hypertension

Postcapillary pulmonary hypertension

Left ventricular systolic or diastolic dysfunction
 Aortic stenosis or regurgitation
 Primary mitral regurgitation
 Mitral valve obstruction
 Pulmonary veno-occlusive disease

Mixed pulmonary hypertension

Chronic primary systolic left ventricular failure
 Aortic stenosis
 Chronic aortic and primary mitral regurgitation
 Mitral valve obstruction

**Selective or nonselective increases
in pulmonary blood flow**

Atrial septal defect
 Ventricular septal defect
 Patent ductus arteriosus
 High-output cardiac failure (thyrotoxicosis, Paget disease)
 Liver disease
 Chronic anemia

artery pressure, exertional hypoxemia, and reduced right ventricular performance can be gauged clinically according to the New York Heart Association (NYHA) functional classification, by which patients may report dyspnea with ordinary physical activity (class II), with less than ordinary activity (class III), or at rest (class IV).⁵ Functional classification has a high correlation with prognosis and a significant impact on treatment selection.⁶

Since most patients have an underlying etiology that explains the presence of PH, careful attention should be given to symptoms related to associated diseases. In addition, patients with underlying dis-

eases that predispose to PH should undergo a careful history directed at the symptoms of PH.⁷

Patients with connective tissue disease should be evaluated especially carefully with respect to pulmonary arterial hypertension (PAH). Patients with scleroderma who have PAH have a higher mortality than those without PAH,^{8,9} and recent clinical studies have indicated a 30% to 35% prevalence of PAH in scleroderma patients,¹⁰⁻¹² although earlier retrospective studies based on autopsy or surgical pathology specimens reported a higher incidence.^{13,14} Pulmonary arterial hypertension occurs in 9% to 14% of patients with systemic lupus erythematosus and carries a 2-year mortality rate of greater than 50% in these patients.¹⁵ Factors associated with an increased incidence of PAH include use of cytotoxic agents, presence of Raynaud phenomenon, renal disease, ribonucleoprotein antibody, and circulating lupus anticoagulant.¹⁶ The mean duration of systemic lupus at the time of PAH diagnosis is 2.4 years; however, because PAH may be the presenting symptom, a careful history directed toward symptoms associated with systemic lupus erythematosus is advised.¹⁷

History-taking in patients with possible PAH should specifically seek to identify risk factors associated with human immunodeficiency virus (HIV) infection since studies have indicated a shorter average duration of symptoms attributable to PAH and a faster disease evolution in HIV-infected patients.^{18,19}

A detailed medication history should be elicited that includes use of illicit drugs, prescription medicines, over-the-counter remedies, and herbal supplements. A known association exists between PAH and a history of appetite suppressant use (dexfenfluramine, fenfluramine, and phentermine), with a relative risk for PAH after 3 months of use that is approximately 23-fold higher than that of the general population.²⁰

A history suggestive of other diseases with known associations with PH should be sought, including pulmonary thromboemboli, hepatic disease, thyroid disease, sickle cell disease, congenital heart disease, conditions associated with elevated left heart pressures, and conditions associated with hypoxemia.²

■ THE PHYSICAL EXAMINATION: A WINDOW INTO ETIOLOGY, SEVERITY

The physical examination in a patient with suspected PH may yield valuable information about the eti-

ology and severity of the disorder. The most consistent finding in patients with PH is an increased pulmonic component of the second heart sound (P_2). Elevation of the jugular venous pulsations, murmurs of pulmonic and tricuspid insufficiency, and a right ventricular heave with an S_3 gallop are secondary findings also associated with PH.²¹ Physical signs of underlying causes of PH may be present and include²¹:

- central cyanosis due to Eisenmenger syndrome (right-to-left intracardiac shunting)
- clubbing due to congenital heart disease, interstitial lung disease, or hepatic cirrhosis
- hepatomegaly, ascites, or spider angiomas, indicating underlying cirrhosis
- scleroderma, sclerodactyly, telangiectasias, or other findings indicating an underlying connective tissue disease.

■ DIAGNOSTIC TESTING: MANY TOOLS CAN AID ASSESSMENT

Because of the nonspecificity of symptoms and the subtlety of physical signs in most patients with PH, the history and physical examination provide only limited information on the presence and severity of disease. The following investigational tools can supplement the history and examination in assessing the presence and severity of PH.

Echocardiography

Transthoracic echocardiography should be performed as the initial study in patients suspected of having PH, owing to its sensitivity and noninvasiveness.⁵ Doppler echocardiography is used to estimate the right ventricular systolic pressure by measuring tricuspid regurgitation velocity, and also provides information about the size and function of the right ventricle, as well as estimates of right atrial pressure.²¹ Right ventricular systolic pressure estimates by echocardiography correlate well with pulmonary artery systolic pressure by right heart catheterization in patients with PH.^{22,23} However, the right ventricular systolic pressure may be underestimated in some cases because of suboptimal tracings of the regurgitant jet, decreased tricuspid regurgitation jet velocity due to high right atrial pressures, or poor estimation of right atrial pressures.^{2,24} Thus, all patients with a significantly elevated right ventricular systolic pressure on transthoracic echocardiography and those evoking a high degree

of clinical suspicion for significant PH despite a normal transthoracic echocardiogram should undergo right heart catheterization for confirmation, especially if they are candidates for treatment.

Transthoracic echocardiography may also provide valuable clues about the presence of cardiac causes of PH, such as left ventricular systolic or diastolic dysfunction, mitral valve disease, and intracardiac shunting. Bubble contrast echocardiography provides information on significant intracardiac shunting, but if visualization of the atrial septum is inadequate, transesophageal echocardiography or right heart catheterization with oximetry may be required.² Transesophageal echocardiography is especially helpful in detecting atypically situated sinus venous atrial septal defects, anomalous pulmonary venous return, and centrally located pulmonary thrombi.²⁵

Because of the high prevalence of PAH in patients with scleroderma, all patients with scleroderma should undergo screening transthoracic echocardiography.²⁶ However, routine echocardiographic screening is not recommended for patients with systemic lupus erythematosus unless they have symptoms consistent with PAH. First-degree relatives of patients with primary pulmonary hypertension (PPH) should undergo transthoracic echocardiography at the time of diagnosis of the index case, every 3 to 5 years thereafter, and at any time symptoms arise that are suggestive of PAH.²

Other laboratory investigations

Chest radiography may indicate the presence of PH. A right descending pulmonary artery width greater than 17 mm has been associated with elevated pulmonary artery pressures.²⁷ Linear calcification of the right pulmonary artery indicates severe longstanding PH.²¹ A globular heart and decreased retrosternal air space may suggest right ventricular dilation or hypertrophy.²⁸ Abnormalities such as interstitial changes or emphysematous change may indicate the presence of underlying parenchymal disease, or nodular densities may suggest pulmonary vasculitis.²¹ Chest radiography and spirometry are abnormal in up to 73% of patients with PAH related to scleroderma.²⁹

Electrocardiography can frequently reveal evidence of right atrial or ventricular enlargement in patients with PH.²⁴

The **ventilation-perfusion scan** is the most useful screening test for pulmonary thromboemboli. At

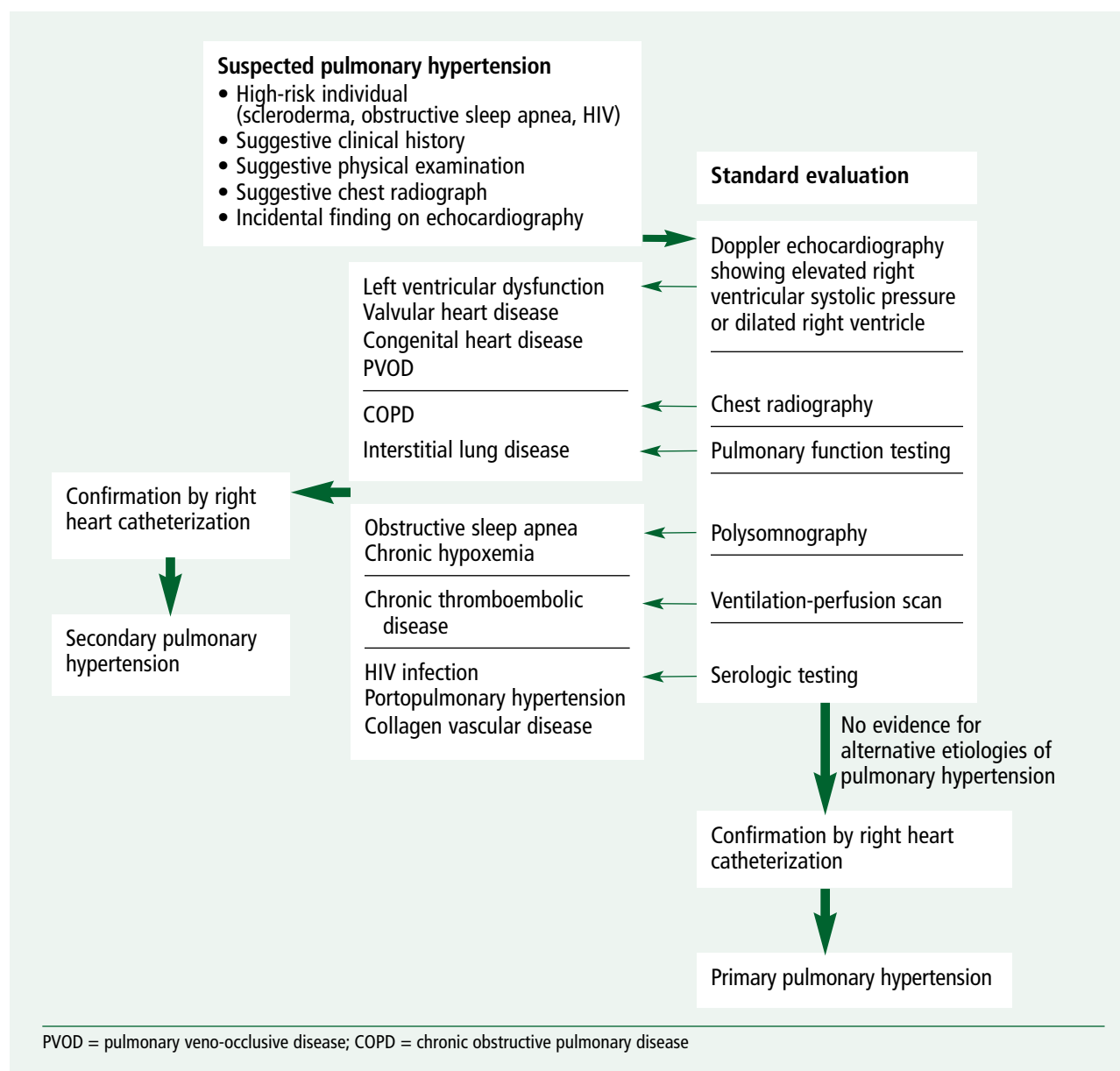


Figure 1. Clinical algorithm for the diagnosis of pulmonary hypertension.

least one segmental-sized or larger perfusion defect will be present in patients with chronic thromboembolic pulmonary hypertension, and most patients will have several segmental or lobar mismatched defects that give the scan a characteristic “moth-eaten” appearance.³⁰

For patients with a ventilation-perfusion scan suggestive of chronic thromboembolic pulmonary hypertension, **pulmonary angiography** can provide additional information on the extent and the loca-

tion of thromboemboli.² However, if residual thromboemboli are incorporated into the pulmonary arterial wall or are located distally in the small segments, conventional angiography may underestimate the extent of thrombus. In selected cases, **angiography** allows better visualization of thromboemboli and their surgical accessibility.^{31,32} **Intravascular ultrasound** may provide useful information on proximal thrombi amenable to thromboendarterectomy or in the differentiation between

acute and chronic thromboembolic disease.^{2,33,34}

Chest computed tomographic scanning is a useful part of the evaluation of patients with known or suspected PH. Helical studies with contrast are helpful in identifying proximal thromboembolic disease. An increased diameter of the main pulmonary artery (≥ 29 mm) is highly predictive of the presence of PH (sensitivity 84%, specificity 75%, positive predictive value 0.97), especially when seen in association with an artery-to-bronchus ratio greater than 1:1 in multiple lobes (specificity 100%).³⁵ High-resolution computed tomographic scans are helpful in diagnosing and staging interstitial lung disease and may suggest the possibility of chronic thromboembolic disease, with a “mosaic” pattern of the lung parenchyma, although this pattern is also associated with PH in the absence of thromboemboli.³⁶ A decreased density gradient between dependent and nondependent lung has also been described as an early indicator of PH.³⁷

Magnetic resonance imaging can be used to assess the size and function of the right ventricle, myocardial thickness, the presence of chronic thromboemboli, and cardiac and pulmonary pressures.³⁸ In a recent study, gadolinium-enhanced pulmonary **magnetic resonance angiography** showing a right pulmonary artery diameter greater than 28 mm allowed for the diagnosis of chronic PH with a high sensitivity (89%) and a high negative predictive value (94%).³⁹

Pulmonary function testing should be part of the initial evaluation of patients with known or suspected PH to assess for abnormalities of the pulmonary parenchyma or airways that may be relevant to the etiology of PH.²¹ A restrictive defect with a reduction in lung volumes to less than 80% of the predicted value is present in 20% of patients with chronic thromboembolic disease.³⁰ A reduction of the diffusion capacity of lung for carbon monoxide (DLCO) ($< 45\%$) out of proportion to a decline in the forced vital capacity has an 87% sensitivity in predicting PAH in patients with scleroderma² and may be the earliest sign of PAH in these patients.^{29,40} A partial pressure of carbon dioxide (PCO_2) value less than 30 mm Hg has been associated with high positive (87%) and negative (73%) predictive values for portopulmonary hypertension in patients with end-stage liver disease.⁴¹ Evaluation by **nocturnal oximetry screening** and/or **polysomnography** for evidence of obstructive sleep apnea and nocturnal hypoxemia is also advised since the results have

both diagnostic and therapeutic implications.

Maximum exercise testing is usually not performed in patients with PH because of the risk of syncope or sudden death.⁴² Submaximal testing with a 6-minute walk test is recommended at the time of diagnosis to establish baseline functional impairment and at follow-up to assess response to therapy and prognosis. The mortality risk is increased 2.4-fold in patients with PPH who are able to walk less than 300 m in 6 minutes and 2.9-fold in those with a greater than 10% decline in arterial oxygen saturation.⁴³ The 6-minute walk distance correlates with severity by NYHA functional class in patients with PPH, and patients who walk less than 332 m have a significantly lower survival rate than those who walk farther.⁴⁴

Lung biopsy is not without risk in patients with PH. It is usually reserved for cases in which a histopathologic diagnosis may alter treatment, such as when active vasculitis, granulomatous disease, pulmonary veno-occlusive disease, or interstitial lung disease is suspected.⁴⁵

Right heart catheterization

Right heart catheterization remains the gold standard for the diagnosis of PH. All patients suspected of having significant PH after clinical and transthoracic echocardiographic evaluation should undergo right heart catheterization, particularly if they are candidates for treatment. Right heart catheterization establishes the pulmonary artery pressure, pulmonary vascular resistance, and cardiac output, as well as the effect of vasodilators on these parameters.

Pulmonary hypertension is defined by right heart catheterization as a mean pulmonary artery pressure greater than 25 mm Hg at rest or greater than 30 mm Hg during exercise. The severity of PH is further classified on the basis of mean pulmonary artery pressure as mild (25 to 40 mm Hg), moderate (41 to 55 mm Hg), or severe (> 55 mm Hg).⁴⁶ Pulmonary hypertension secondary to left heart disease or chronic obstructive pulmonary disease usually presents with mild to moderate elevation of mean pulmonary artery pressures (25 to 45 mm Hg). More severe PAH is typically found in PPH, in the setting of collagen vascular disease, or in chronic pulmonary thromboembolism.⁶ In most cases of portopulmonary hypertension the increase in pressures is mild with minimal elevations in pulmonary vascular resistance, although a subset of patients with severe PH with elevated pulmonary vascular resistance are dis-

TABLE 2
Hemodynamic profile in pulmonary hypertension

Type	Pulmonary capillary wedge pressure	Pulmonary artery pressure (systolic, diastolic, mean)	Pulmonary vascular resistance	Pulmonary artery end diastolic pressure
Precapillary pulmonary hypertension	Normal	↑	↑	5–15 mm Hg higher than pulmonary capillary wedge pressure
Postcapillary pulmonary hypertension	↑	↑	Normal	5–15 mm Hg higher than pulmonary capillary wedge pressure
Mixed pulmonary hypertension	↑	↑	↑	Modestly higher than pulmonary capillary wedge pressure
Selective or nonselective increases in pulmonary blood flow	Inaccurate because of high pulmonary artery pressures	↑↑	Normal or ↑	↑

tinguished by right heart catheterization.⁴⁷

A decreased mixed venous saturation consistent with low cardiac output has been found to be a strong predictor of poor outcome in some studies. Any subsequent increase in the mixed venous saturation with treatment may indicate an improvement in the cardiac index that is due to decreased right ventricular afterload.⁴²

In some symptomatic patients with evidence of only mild or moderate elevation of pulmonary artery systolic pressures on echocardiography, measurement of hemodynamics at rest and during exercise by echocardiography may be needed to establish PH as the etiology of symptoms. In these patients, right heart catheterization can provide helpful additional data. In precapillary PH, the pulmonary artery pressures and resistance are elevated at rest but the pulmonary capillary wedge pressure is normal (Table 2). During exercise, the pressure increases, but the normal decrease in vascular resistance does not occur.

In cases where the pulmonary capillary wedge pressure is noted to be elevated, the diagnosis of pulmonary veno-occlusive disease or left-sided heart disease should be considered.⁴ In older patients, the pulmonary capillary wedge pressure may increase (>30 mm Hg) during exercise because of decreased left ventricular compliance. These patients should be treated for systemic hypertension and diastolic

dysfunction but should not be aggressively treated for PH.^{2,21} In certain cases a mixed hemodynamic picture may be present owing to progressive pulmonary vasculopathy in response to chronic elevation of the pulmonary capillary wedge pressure.

Some patients with mild to moderate PH can be followed or managed without right heart catheterization. Those with mild to moderate PH due to chronic hypoxemia (resting, exertional, or nocturnal) can be followed with serial echocardiography for evidence of progression on appropriate oxygen and/or nocturnal ventilatory support. For patients with mild to moderate PH by echocardiography in the setting of other known causes, such as scleroderma, who do not have NYHA class III symptoms, right heart catheterization can be reserved as a future option if PH progresses on serial echocardiography (every 3 to 6 months).

■ GENETIC TESTING ADVANCES, BUT NOT YET RECOMMENDED

Primary pulmonary hypertension is usually sporadic, but in nearly 100 families in the United States the disease has occurred in at least two first-degree relatives. Documenting familial PPH can be difficult because of skipped generations resulting from incomplete penetrance or variable expression. Many individuals in families with PPH may inherit

the gene and have children with PPH yet never develop PPH themselves. The female-to-male ratio, age at disease onset, and natural history of PPH are similar between patients with the familial form of PPH and those with the sporadic form.⁴⁸

The locus designation gene for familial PPH, known as *PPH1*, is on chromosome 2q31–32 and is transmitted in an autosomal dominant manner. Familial PPH is caused by mutations in the bone morphogenetic protein receptor type II gene (*BMPR2*), which encodes a transforming growth factor beta ($\text{TGF-}\beta$) receptor. The $\text{TGF-}\beta$ signaling pathway appears to be involved in the pathogenesis of PPH and may provide a target for future therapies.⁴⁹

A complete family history should be obtained in every patient with PPH. Because there is a lifetime penetrance of 10% to 20%, the likelihood of a first-degree relative being affected by PPH is about 0.6% to 1.2% when only one individual in the family has PPH, even if the *PPH1* gene is present. If there is a second case in the family, the lifetime risk rises to 5% to 10%. Offspring of an affected parent have a 5% to 10% lifetime risk of developing PPH.⁴⁸

Most experts advise against genetic testing of family members of patients with PPH because knowledge of the gene and its interaction with other factors contributing to PH is still in its infancy and because the overall risk in first-degree relatives is low. When genetic testing is performed, it is critical to ensure both appropriate genetic analysis and appropriate genetic counseling.⁵⁰

Primary pulmonary hypertension has also been associated with autoimmune phenomena, but the genetic significance remains unclear.⁵⁰

■ SPECIAL SITUATIONS

Certain diseases and clinical states are associated with an increased prevalence of PH. We conclude by presenting the following recommendations on screening strategies for select population subgroups with factors that put them at risk for PH.

Systemic autoimmune disease

An elevated erythrocyte sedimentation rate and increased immunoglobulin G levels have been reported in patients with PAH due to scleroderma.^{51–53} Serologic studies show that antiphospholipid antibodies are almost twice as prevalent (60% to 68%) in systemic lupus erythematosus patients with PAH as compared to those patients without

PAH.⁵⁴ Assessing lupus anticoagulant and anticardiolipin antibodies may identify patients with systemic lupus erythematosus who are at increased risk for venous thromboemboli and PH.⁵⁴

Liver disease

The prevalence of PH is approximately 1% in patients with chronic liver disease or portal hypertension but is approximately 4% in patients undergoing orthotopic liver transplantation.⁵⁵ All patients being evaluated for liver transplantation should undergo transthoracic echocardiography to assess for portopulmonary hypertension since the presence of PH increases the risk of complications during transplantation. Transthoracic echocardiography is reported to be 97% sensitive and 77% specific in diagnosing moderate to severe PAH in patients with portal hypertension.^{56,57}

HIV infection, intravenous drug abuse

Pulmonary arterial hypertension is reported in 0.5% of HIV-infected patients.⁵⁸ It is not related to the degree of immunodeficiency or the duration of the disease. Diagnostic screening with transthoracic echocardiography is recommended only in HIV-infected patients who have symptoms consistent with PAH.^{59,60}

Pulmonary hypertension in patients with a history of intravenous drug abuse is caused by embolization of foreign particles that are injected with the drug. Because the presence of PH is variable in this population, screening with transthoracic echocardiography is recommended only in individuals with symptoms consistent with PH.⁶¹ Open lung biopsy is generally not indicated unless a confirmatory diagnosis of PH due to intravenous drug use needs to be established.

Hyperthyroidism

Pulmonary hypertension in patients with hyperthyroidism may be due to a high cardiac output state, endothelial damage, increased metabolism of intrinsic pulmonary vasodilating substances, or increased cholinergic output and reduced vasodilator response.^{62,63} The usefulness of screening echocardiography in these patients is unclear.

Obstructive sleep apnea and parenchymal lung disease

There is a well-described association between obstructive sleep apnea and PH. Prevalence rates of

PH in patients with obstructive sleep apnea range from 17% to 79%; PH is usually mild in these patients but may be severe.⁶⁴ The etiology is most likely multifactorial and related to a combination of daytime and nocturnal hypoxemia, changes in pleural pressure, alveolar hypoventilation, and elevated endothelin levels.⁶⁵ Patients with sleep apnea documented by polysomnography with symptoms of dyspnea should be screened for PH with echocardiography.⁶⁶ One recent study found that 22% of patients with severe obstructive sleep apnea (defined as an apnea-hypopnea index > 30) had evidence of daytime PH.⁶⁷

Patients with parenchymal lung disease leading to resting, nocturnal, or exertional hypoxemia may also develop PH. Echocardiographic screening in

this setting is based on abnormal cardiac auscultation, rapid exertional desaturation, and progression of dyspnea or hypoxemia in the context of stable lung volumes and flows.

Other conditions

Pulmonary hypertension has been associated with other conditions, including hypothyroidism, L-tryptophan use, hyperuricemia, and sickle cell disease, but the predictive value of early screening is not yet clear.² A recent clinicopathologic study of 20 cases of sickle cell hemoglobinopathy noted a high prevalence of PH and high mortality. These groups of patients may benefit from regular periodic assessments for PH with directed history, physical examination, and transthoracic echocardiography.⁶⁸

REFERENCES

- Rich S, Danzker DR, Ayres S, et al. Primary pulmonary hypertension: a national prospective study. *Ann Intern Med* 1987; 107:216–223.
- McGoon M. The assessment of pulmonary hypertension. *Clin Chest Med* 2001; 22:493–508.
- Gomez A, Bialostozky D, Zajarias A, et al. Right ventricular ischemia in patients with primary pulmonary hypertension. *Am J Coll Cardiol* 2001; 38:1137–1142.
- Fishman A. Pulmonary hypertension and cor pulmonale. In: Fishman A, ed. *Fishman's Pulmonary Diseases and Disorders*. 3rd ed. New York: McGraw Hill, 1998:1261–1296.
- D'Alonzo GE, Barst RJ, Ayres SM, et al. Survival in patients with primary pulmonary artery hypertension: results from a national prospective registry. *Ann Intern Med* 1991; 115:343–349.
- Rich S, ed. Primary pulmonary hypertension: executive summary from the World Symposium on Primary Pulmonary Hypertension. Geneva: World Health Organization, 1998.
- Minai OA, Dweik RA, Arroliga AC. Manifestations of scleroderma pulmonary disease. *Clin Chest Med* 1998; 19:713–731.
- Stupi AM, Steen VD, Owens GR, et al. Pulmonary hypertension in the CREST syndrome variant of systemic sclerosis. *Arth Rheum* 1986; 29:515–524.
- Koh ET, Lee P, Gladman DD. Pulmonary hypertension scleroderma: an analysis of 17 patients. *Br J Rheumatol* 1996; 35:989–993.
- Morelli S, De Marzio P, Valesini G, et al. Pulmonary hypertension in systemic sclerosis. *G Ital Cardiol* 1993; 23:871–876.
- Murata I, Kihara H, Shinohara S, et al. Echo evaluation of pulmonary arterial hypertension in patients with progressive systemic sclerosis and related syndromes. *Jpn Circ J* 1992; 56:983–991.
- Battle RW, Davitt MA, Cooper SM, et al. Prevalence of pulmonary hypertension in limited and diffuse scleroderma. *Chest* 1996; 110:1515–1519.
- Salerni R, Rodnan GP, Leon DF, et al. Pulmonary hypertension in the CREST syndrome variant of progressive systemic sclerosis (scleroderma). *Ann Intern Med* 1977; 86:394–399.
- Yousem SA. The pulmonary pathologic manifestations of the CREST syndrome. *Hum Pathol* 1990; 21:467–474.
- Orens JB, Martinez FJ, Lynch JP III. Pleuropulmonary manifestations of systemic lupus erythematosus. *Rheum Dis Clin North Am* 1994; 20:159–193.
- Asherson RA, Hackett D, Gharavi AE, et al. Pulmonary hypertension in systemic lupus erythematosus (editorial). *J Rheumatol* 1986; 13:1–5.
- Quismorio FP, Sharma O, Koss M, et al. Immunopathologic and clinical studies in pulmonary hypertension associated with systemic lupus erythematosus. *Semin Arth Rheum* 1984; 13:349–359.
- Petitpretz P, Brenot F, Azarian R, et al. Pulmonary hypertension in patients with human immunodeficiency virus infection. Comparison with primary pulmonary hypertension. *Circulation* 1994; 89:2722–2727.
- Mehta NJ, Khan IA, Mehta RN, et al. HIV-related pulmonary hypertension: analytic review of 131 cases. *Chest* 2000; 118:1133–1141.
- Abenham L, Moride Y, Brenot F, et al. International primary pulmonary hypertension study group. Appetite suppressant drugs and the risk of primary pulmonary hypertension. *N Engl J Med* 1996; 335:609–616.
- Chatterjee K, De Marco T, Alpert J. Pulmonary hypertension: hemodynamic diagnosis and management. *Arch Intern Med* 2002; 162:1925–1933.
- Homma A, Anzueto A, Peters JL, et al. Pulmonary artery systolic pressures estimated by echocardiogram vs cardiac catheterization in patients awaiting lung transplantation. *J Heart Lung Transplant* 2001; 20:833–839.
- Berger M, Haimowitz A, van Tosh A, Berdoff RL, Goldberg E. Quantitative assessment of pulmonary hypertension in patients with tricuspid regurgitation using continuous-wave Doppler ultrasound. *J Am Coll Cardiol* 1985; 6:359–365.
- Peacock AJ. Primary pulmonary hypertension. *Thorax* 1999; 54:1107–1118.
- Pruszczyk P, Torbicki A, Pacho R, et al. Noninvasive diagnosis of suspected severe pulmonary thromboembolism: transesophageal echocardiography vs. spiral CT. *Chest* 1997; 112:722–728.
- Smith JW, Clements PJ, Levinsman J, et al. Echocardiographic features of progressive systemic sclerosis (PSS): correlation with hemodynamic and postmortem studies. *Am J Med* 1979; 66:28–33.
- Matthay R, Berger H. Cardiovascular function in cor pulmonale. *Clin Chest Med* 1983; 4:269–295.
- Restrepo CI, Tapsen VE. Pulmonary hypertension and cor pulmonale. In: Topol EJ, ed. *Textbook of Cardiovascular Medicine*. 2nd ed. Philadelphia: Williams & Wilkins, 2002:647–665.
- Young RH, Mark GJ. Pulmonary vascular changes in scleroderma. *Am J Med* 1978; 64:998–1004.
- Viner SM, Bagg BR, Auger WR, et al. The management of pulmonary hypertension secondary to chronic thromboembolic disease. *Prog Cardiovasc Dis* 1994; 37:79–92.

31. Shure D, Gregoratos G, Moser KM. Fiberoptic angioscopy: role in the diagnosis of chronic pulmonary arterial obstruction. *Ann Intern Med* 1985; 103:844–850.
32. Uchida Y, Oshima T, Hirose J, et al. Angioscopic detection of residual pulmonary thrombi in the differential diagnosis of pulmonary embolism. *Am Heart J* 1995; 130:854–859.
33. Stahr P, Rupprecht HJ, Voigtlander T, et al. Comparison of normal and diseased pulmonary artery morphology by intravascular ultrasound and histological examination. *Int J Card Imaging* 1999; 15:221–31.
34. Bressollette E, Dupuis J, Bonan R, et al. Intravascular ultrasound assessment of pulmonary vascular disease in patients with pulmonary hypertension. *Chest* 2001; 120:809–815.
35. Tan RT, Kuzo R, Goodman L. Utility of CT scan for predicting pulmonary hypertension in patients with parenchymal lung disease. *Chest* 1998; 113:1250–1256.
36. Sherrick AD, Swensen SJ, Hartman TE. Mosaic pattern of lung attenuation of CT scans: frequency among patients with pulmonary artery hypertension of different causes. *Am J Roentgenol* 1997; 169:79–82.
37. Cailes JB, du Bois RM, Hansell DM. Density gradient of the lung parenchyma on computed tomography scanning in patients with pulmonary hypertension and systemic sclerosis. *Acad Radiol* 1996; 3:724–730.
38. Frank H, Globits S, Glogar D, et al. Detection and quantification of pulmonary artery hypertension with MR imaging: results in 23 patients. *Am J Roentgenol* 1993; 161:27–31.
39. Kruger S, Haage P, Hoffman R, et al. Diagnosis of pulmonary arterial hypertension and pulmonary embolism with magnetic resonance angiography. *Chest* 2001; 120:1556–1561.
40. Steen VD, Graham G, Conte C, et al. Isolated diffusing capacity reduction in systemic sclerosis. *Arth Rheum* 1992; 35:765–770.
41. Kuo PC, Plotkin JS, Johnson LB, et al. Distinctive clinical features of portopulmonary hypertension. *Chest* 1997; 112:980–986.
42. McLaughlin VV, Genthner DE, Panella MM, Rich S. Reduction in pulmonary vascular resistance with long-term epoprostenol (prostacyclin) therapy in primary pulmonary hypertension. *N Engl J Med* 1998; 338:273–277.
43. Paciocco G, Martinez FJ, Bossone E, et al. Oxygen desaturation on the six-minute walk test and mortality in untreated primary pulmonary hypertension. *Eur Respir J* 2001; 17:647–652.
44. Miyamoto S, Nagaya N, Satoh T, et al. Clinical correlates and prognostic significance of six-minute walk test in patients with primary pulmonary hypertension. Comparison with cardiopulmonary exercise testing. *Am J Respir Crit Care Med* 2000; 161:487–492.
45. Venkateshiah SB, Arroliga AC, Mehta AC, et al. Safety of surgery in patients with pulmonary artery hypertension [abstract]. *Am J Respir Crit Care Med* 2002; 165:B53.
46. Khan MG. Pulmonary hypertension and cor pulmonale. In: Khan MG, Lynch JP III, eds. *Pulmonary Disease Diagnosis and Therapy: A Practical Approach*. Baltimore: Williams & Wilkins, 1997:603–616.
47. Chemla D, Castelain V, Herve P, et al. Haemodynamic evaluation of pulmonary hypertension. *Eur Respir J* 2002; 20:1314–1331.
48. Humber M, Trembath RC. Genetics of pulmonary hypertension: from bench to bedside. *Eur Respir J* 2002; 20:741–749.
49. Newman J. Treatment of primary pulmonary hypertension—the next generation. *N Engl J Med* 2002; 346:933–935.
50. Thomas AQ, Gaddipati R, Newman JH, et al. Genetics of primary pulmonary hypertension. *Clin Chest Med* 2001; 22:477–491.
51. Yamane K, Ihn Y, Asano N, et al. Clinical and laboratory features of scleroderma patients with pulmonary hypertension. *Rheumatology* 2000; 39:1269–1271.
52. MacGregor AJ, Canavan C, Knight CP, et al. Pulmonary hypertension in systemic sclerosis: risk factors for progression and consequences for survival. *Rheumatology* 2001; 40:453–459.
53. Launay D, Hachulla E, Hartron PY, et al. Pulmonary hypertension screening in systemic sclerosis: a cohort study of 67 patients. *Rev Med Interne* 2001; 22:819–829.
54. Fagan KA, Budesch DB. Pulmonary hypertension associated with connective tissue disease. *Prog Cardiovasc Dis* 2002; 45:225–234.
55. Castro M, Krowka MJ, Schroeder DR, et al. Frequency and clinical implications of increased pulmonary artery pressures in liver transplantation. *Mayo Clin Proc* 1996; 71:543–551.
56. Kim WR, Krowka MJ, Plevak DJ, et al. Accuracy of Doppler echocardiography in the assessment of pulmonary hypertension in liver transplant candidates. *Liver Transplant* 2000; 6:453–458.
57. Cotton CL, Gandhi S, Vaitkus PT, et al. Role of echocardiography in detecting portopulmonary hypertension in liver transplant candidates. *Liver Transplant* 2002; 8:1051–1054.
58. Le Houssine P, Karmochkine M, Ledru E. Primary pulmonary hypertension in human immunodeficiency virus infection. Study of 9 cases and review of the literature. *Rev Med Interne* 2001; 22:1196–1203.
59. Petrosillo N, Pellicelli AM, Boumis E, Ippolito G. Clinical manifestation of HIV-related pulmonary hypertension. *Ann NY Acad Sci* 2001; 946:223–235.
60. Seoane L, Shellito J, Welsh D, et al. Pulmonary hypertension associated with HIV infection. *South Med J* 2001; 94:635–639.
61. Tomashefsk JF, Hirsch CS. The pulmonary vascular lesions of intravenous drug abuse. *Hum Pathol* 1980; 11:133–145.
62. Nakchbandi IA, Wirth JA, Inzucchi SE. Pulmonary hypertension caused by Grave's thyrotoxicosis: normal pulmonary hemodynamics restored by (131)I treatment. *Chest* 1999; 116:1483–1485.
63. Arroliga AC, Dweik RA, Rafanan AL. Primary pulmonary hypertension and thyroid disease. *Chest* 2000; 118:1224–1225.
64. Sanner BM, Doberauer C, Konermann M, et al. Pulmonary hypertension in patients with obstructive sleep apnea syndrome. *Arch Intern Med* 1997; 157:2483–2487.
65. Phillips BG, Norkiewk K, Perck CA, et al. Effect of obstructive sleep apnea on endothelin-1 and blood pressure. *J Hypertens* 1999; 61–66.
66. Krowka MJ. Pulmonary hypertension: diagnostics and therapeutics. *Mayo Clin Proc* 2000; 75:625–630.
67. Yamakawa H, Shiomi T, Sasanabe R, et al. Pulmonary hypertension in patients with severe obstructive sleep apnea. *Psychiatry Clin Neurosci* 2002; 56:311–312.
68. Haque AK, Gokhale S, Rampy BA. Pulmonary hypertension in sickle cell hemoglobinopathy. A clinicopathologic study of 20 cases. *Hum Pathol* 2002; 33:1037–1043.