

DIAGNOSIS AND TREATMENT OF CARDIOSPASM

PAUL M. MOORE, JR., M.D.

The condition known as cardiospasm has been attributed to many causes and many names have been offered by the proponents of the various theories to take its place. But the name cardiospasm has remained the one that has been the most frequently used, partially because the various theories advanced were not altogether convincing, and partially because the names suggested were too cumbersome. The most recent term, achalasia of the cardia, sponsored by Arthur F. Hurst¹ is being used more and more in the English literature and is appearing more frequently now in America. The term is short and easily used and the theory behind it has considerable merit.

The earliest case was reported by Thomas Willis² in *Pharmaceutice rationalis* in 1672. He made a dilator of whalebone surmounted by a button of sponge which the patient used on himself for fifteen years. The early literature classifies these cases as Idiopathic Dilatation of the Esophagus.

An excellent and complete review of the literature has been made by Sturtevant³ and the earlier theories have been well covered by Freeman⁴ so I will make only brief reference to some of the better known theories.

Cardiospasm. This is one of the earliest theories and has been the most popular. It was sponsored by Kraus, Meltzer and Mikulicz. It would account for the obstruction to the passage of food into the stomach and for the beneficial effects of belladonna and atropine. It does not explain the marked dilation of the esophagus in the later stages. Such dilation is not seen in obstruction due to other causes, such as scar tissue stenosis, even after it has been present many years. Opponents of this theory point out that there is no definite anatomic sphincter muscle at the cardia. Recently, Lendrum⁵ came to this conclusion after studying 150 human specimens. On the other hand, Knight⁶ has demonstrated a physiologic intrinsic sphincter at the cardia in cats which contracts on sympathetic stimulation and relaxes on vagal stimulation.

Phrenospasm. This has been advanced by Jackson⁷ who tries to explain the condition on the basis of a spasm of the diaphragm which acts as a pinch cock on the lower end of the esophagus. Although he has supplied an anatomic sphincter in this theory, it still does not explain the marked dilatation of the esophagus in later cases. Then, too, the obstruction to the passage of food is sometimes below the diaphragm.

Fibrosis of the terminal portion of the esophagus. This is the most recent theory of Mosher⁸. He feels that there is a tubular narrowing of the terminal portion of the esophagus in the crural canal and crural ring due to a fibrosis of the periesophageal connective tissue and of the

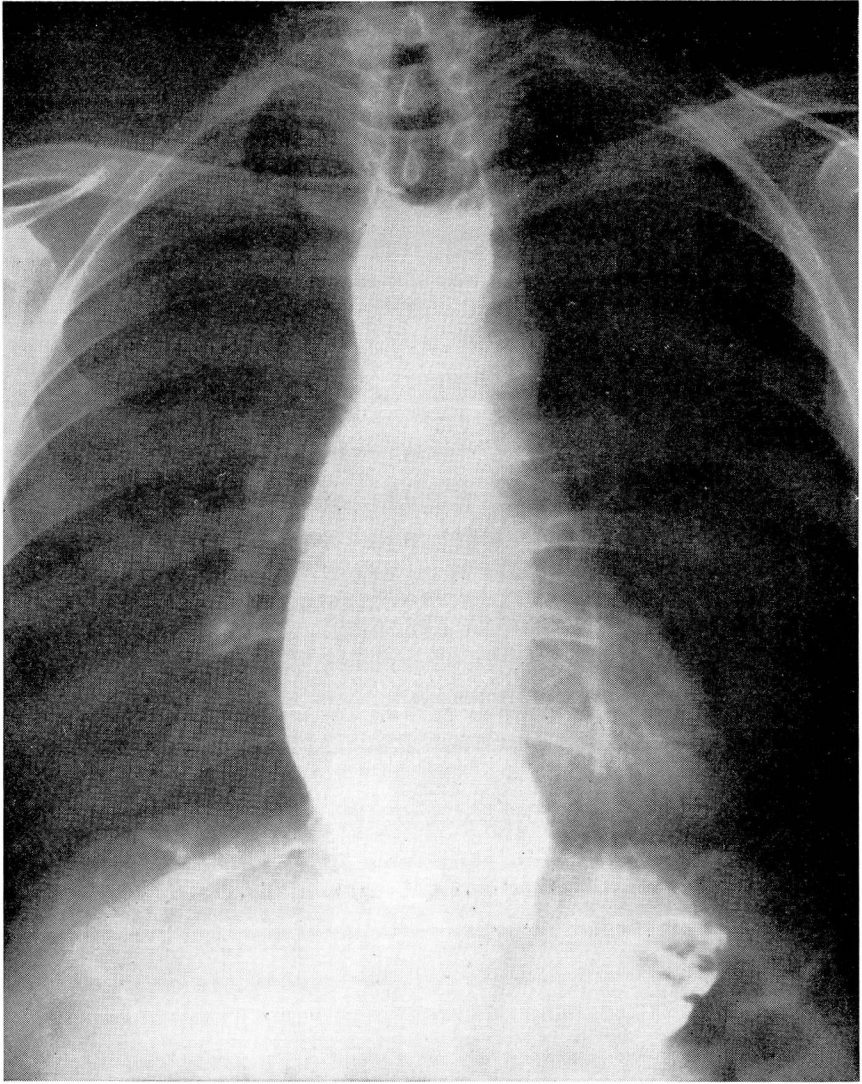


FIGURE 1. Typical roentgenogram illustrating cardiospasm.

muscles of the esophagus. He believes this is brought about by infection of the coats of the esophagus. The fibrosis of Auerbach's plexus reported by Hurst¹, Rake⁹ and others is interpreted as being of secondary rather than primary importance. He reports three cases which he has studied from the standpoint of involvement of the plexus. One case of five years' duration showed no involvement of the plexus. One long-standing case showed some involvement and a man of seventy showed marked involvement of the plexus.

DIAGNOSIS AND TREATMENT OF CARDIOSPASM

Achalasia of the cardia. This term was introduced by Hurst⁹ in 1915 and has been gaining in popularity ever since. He and Rake are the principal champions of the theory that the condition is due to a failure of the cardia to relax and open during the act of swallowing rather than due to a spasm. They found that this theory had first been suggested by Einhorn¹⁰ in 1888 and again by Rolleston¹¹ in 1896. According to this theory, the cardia is normally closed when at rest and opens as a result of a peristaltic wave passing down the esophagus. Normally a bolus of food is swallowed, the peristaltic wave passes down the esophagus to the cardia where there is a momentary pause, then the cardia opens and the bolus passes into the stomach. In achalasia, the cardia fails to relax and the food remains in the esophagus. This, they feel, is due to a neuromuscular dysfunction resulting from pathologic changes in the vagi and more particularly in Auerbach's plexus. Hurst, Rake and more recently Lendrum⁵ have reported numerous cases in whom careful postmortem examination has revealed a striking loss or complete absence of the ganglion cells in the myenteric (Auerbach's) plexus. Freeman⁴ and Mosher⁸ report one case each that showed no involvement of this plexus. The clinical and roentgen picture has been produced in rabbits¹² and in cats⁶ by section of the vagus nerves. Symptomatic relief was produced by subsequently sectioning the sympathetic. On the basis of these experimental investigations, a number of reports have been made of resection of the sympathetic supply to the cardiac sphincter in the treatment of this condition^{12, 13}.

That there are psychogenic features in most cases of cardiospasm cannot be denied, but whether they are of etiologic significance or are by-products of the condition is another question. Winkelstein¹⁴ feels that a certain number of cases are on a psychogenic basis and can be helped by psychotherapy. Most of these cases are extremely nervous, and sudden nervous tension or strain does make them worse but it seems to me that the condition itself is enough to produce nervousness. The psychogenic factor could hardly enter into the cases which have been reported as occurring in the newborn by Segar and Stoeffler¹⁵, Aikman¹⁶, and Bogert¹⁷.

Although cardiospasm is most frequently found in young adulthood, it has been reported as occurring from the first day of life to old age. The symptomatology varies with the severity of the condition and the length of time it has existed. In the newborn it may cause vomiting during or immediately after the first feeding. There is no gastric juice in the vomitus. A barium esophagram shows the typical picture of obstruction at the cardia with dilation of the esophagus above.

Usually the patient with cardiospasm does not consult the physician for some years after its onset. At first there is the sensation of food

sticking momentarily in the lower end of the esophagus. This is intermittent at first. As the condition becomes more established and more frequent, there often develops a pain or feeling of pressure which is substernal or in the epigastrium. This pain is increased by taking food and may become very severe and may radiate through to the back. Regurgitation is a very common symptom and the regurgitated food has an alkaline reaction and may show some putrification but no digestion. As the esophagus becomes more and more dilated, a shortness of breath develops on exertion or on lying down. The closed cardia will support a column of water eight inches high and as much as 2000 cc. of fluid content has been aspirated from one dilated esophagus. As a result, the patient has much difficulty resting at night both because of the pressure of the overloaded esophagus and because the liquid contents often leak out and spill into the larynx, bringing on severe paroxysms of nocturnal coughing. Most of the patients discover that they can attain some small degree of comfort by voluntarily regurgitating as much as possible. They also find that in the earlier stages they can aid the passage of food into the stomach by taking a sip of hot water or sometimes by taking a deep breath or twisting the body one way or another. Because of the esophageal irritation, there may be increased salivation which may be very annoying to the patient. In extreme longstanding cases there is loss of weight and strength, and anemia.

The *diagnosis* is made by esophagram and esophagoscopy. The roentgen picture is typical but esophagoscopy should always be done, for the cardiospasm may be secondary to a peptic ulcer of the esophagus or an early malignancy. On esophagoscopy, the dilated esophagus is always partly filled with a frothy liquid content which may contain partly decayed bits of food. The mucosa is a gray or mottled red and may be ulcerated. There is always an esophagitis. Carcinoma has been known to develop²⁰. The Jackson dilators meet with only a little resistance as they are passed into the stomach.

The *treatment* must consist of a definite program which the patient must adhere to in order to obtain the best results. Every one of these cases can be very definitely helped. Complete permanent cure is questionable. In the newborn the passage of a small catheter through the nose and esophagus into the stomach where it is allowed to remain for one or two days for feedings is usually enough. This may be repeated if necessary.

The patient is put on a diet of bland liquids and soft food. He is warned against eating any highly seasoned food and especially against foods with seeds or pits that would be irritating. As his condition improves he can add more solid foods to his list.

In spite of the frequency with which the published papers insist that

DIAGNOSIS AND TREATMENT OF CARDIOSPASM

antispasmodics are disappointing, I still prescribe them. I use them because I have seen patients make better progress when they were used than when they were left out of the plan. They can be given as tincture belladonna, XV drops, t.i.d.a.c.

A mild sedative is also very desirable. I give phenobarbital gr. $\frac{1}{4}$ t.i.d.a.c. One can combine the antispasmodic and sedative in the following prescription:

Sod. Bromide	3 IV
Tr. belladonna	3 IV
Tr. hyoscyamus	3 IV
Simple elixir q.s. ad.	3 IV
Sig.; 1 tsp. t.i.d. one hour before meals.	

In addition to the above measures the cardia is dilated mechanically at intervals, depending on the severity and the reaction of the patient. I like to give a dilation about once a week and then lengthen the intervals as the patient improves. Many dilators have been designed and are in use today. I prefer the mercury filled bougies and start with the number 28. This is done one-half hour after giving the patient $1\frac{1}{2}$ gr. nembutal and anesthetizing the throat with a spray of 2 per cent cocaine. If the patient tolerates the procedure well, I pass the next size, the number 30. Each dilator is left in place about five minutes if possible. As the patient becomes more used to the procedure, two can be passed each time. When the largest size, the number 34 is reached, I like to have them swallow the Mosher bag and pump it up to four pounds for five minutes. This produces a larger amount of stretching than is possible with the non-expanding type of dilator but it is extremely difficult for some people to swallow. The periods between dilations can be lengthened from time to time. After the largest dilation is reached, the patient is instructed to return when he feels the need of another dilation.

Bruenner¹⁸ advocates treatment with the high frequency current in conjunction with the dilation. She uses the dilator as one electrode and the other electrode is attached to one disc on the front and one disc on the back of the patient.

Very severe cases with marked esophagitis may run a septic temperature following any manipulation. These should be handled as advised by Canfield¹⁹. He does a gastrostomy and then irrigates the esophagus with 1,000 cc. hot physiologic saline solution one to three times a day. Temporary gastrostomy is at times very helpful in controlling a far advanced case. Many other operative procedures have been done but it is not within the scope of this paper to discuss them. Thus far it would seem that they apply to only a very few of these cases unless the recently devised sympathectomy proves to give a permanent cure.

REFERENCES

1. Hurst, A. F.: Some disorders of esophagus, J.A.M.A., 102:582-587, (February 24) 1934.
2. Willis, Thomas: Cited by Hurst, op. cit. 1.
3. Sturtevant, M.: Cardiospasm, with a review of the literature, Arch. Int. Med., 51:714-736, (May) 1933.
4. Freeman, E. B.: Chronic cardiospasm; Report of fatal case with pathological findings, South. M. J., 26:71-76, (January) 1933.
5. Lendrum, F. C.: Anatomic features of cardiac orifice of stomach, with special reference to cardiospasm, Arch. Int. Med., 59:474-511, (March) 1937.
6. Knight, G. C.: Relation of extrinsic nerves to functional activity of esophagus, Brit. J. Surg., 22:155-168, (July) 1934.
7. Jackson, C.: Peroral Endoscopy and Laryngeal Surgery, p. 511, St. Louis, Mo., The Laryngoscope Company, 1915.
8. Mosher, H. P.: Fibrositis of terminal portion of esophagus: Cardiospasm. Proc. Internat. Assembly Inter-State Post-Graduate M. A. North America (1930), 6:95-104, 1931.
9. Hurst, A. F. and Rake, G. W.: Achalasia of cardia, Quart. J. Med., 23:491-508, (July) 1930.
10. Einhorn, M.: A case of dysphagia with dilatation of the esophagus, Med. Rec. N. Y., 34:751, 1888.
11. Rolleston, H. D.: Simple dilation of the esophagus, Tr. Path. Soc. London, 1896, lxvii, 37 and 1899, i, 69.
12. Knight, G. C. and Adamson, W. A. D.: Achalasia of the cardia, Proc. Roy. Soc. Med., 28:891-897, (May) 1935.
13. Eliason, E. L. and Erb, W. H.: Cardiospasm; Report of two cases treated by resection of sympathetic supply to cardiac sphincter, Am. J. Surg., 35:105-112, (January) 1937.
14. Winkelstein, A.: Psychogenic factors in cardiospasm, Am. J. Surg., 12:135-138, (April) 1931.
15. Segar, L. H. and Stoeffler, W.: Cardiospasm in newborn, Am. J. Dis. Child., 39:354-358, (February) 1930.
16. Aikman, J.: Cardiospasm and other obstructions of upper gastro-intestinal tract in new born, New York State J. Med., 33:865-873, (July 15) 1933.
17. Bogert, F. van der: "Cardiospasm" in the new born, Arch. Pediat., 50:585-588, (August) 1933.
18. Bruenner, M.: Treatment of cardiospasm with high frequency current, M. Rec., 149: 371-373, (June 7) 1939.
19. Canfield, M.: Cardiospasm: Methods of procedure in presence of serious esophagitis, New England J. Med., 271:702-704, (October 28) 1937.
20. Rake, Geoffrey: Epithelioma of the esophagus in association with achalasia of the cardia, Lancet., 2:682, (September 26) 1931.