

A practical guide for examining and treating the diabetic foot

ALLAN M. BOIKE, DPM

Department of Orthopaedic Surgery, The Cleveland Clinic

JAMES O. HALL, DPM

Department of Orthopaedic Surgery, The Cleveland Clinic

■ ABSTRACT

Physicians can perform a quick, complete examination of the feet of patients with diabetes to prevent serious complications. The examination should focus on circulation, nerve function, musculoskeletal problems, and the skin. All patients should be urged to wear supportive, comfortable shoes, and to wash, moisturize, and examine their feet every day.

IT ISN'T JUST PODIATRISTS who should be examining the feet of patients with diabetes. Internists and other specialists can help their diabetic patients avoid serious complications by regularly checking their feet and by reinforcing the principles of foot self-care (see patient information page, **Taking care of your feet**, page 349).

This article gives some tips on performing a quick, focused examination of the diabetic foot for circulatory, nerve function, skin, and musculoskeletal problems. It also includes how to treat ulcerations, infections, and Charcot arthropathy.

■ DIABETES AND THE FOOT

Regular foot examinations are essential for all diabetic patients because the circulatory and neuropathic sequelae of diabetes can turn

minor breakdowns into severe ulcerations that lead to amputation. About 15% of all people with diabetes will develop an ulceration, and about half of all amputations start with an ulceration.

The foot is often the first part of the body to show the adverse effects of diabetic neuropathy and circulatory problems. Most lower-extremity ulcerations in diabetes are due to neuropathy, with the remainder attributable to circulatory impairment. Impaired kidney function can worsen the problem by causing increased neuropathy and swelling in the lower extremities. In addition, diabetic neuropathy may lead to Charcot arthropathy, a degenerative joint disease.

The complete examination of the diabetic foot should include assessments of circulatory function, neuropathy, musculoskeletal function, and skin integrity.

■ CIRCULATORY PROBLEMS

Examination

Pulses. Start every examination by palpating the dorsalis pedis and posterior tibial pulses. If these pulses are present, then there is no need to check the more proximal circulation, but if they are absent, then move to the popliteal and femoral areas to find out exactly where there is flow.

Skin temperature indicates perfusion to the skin, and any elevation or decrease in surface temperature suggests a problem. Check skin temperature by running the back of your hand down the leg from the tibial tubercle and along the foot to the dorsum of the digits. Hot spots are particularly important in detecting Charcot arthropathy, because in this condition, one foot may be warmer than the other.

Visually inspect the skin. Absence of

Help your
diabetic
patients by
checking their
feet regularly

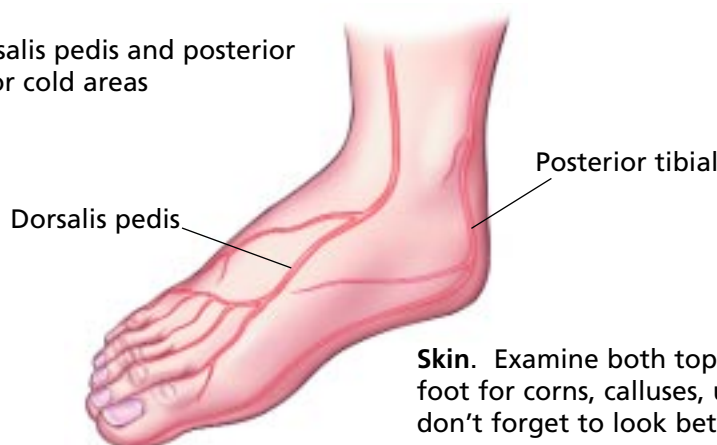


PATIENT INFORMATION

Taking care of your feet, page 349

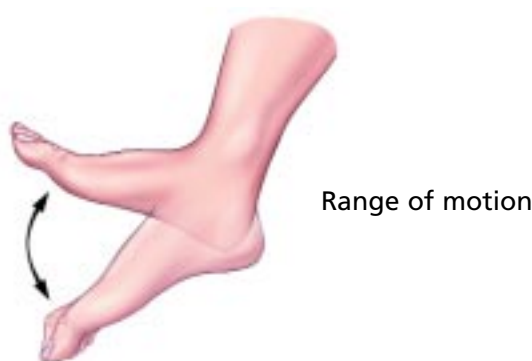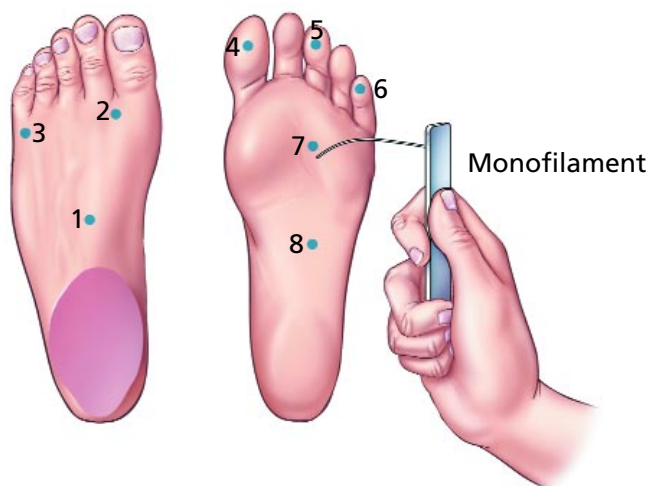
■ Examining the diabetic foot

Circulation. Palpate the dorsalis pedis and posterior tibial pulses; check for hot or cold areas



Skin. Examine both top and bottom of the foot for corns, calluses, ulcers, infection—don't forget to look between the toes

Neuropathy. Check protective sensation with a Semmes-Weinstein monofilament; test vibratory sensation with a tuning fork over bony prominences; test pain with pinpricks; test proprioception by passive movement of the toes with patient's eyes closed



Musculoskeletal. Check strength, range of motion; look for deformities

CCF
©2002

FIGURE 1

hair or a decrease in hair growth, nail changes, and atrophic, dry, cracked skin suggest neurotrophic and autonomic changes. Skin inelasticity or tenting can be signs of lack of circulation and perhaps of dehydration.

Signs of decreased circulation should be noted in the chart and followed up with one or more specialized tests.

- Pulse volume recordings indicate where

blockages may be and provide quantitative records of circulation decreases.

- Ultrasound and MRI can localize blockages and help in planning any invasive procedures to revascularize limbs.
- Transcutaneous oxygen measurement can predict healing potential for patients with marginal circulation. However, this test is fairly difficult to perform because the ambient

temperature must be controlled carefully.

- Arteriography, the gold standard, can be used to locate blockages and patent vessels distal to the blockages in preparation for surgical bypass operations.

Managing circulatory problems

The goal of management is to preserve existing circulation. The key component is good glycemic control. Exercise is very helpful for maintaining circulation. We put patients with marginal circulation on walking programs so as to develop collateral circulation. Patients should also be urged to avoid constricting garments and shoes and to quit smoking.

■ DIABETIC NEUROPATHY IN THE FOOT

Neuropathy is the leading cause of diabetic lower-extremity ulcerations. The mechanism is not clear, but it may be hypoxic/metabolic.

Diabetic neuropathy affects sensory, motor, and autonomic nervous function, but sensation is often affected first. Neuropathic changes are often first found in the feet, then they progress in a proximal direction.

Examination

The neuropathy examination should assess four sensations: protective sensation, vibratory sensation, pain, and proprioception.

Testing protective sensation. If you do only one neurologic test, I would suggest the Semmes-Weinstein monofilament test. Touch the monofilament to the sole of the foot, press gently until it bends, and ask the patient to report any feeling. The test should be repeated on eight specific areas on the foot, which can provide standardized comparisons between feet and among patients.

Lack of sensation is the most significant finding; in some cases the monofilament test may detect painful neuropathy as well.

Test vibratory sensation by placing a vibrating tuning fork (128 Hz) against a bony prominence and asking the patient whether he or she feels it, and when he or she feels it stop vibrating. Many patients feel the initial vibration but say that it stops immediately, when in fact it continues to vibrate. It may be helpful to do a “test run” on a malleolus or a hand so that the patient knows what the tun-

ing fork feels like before moving to the metatarsal and interphalangeal joints.

For research projects, the more expensive biothesiometer can provide quantitative measurements of sensation thresholds.

Assessing pain sensation. Gentle pricks with a safety pin can assess the patient's ability to feel sharp and dull sensations. Start distally and move proximally. The absence of sharp or dull sensation is extremely dangerous because it means that patients cannot feel breaks in the skin or foreign objects. We have many anecdotal stories of people continuing to walk around with hairpins or children's toys in their shoes because they cannot feel them.

Assessing proprioception. Elderly patients are particularly prone to losing their sense of body position, or proprioception, which affects their gait and stability and is a leading cause of falls. Proprioception in the feet can be assessed by asking the patient to close his or her eyes, moving the patient's toe, and asking whether the movement was upwards or downwards.

Managing diabetic neuropathy

Neuropathy is not reversible. Thus, it is particularly important for patients with newly diagnosed neuropathy to prevent progression by keeping their blood sugar under control.

All patients should inspect their feet every day. A loved one or family member may have to help if the patient has impaired eyesight or mobility problems.

Patients should also avoid using heating pads and ice packs and being exposed to extreme temperatures, because they may not feel when temperatures become severe enough to cause tissue damage.

Neuropathic pain can be treated with topical capsaicin, which must be applied three to four times a day and may take 3 to 5 weeks to start providing relief. For neuropathic pain and Charcot neuroarthropathy, tricyclic antidepressants, gabapentin, or injectable bisphosphonates may be effective.

■ MUSCULOSKELETAL PROBLEMS

Examination

The musculoskeletal examination should focus on testing range of motion and muscle strength, identifying osseous abnormalities,

If you do only one neurologic test, do the monofilament

and examining how the patient's shoes accommodate musculoskeletal deformities.

To examine range of motion, move the ankle, the subtalar joint, the metatarsal joints, and the phalangeal joints through their normal ranges of motion, and determine whether there is any pain, restriction to the range of motion, or crepitus. Impaired joint motion or a lack of shock absorption can lead to callus buildup and abnormal pressure points that can result in skin breakdown, ulceration, and infection.

Muscle strength. In a cursory examination, measure the strength of the dorsiflexors, plantar flexors, inverters, and everters. The goal is to determine whether the patient can move the foot up and down through a normal range of motion, and whether the patient can overcome resistance. Weakness, asymmetry, or unilateral pes planus is significant. Atrophy of the intrinsic muscles of the foot is common and harmful because it leads to contracture and lack of joint motion, which can then cause abnormal pressure points. Fixed contractures such as hammertoe or bunion are also associated with muscle weakness.

Osseous abnormalities are dangerous to the diabetic foot because they create pressure points. Common deformities are hammertoe (contracted toes), bunion (hallux valgus), and tailor's bunion (abnormally prominent head of the fifth metatarsal).

Examine the patient's shoes. Shoes may be too tight and may not accommodate deformities. Often, patients fail to realize that their shoes are worn out and no longer provide support, protection, or shock absorption. For patients who have lost pressure sensation, inappropriate shoes are particularly dangerous because the patient does not feel early signs of skin breakdown.

Maintaining musculoskeletal function

Patients should avoid tight shoes, especially high heels. Shoes should accommodate any foot deformities, and custom shoes should be fitted to accommodate deformities. Padding materials can alleviate pain from osseous deformities and reduce skin breakdown. Many of these deformities can be surgically corrected.

To maintain good muscle function,

patients should maintain glycemic control and do light exercise such as walking and stretching. Keeping active helps keep muscles toned, and it also helps with glycemic control. Running, however, should probably be discouraged.

SKIN INTEGRITY

Examination

The dermal examination is extremely important because the skin is the first barrier to infection. If it breaks down, diabetic patients are particularly susceptible to limb-threatening problems. The examination should include a careful inspection of the top and bottom of the foot, between the toes, and the toenails.

Nails should be examined for onychomycosis, ingrown nails, and paronychia. Patients often try to debride their own ingrown nails, which can lead to serious infection.

Toes should be examined thoroughly for tinea pedis, corns, and fissured or cracked skin. Hard corns are most frequent on the top or sides of toes, and soft corns between toes. Chronic tinea, which leads to snow-like skin desquamation, is an early step in the breakdown in the skin barrier to infection. Untreated corns can lead to ulceration.

The metatarsal heads are the most common location for calluses that lead to problems, because the chronic weight-bearing forces cause extra pressure. Many diabetic people are overweight, which puts even more force on the forefoot. These calluses are also dangerous because their location makes them hard for patients to find.

Plantar warts can often be recognized by little black dots, which are capillaries coming right to the surface of the skin and hemorrhaging. In addition, there are no skin lines going through the wart.

Heel problems can be significant, particularly in the winter when people fail to use moisturizers on their feet. The heels become dry, fissures open, and infection sets in. The heel is composed of fat tissue in columns, and infections are difficult to treat. Heel fissures can be quite deep and painful, and they can spread out and crack further with every step.

Ulcerations. The typical neuropathic

Tell diabetic patients to inspect their feet every day

ulceration is a white halo of hyperkeratotic tissue with serosanguinous drainage. A minority of ulcerations arise from circulatory causes. For example, poor circulation may make the feet feel cold, prompting the patient to use heating pads at a high setting that causes burns.

Medical management and prevention of skin problems

Patients must wash and moisturize their feet every day, particularly in the winter. However, they should not moisturize between the toes, which may encourage the growth of tinea pedis through maceration of tissue. Over-the-counter lotions such as Eucerin, Lubriderm, and Vaseline Intensive Care are generally sufficient. Especially in the winter months, creams may be more effective than lotions. For severe xerosis, lactic acid or urea preparations are often effective.

Over-the-counter topical antifungals are effective, but some require application two or three times a day. If the patient is unable to manage repeated applications, a once-a-day prescription topical antifungal such as oxiconazole (Oxistat) or butenafine (Mentax) may be preferable. Oral antifungals such as itraconazole (Sporanox) or terbinafine (Lamisil) should probably be reserved for recalcitrant tinea infections because they occasionally cause drug interactions or side effects, particularly on liver function. These side effects are particularly worrisome for patients taking oral antihyperlipidemic agents, which also have some potential for liver toxicity.

Ingrown nails may require incision and drainage or permanent surgical correction of a deformed nail.

For corns and calluses, it is important to convince the patient to wear comfortable shoes. Corns and calluses should be debrided safely. If a corn arises because of a toe deformity, the deformity may have to be surgically corrected. Orthotics may help heal and prevent calluses.

Plantar warts, which are viral in origin, are difficult to cure and often recur. However, they should probably be treated anyway to prevent callus buildup or skin breakdown. Many treatments are available, from topical medication to surgical excision.

SHOES AND BRACES FOR THE DIABETIC FOOT

For both neurologic and skin problems, it is critical for the patient to wear comfortable shoes that provide protection from pressure. It is particularly important for shoes and orthotic devices to accommodate pressure points and plantar calluses. For patients with established diabetes, Medicare will cover one pair of diabetic shoes per year.

Unfortunately, comfortable shoes are rarely fashionable, and many patients prefer high heels or shoes with pointed toes. It is difficult to convert them from fashion to comfort. Sometimes we try to alarm the patient by saying, "After you have your prosthesis, it won't really matter what kind of shoe you wear!"

For patients with ulcerations or other problems, extra-depth shoes with custom-molded inserts or custom-molded shoes are preferable. Sometimes a simple ankle-foot orthotic is sufficient, but more complex problems may require bracing, such as the Charcot restraint orthotic walker (CROW) or a patellar weight-bearing brace.

NEUROPATHIC ULCERS

Examination

These ulcers are found at pressure points in patients who lack protective sensation. When evaluating the ulcer, document aspects such as the circulatory function, the size of the lesion, and its depth so that progress can be tracked. Deep ulcers that reach bone are associated with osteomyelitis about 90% of the time.

Examine the base of the ulcer. Document the condition of the surrounding skin, including features such as hypertrophy, hyperkeratosis, and infection. Note any drainage (which is usually serous but may also be purulent), erythema, lymphangitis, or ascending cellulitis. Be sure to inspect between the toes, because ulcers there may escape detection.

Treatment

Sharp debridement is often appropriate, and because neuropathic patients feel little pain, it

Shoes should accommodate pressure points and plantar calluses



can often be performed in the office. Topical debriding agents, such as enzymes, can also be used. Occasionally, grafting or excision of the lesion is needed.

The wound must be carefully tended with sterile wet-to-dry dressings. Patients who cannot do their own dressing changes require help from home health nurses. Becaplermin (Regranex) is a recombinant human platelet-derived growth factor that is applied topically. Unfortunately, a single 15-g tube of becaplermin costs about \$300.

The fastest and best way to heal a serious ulceration on the plantar aspect of the foot is to completely take any weight-bearing activity off the foot, sometimes called “off-loading.” This can be accomplished by having the patient use crutches, a walker, or a wheelchair. If the patient is unable or unwilling to do that, we use total-contact casting to redistribute weight across the plantar aspect of the foot. Unfortunately, these are also bulky devices and are not very popular with patients. Off-loading should be used for prevention as well as management.

Bioengineered skin substitutes containing living cells and collagen are now available; two of them are Apligraf and Dermagraft. They can be applied weekly on an outpatient basis. Each application may cost more than \$500, but they are probably cost-effective when compared with the cost of admission for a foot infection.

■ EVALUATING AND TREATING FOOT INFECTIONS

Examination

The choice of antibiotics should be guided by deep cultures. Superficial swab cultures are less useful because the ulcers are highly contaminated, and blood cultures give little information.

The general wound description should be charted, as well as the patient’s vascular status, glycemic control, laboratory results (particularly any pertaining to the infection), complete blood counts, sedimentation rates, and imaging results.

In describing the wound itself, inspect the base of the wound and classify it as granular, fibrotic, or necrotic. Note any edema and ery-

thema around the wound, its color and odor, whether it is fluctuant, and whether there is subcutaneous crepitation or subcutaneous empyema. Note any drainage and whether it is serous or purulent.

Unfortunately, a 1996 study¹ at a large teaching hospital showed that inpatient evaluation of foot infections is generally poor. Of the patients admitted with foot infections, nearly one third were given no pulse evaluations. Almost 60% had no assessment of protective sensation, and 90% had no examination of underlying structures.

Treatment

The first step of treatment is to control glycemia. The wound should be treated with appropriate antibiotics. Incision and drainage may be needed, followed by good wound care. Some patients may be eligible for delayed primary closure. One of the most important steps is careful follow-up to ensure that the wound fully heals and that no new problems develop.

For deep infections, osteomyelitic bone may have to be resected. For patients who have discontinued antibiotics at least a few days before the surgery, culture samples can be taken from the bone.

■ CHARCOT ARTHROPATHY

Examination

Charcot arthropathy, or neuropathic arthropathy, is degeneration of the stress-bearing part of a joint as a complication of a neurologic disorder, but it is frequently misdiagnosed. First described in 1868 in syphilitic patients, it is now characteristic of long-lived diabetic patients, with an incidence of about 2.1% to 2.5% of the diabetic population.

Charcot arthropathy causes a loss of the normal architecture of the foot, with resulting mild to severe foot deformities. The plantar medial arch may be depressed, or the feet may be abducted at angles. These deformities cause new pressure points that lead to ulcerations, eventual infections, and amputations.

Patients may present with a hot, red, swollen extremity. The differential diagnoses include infections, deep vein thrombosis, cellulitis, or underlying osteomyelitis. To rule out infection, examine the whole patient for signs

‘Off-loading’ is the fastest and best way to heal serious plantar ulcers



of infection, such as increased white cell count. An increased sedimentation rate may indicate either infection or the inflammatory process underlying Charcot arthropathy.

Many patients with Charcot arthropathy, but not all, feel no pain or lessened pain because of loss of sensation.

Imaging studies

Sequential bone scans, computed tomography, or magnetic resonance imaging (MRI) may be more helpful than plain film radio-graphs. Sequential bone scanning should start with a technetium triphasic bone scan, followed by a white cell-labeled technetium scan or an indium scan. MRI may be equivocal in these patients because they have bone marrow edema, and it may be difficult to tell whether they have bony involvement. Duplex ultrasound may be used to rule out deep vein thrombosis.

Imaging studies show something that looks like osteoarthritis with a vengeance. Patients may have severe subluxations, dislocations, early subchondral osteopenic framing, excess juxta-articular new bone with mammoth hypertrophic osteophytes. Most frequently involved are the Lisfranc's or tarsometatarsal joint, the midtarsal joint, the first metatarsophalangeal joint, and the ankle joint.

Over time, deformities and amputation may reshape the foot into something like a cube. Such patients have a very difficult time getting fitted for shoes. Also, over time, some patients develop fractures (most often in the heel) from equinus deformities with a tight posterior heel group pulling at the bone. These fractures can pull the posterior aspect of the heel upwards.

Among patients with Charcot arthropathy who have single-limb amputations, more than half undergo a contralateral amputation within 5 years.

Orthotic treatment

The goal of treatment is to ensure a fully plantigrade foot.

Patients with acute arthropathy should be placed in a Jones compression dressing for a week or two to reduce the swelling. If the disorder is caught early, the limb should be immobilized in a non-weight-bearing cast for a minimum of 3 months, and perhaps as long as 6 months.

A total-contact cast can be used for patients with ulcerations associated with Charcot arthropathy. This is a short-legged cast with padding over bony prominences that is left in place for about a week at a time. The cast is removed at the physician's office, and the area is checked. For draining wounds, a window can be made in the cast so that the dressing can be changed daily.

A patellar weight-bearing brace has a double upright bar attached to the heel of the shoe to support some of the patient's weight, alleviating the weight on the plantar aspect of the foot. These braces are unfortunately very heavy and can be difficult to manage for patients who have neuropathic weakness.

For Charcot arthropathy in the quiescent stage, an ankle-foot orthotic and custom-molded shoes can accommodate deformities that have already occurred and help prevent further deformities.

Surgical treatment

After a patient's acute problems are stabilized, surgery may be warranted to remove bony prominences. Sometimes arthrodesis can be performed to stabilize joints. Occasionally, patients do well with a total rear-foot arthrodesis to ensure a plantigrade foot pointed straight ahead.

Unfortunately, amputation is occasionally required, and sometimes tendon-lengthening, particularly lengthening of the Achilles tendon to alleviate pressure.

In diagnosing Charcot arthropathy, duplex ultrasound can rule out deep vein thrombosis

REFERENCES

1. Edelson GW, Armstrong DG, Lavery LA, Caicco G. The acutely infected diabetic foot is not adequately evaluated in an inpatient setting. *Arch Intern Med* 1996; 156:2373-2378.

SUGGESTED READING

Armstrong D, Frykberg R, Giurini J, et al. Diabetic foot disorders: a clinical practice guideline. Brooklandville, MD; American College of Foot and Ankle Surgeons, 2000.

Frykberg R. The high risk foot in diabetes mellitus. New York; Churchill Livingstone, 1991.

Levin ME, O'Neal LW, Bowker JH, editors. The diabetic foot. St. Louis, MO; Mosby Year Book, 1993.

Mandel S, Willis J, editors. Handbook of lower extremity neurology. New York; Churchill Livingstone, 2000.

ADDRESS: Allan M. Boike, DPM, Department of Orthopaedic Surgery, A40, The Cleveland Clinic Foundation, 9500 Euclid Avenue, Cleveland, OH 44195, e-mail boikea@ccf.org.