



The Clinical Picture

A 52-year-old man
with sudden onset of a facial rash

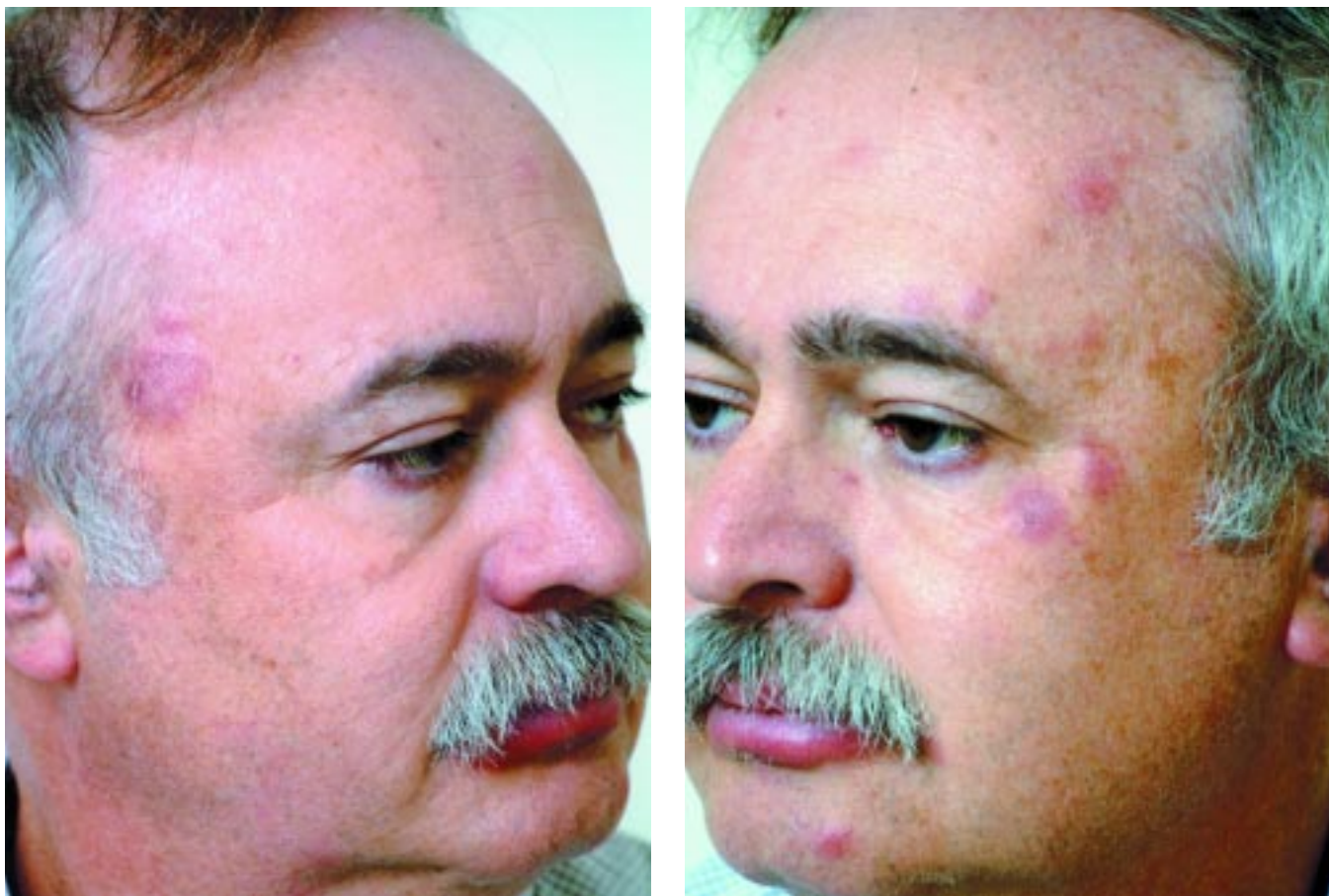

FIGURE 1. The clinical appearance of the multiple facial plaques.

Q: A 52-YEAR-OLD MAN presented to the dermatology clinic with a nonpruritic rash that developed over the past 24 hours. He had no ongoing medical problems and denied taking any medication. He reported having a similar facial eruption 7 months earlier, which had resolved in 2 weeks without treatment. On further questioning, he remembered having taken Aleve (brand of naproxen sodium),

an over-the-counter nonsteroidal anti-inflammatory drug (NSAID), before the onset of the rash. He had taken it to relieve pain after a racquetball match.

He had several discrete and coalescent edematous red plaques on his forehead, cheeks, and chin, and a well-demarcated red edematous plaque on the shaft of the penis. A biopsy of the plaque on the forehead was performed.



Without knowing the biopsy results, what is the likely diagnosis?

- ☐ Insect bites
- ☐ Fixed drug eruption
- ☐ Allergic contact dermatitis
- ☐ Urticaria
- ☐ Discoid lupus erythematosus

A: The history and the morphology of the skin eruption are consistent with a diagnosis of fixed drug eruption, and the results of the skin biopsy, discussed below, help to confirm this diagnosis.

■ FIXED DRUG ERUPTION

Fixed drug eruption is a distinct cutaneous disorder first described by Brocq in 1894.¹ The eruption usually occurs within 1 to 2 weeks of initial exposure to a sensitizing drug. With subsequent exposures, the rash characteristically recurs within a few days at the previously affected sites. In rare instances, rechallenge results in either the development of lesions at new sites or a generalized fixed drug eruption.

Although the exact mechanism remains unknown, the timing of the initial and subsequent reactions suggests that this is a specialized form of delayed hypersensitivity.²

Clinical features

The lesions appear as one or more round, sharply demarcated, erythematous, edematous plaques, some with a central bulla. The lesions may be found on the lips, hands, legs, face, and genitalia, but half of fixed drug eruptions occur on the oral and genital mucosa.³ After the acute inflammatory stage subsides, prolonged or permanent postinflammatory hyperpigmentation may persist.

A thorough drug history

Since the morphology of the lesions in our patient indicated fixed drug eruption, and since he had denied taking any medications, we asked him specifically about taking over-the-counter drugs. This is necessary because patients often do not consider over-the-counter medications as “drugs.”

■ CONFIRMING THE DIAGNOSIS

Biopsy features

Skin biopsy can help confirm the diagnosis of fixed drug eruption. Histologically, the major changes are confined to the epidermis and upper dermis. An important characteristic is hydropic degeneration of the epidermal basal cells, which results in pigmentary incontinence, ie, the presence of melanin-pigmented macrophages within the superficial papillary dermis. An interface dermatitis occurs with the formation of intraepidermal and subepidermal vesicles, necrosis of keratinocytes, and a mixed superficial and deep infiltrate of neutrophils, eosinophils, and mononuclear cells. Marked edema, vascular dilatation, and a perivascular inflammatory cell infiltration consisting of lymphocytes, histiocytes, polymorphonuclear leukocytes, and mast cells is seen in the upper dermis.^{2,3} Immunofluorescent study is not of value in confirming the diagnosis.

Oral rechallenge, topical provocation

Oral rechallenge with the suspected drug can help confirm the diagnosis, but it can lead to an anaphylactic reaction.^{4,5} Topical provocation (patch testing) with the suspected agent may provide a safer means of confirming the diagnosis.^{4,6}

Important technical considerations in patch testing include the choice of vehicle, the drug concentration, the sites of application, and whether an occlusive or open method should be used.^{5,7}

Prostaglandin-inhibiting properties of naproxen may prevent a local inflammatory reaction and produce a falsely negative result. In addition, if the eruption is due to a metabolite of naproxen, this could lead to a falsely negative patch test result.⁸

In our patient, the diagnosis was confirmed based on the typical clinical picture, the biopsy findings, and the patient's history of a similar reaction after taking Aleve.

■ DRUGS THAT CAUSE FIXED DRUG ERUPTION

Both over-the-counter and prescription drugs are known to cause fixed drug eruption. The most common include NSAIDs, barbiturates,

Patients often don't think of OTC agents as 'drugs'




sulfonamides, phenolphthalein, and tetracyclines.^{2,3}

The culprit drug is often taken only intermittently, as in our patient. In this case, the drug was the over-the-counter NSAID Aleve, which is composed primarily of naproxen and which has analgesic, anti-inflammatory, and antipyretic properties.⁹

■ TREATMENT

Most fixed drug eruptions remit when the drug is stopped. Antihistamines can be used to alleviate pruritus. For more rapid relief in severe cases, a short course of oral corticosteroids can be considered.

Our patient had a number of markedly edematous lesions of the face and genitalia. We thus treated him with prednisone 40 mg daily, tapered by 10 mg every 7 days over 1 month, and we advised him to avoid Aleve, as well as any other NSAID that contains naproxen. The skin lesions resolved completely within 10 days. 

■ REFERENCES

1. Brocq L. Eruption erythémato-pigmentée fixe due à l'antipyrine. *Ann Dermatol Vénereol* 1894; 5:308–313.
2. Stern RS, Rear NH. Cutaneous reactions to drugs and biological response markers. In: Arndt KA, editor. *Cutaneous Medicine and Surgery*. Philadelphia: W.B. Saunders, 1996:420–421.
3. Odom RB, James WD, Berger TG. Contact dermatitis and drug eruptions. In: *Andrews' Diseases of the Skin*. 9th edition. Philadelphia: W.B. Saunders, 2000:134–135.
4. Kauppinen K, Stubb S. Fixed eruptions: causative drugs and challenge tests. *Br J Dermatol* 1985; 112:575–578.
5. Alanko K, Stubb S, Reitamo S. Topical provocation of fixed drug eruption. *Br J Dermatol* 1987; 116:561–567.
6. Kauppinen K. Fixed drug eruption and oral rechallenge. *Cleve Clin J Med* 1991; 58:64–65.
7. Alanko K. Topical provocation of fixed drug eruption: a study of 30 patients. *Contact Dermatitis* 1994; 21:25–27.
8. Habbema L, Bruynzeel DP. Fixed drug eruption due to naproxen. *Dermatologica* 1987; 174:184–185.
9. Bigby M, Stern R. Cutaneous reactions to nonsteroidal anti-inflammatory drugs. *J Am Acad Dermatol* 1985; 12:866–876.

ADDRESS: James S. Taylor, MD, Department of Dermatology, A61, The Cleveland Clinic Foundation, 9500 Euclid Avenue, Cleveland, OH 44195; e-mail taylorj@ccf.org.