

The Clinical Picture

A homeless 63-year-old man with an abnormal electrocardiogram

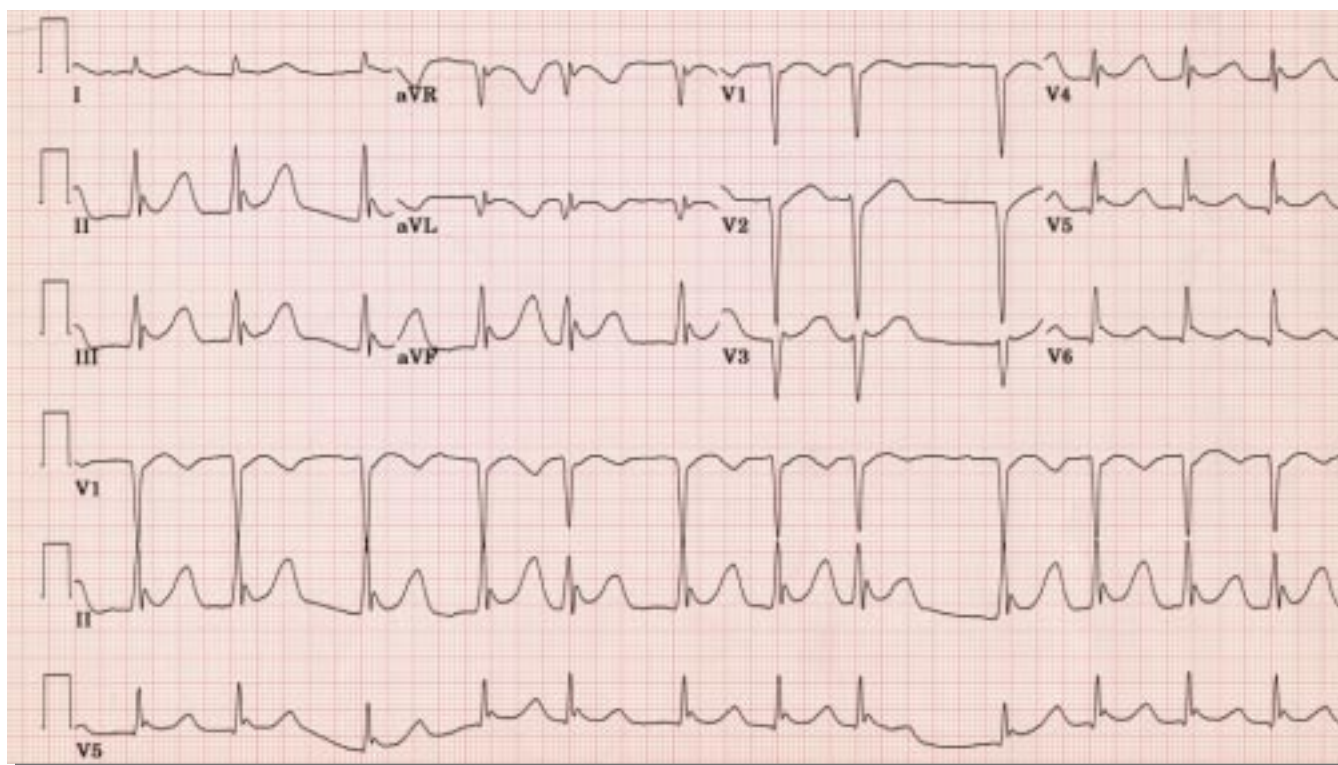


FIGURE 1. The patient's electrocardiogram on admission

Q: POLICE FOUND a 63-year-old homeless man lying in the street. He was unresponsive. They brought him to the emergency department. FIGURE 1 shows the initial 12-lead electrocardiogram (ECG) taken on admission. After intubation and appropriate care in the intensive care unit, another ECG was obtained 8 hours later (FIGURE 2).

What is the most likely diagnosis based on these ECGs?

- ☐ Subarachnoid hemorrhage
- ☐ Acute inferior wall myocardial infarction

- ☐ Hyperkalemia
- ☐ Hypothermia
- ☐ Digitalis toxicity

A: When FIGURE 1 was recorded, the patient was still unresponsive and his temperature—measured electronically via the tympanic membrane—was 28.0°C (82.4°F). FIGURE 2 was taken after he had regained consciousness and his temperature had warmed to 36.0°C (96.8°F). His last memory was of binge drinking outdoors.

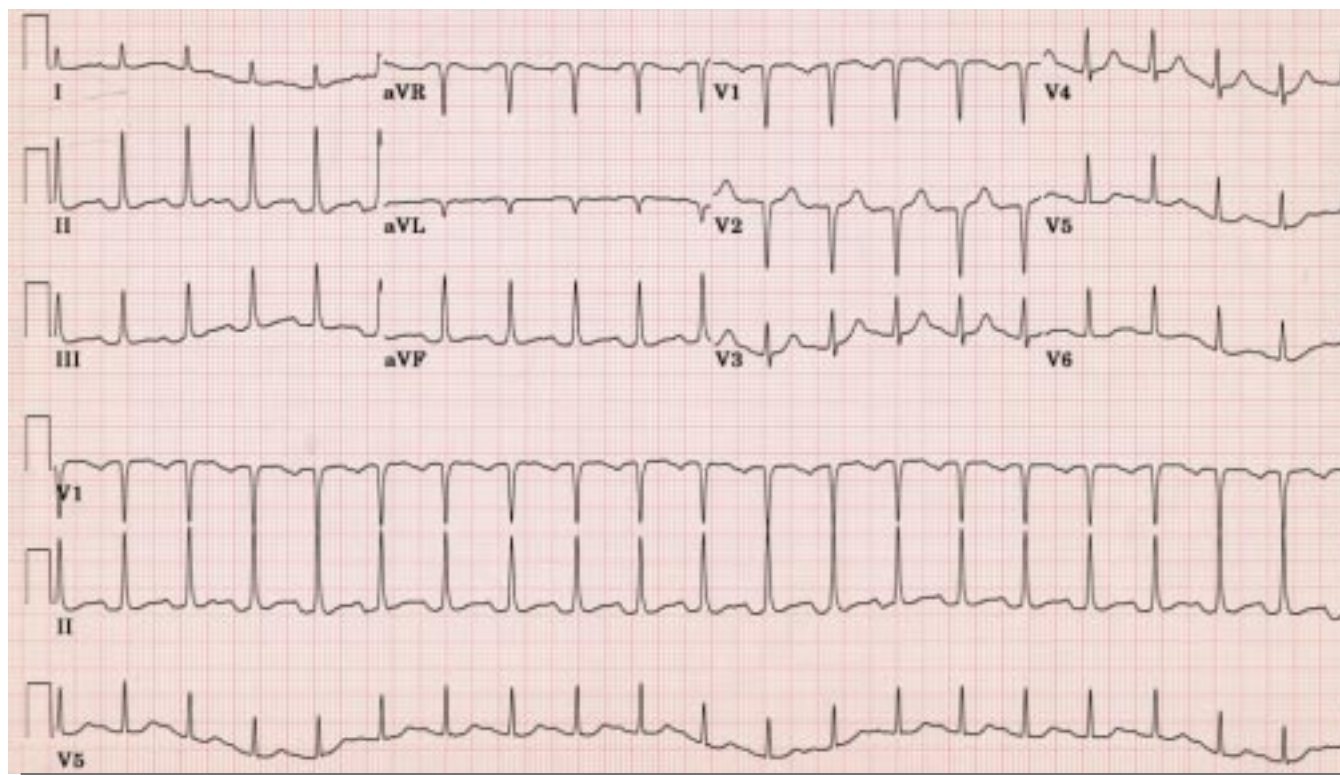


FIGURE 2. The patient's electrocardiogram 8 hours later

■ ECG SIGNS OF HYPOTHERMIA

The most characteristic and recognizable ECG feature of hypothermia is the J wave, also called the Osborn wave, the J deflection, or the camel-hump sign. Eventually seen in about 80% of patients with hypothermia, the J wave first appears at temperatures below 33°C (91.4°F). It is a reasonably specific sign of hypothermia, but it has been reported in normothermic patients and is therefore not pathognomonic.

As shown in **FIGURE 1**, the J wave is the convex positive deflection at the junction of the QRS complex and the early part of the ST segment. (Perhaps a more descriptive term would be the “inverted J wave.”) Although typically most prominent in the inferior limb leads (II, III, aVF) and the lateral precordial leads (V₅, V₆), all leads are involved as hypothermia worsens and the deflection heightens.

Origin of the J wave. Though the cellular basis of the J wave is not yet completely understood, several experts propose the phenomenon to be due to an accentuation of the

“spike-and-dome” morphology of cardiac action potentials of mid-myocardial and epicardial cells. Hypothermia markedly slows conduction velocity and delays depolarization from the endocardium to the epicardium. Coupled with a widening of epicardial cell action potentials, this slowing can unmask a J wave by moving it outside the QRS complex.

Other features

Other ECG features of hypothermia are less specific than the J wave:

- Absent P waves combine with increased atrial ectopic activity to produce atrial fibrillation with slow ventricular response; this occurs (as in **FIGURE 1**) in approximately 60% of patients with a body temperature below 29.0°C (84.2°F)
- PR interval prolongation leads to more severe degrees of atrioventricular block
- Prolongation of the QRS duration and QTc interval reflects the effect of hypothermia on the intraventricular conduction system and the ventricular recovery phase; this electrophysiologic “irritability” worsens progressively below a

The J wave is a reasonably specific sign of hypothermia



temperature of 28.0°C (82.4°F), when ventricular fibrillation becomes a grave concern.

The diagnosis of hypothermia is often obvious before an ECG is obtained. Nevertheless, ECG findings typical of hypothermia may corroborate a high index of suspicion in certain high-risk patient groups, such as elderly, postoperative, hypothyroid, homeless, and alcoholic patients.

■ IMPORTANCE OF MAINTAINING STABLE RHYTHM

Hypothermia typically results in a lethal arrhythmia. Cardiac output progressively declines below 30°C (86°F) owing to depressed cardiac mechanics, including a reduced heart rate. However, if venous return and a stable rhythm compatible with perfusion (sinus bradycardia, atrial fibrillation) are maintained, cardiac output can be sufficient to counter the concordant decrease in oxygen demand. Therefore, maintaining a stable rhythm is essential in the management of hypothermia.

■ THE WRONG ANSWERS

As for the other answers in this quiz:

Subarachnoid hemorrhage. The most characteristic ECG findings in subarachnoid and intracranial bleeding are deeply inverted T waves, prolongation of the QTc interval, and prominent U waves. Rhythm disturbances include sinus bradycardia, sinus tachycardia, wandering atrial pacemaker, AV junctional rhythm, and ventricular tachycardia. J waves with atrial fibrillation are not characteristic.

Acute inferior wall myocardial infarction is marked by ST-segment elevation with

upward convexity in the inferior leads and reciprocal ST-segment depression in “noninfarct” leads.

Hyperkalemia. Atrial fibrillation and J waves are not features of hyperkalemia.

Digitalis toxicity. Although atrial fibrillation with a slow ventricular response can suggest digitalis toxicity, the prolonged QTc interval and J wave in this patient suggest a different diagnosis.

■ CONCLUSION OF THE CASE

Our patient was intubated, passively warmed with external countercurrent heat exchangers, and given ample fluid replacement. After 8 hours, his temperature had risen to 36.0°C and his ECG (FIGURE 2) showed conversion to sinus tachycardia, a normal QTc interval, a normal QRS duration, and no J wave. He was extubated on the following day, recovered fully, and was discharged on his 6th hospital day.

■ SUGGESTED READING

Murray P, Hall J. Hypothermia. In: Principles of critical care. 2nd edition. New York: McGraw-Hill, 1998: 1645–1655.

Osborn JJ. Experimental hypothermia: respiratory and blood pH changes in relation to cardiac function. *Am J Physiol* 1953; 175:389–398.

Patel A, Getsos JP, Moussa G, Damato AN. The Osborn wave of hypothermia in normothermic patients. *Clin Cardiol* 1994; 17:273–276.

Vassallo SU, Delaney DA, Hoffman RS, Slater W, Goldfrank LR. A prospective evaluation of the electrocardiographic manifestations of hypothermia. *Acad Emerg Med* 1999; 6:1121–1126.

Yan G, Antzelevitch C. Cellular basis for the electrocardiographic J-wave. *Circulation* 1996; 93:72–79.

ADDRESS: Raed Bargout, MD, 1348 South Finley Road, Apartment 3D, Lombard, IL 60148.

Hypothermia typically results in a lethal arrhythmia