



# Deep brain stimulation reduces symptoms of Parkinson disease

ERWIN B. MONTGOMERY, JR., MD

Movement Disorders Program, Department of Neurology, Cleveland Clinic

## ■ ABSTRACT

Surgical ablation or continuous electrical stimulation of specific areas deep in the brain may help patients with Parkinson disease or other movement disorders for whom medications have failed or who experience dose-limiting side effects from medications.

**S**URGERY IS ONCE AGAIN a reasonable option for patients with Parkinson disease or other movement disorders when medication does not control symptoms. Although surgery fell out of favor 3 decades ago when levodopa was introduced, recent improvements in our ability to map neural pathways—using micro-electrode recordings of the activity of individual nerve cells—combined with an ability to ablate specific areas of the brain with pinpoint accuracy, are resurrecting the surgical option.

Even more exciting, a new technology that uses electrodes implanted in the brain to provide electrical stimulation is providing an alternative to surgical ablation.

## ■ RATIONALE FOR SURGERY

Deep within the brain, the basal ganglia (or extrapyramidal system) regulate voluntary movement. The system comprises several neural centers, including the substantia nigra pars compacta (FIGURE 1). Normally the system is balanced, with some centers promoting movement and others inhibiting movement. In Parkinson disease, the substantia nigra degenerates, resulting in other areas becoming depleted of dopamine and allowing these

other centers to become overactive and inhibit movement.

Medical therapy with levodopa or dopamine agonists restores the dopamine effect, but often causes unacceptable side effects and often fails in the long term. However, by ablating any of three of the other, nondopaminergic centers, neurosurgeons can reduce not only the symptoms of Parkinson disease, but also the dyskinetic effects of levodopa.

Surgery has reemerged as an option with the development of better imaging techniques, new techniques to map circuits within the brain, and stereotactic surgical techniques. All of these advances assure that the physician can locate the correct target in the brain and precisely reach it during surgery.

## ■ TARGETS FOR ABLATION

In current surgical procedures, one of three specific areas of the brain are ablated, depending on the results desired.

**Thalamus, ventralis intermedius nucleus.** Thalamotomy reduces tremor in approximately 85% of patients, but does not help other parkinsonian symptoms.<sup>1</sup>

**Globus pallidus, medial posteroventral section.** Pallidotomy may be slightly less effective for tremor than is thalamotomy, but helps most other symptoms except gait and balance.

For example, in one series,<sup>2</sup> more than half of patients who were dependent in one or more activities of daily living became independent after undergoing pallidotomy. They also experienced a significant reduction in the total Unified Parkinson Disease Rating Scale score (the standard scoring system—the lower

**Thalamic surgery or stimulation relieves some symptoms but not all**

## ■ How deep brain stimulation improves the symptoms of Parkinson disease

**LIKE A PACEMAKER FOR THE BRAIN**, deep brain stimulation uses a small, implanted battery pack and electrodes to stimulate specific neural centers in the basal ganglia (extrapyramidal system). This therapy can control the symptoms of Parkinson disease by inhibiting neural centers that are overactive as the result of a damaged substantia nigra.

**Electrode** is implanted in one of three target areas:

**Globus pallidus** (shown here), a center that uses gamma-aminobutyric acid (GABA) as a neurotransmitter

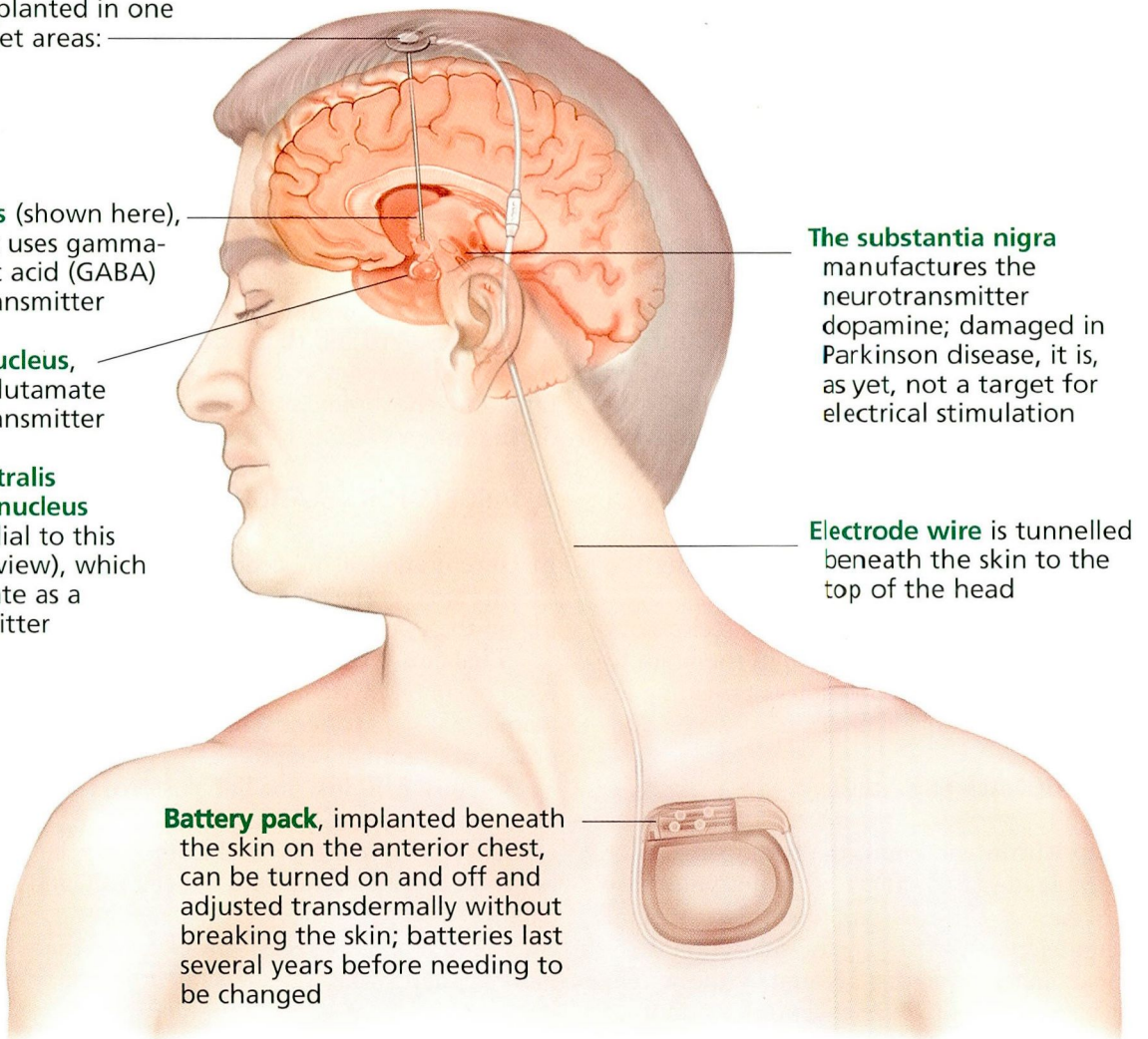
**Subthalamic nucleus**, which uses glutamate as a neurotransmitter

**Thalamus, ventralis intermedius nucleus** (located medial to this parasagittal view), which uses glutamate as a neurotransmitter

**The substantia nigra** manufactures the neurotransmitter dopamine; damaged in Parkinson disease, it is, as yet, not a target for electrical stimulation

**Electrode wire** is tunneled beneath the skin to the top of the head

**Battery pack**, implanted beneath the skin on the anterior chest, can be turned on and off and adjusted transdermally without breaking the skin; batteries last several years before needing to be changed



**FIGURE 1**





the score, the better). This benefit was seen at 1 week after surgery, and sustained for 2 years of follow-up.

As expected, pallidotomy relieves tremor on the contralateral side of the body, since motor fibers cross over in the spinal cord. Somewhat surprisingly, it also reduces tremors somewhat on the ipsilateral side. In addition, it virtually abolishes drug-induced dyskinesias.<sup>2</sup>

The surgery is safe. In the series cited above,<sup>2</sup> fewer than 2% of patients experienced significant morbidity. To date, hundreds of patients have undergone the surgery and not one has died from it.

**Subthalamic nucleus.** Surgery in this area may be less effective for tremor than in the thalamus, but may help with gait and posture.<sup>3</sup>

## ■ DEEP BRAIN STIMULATION

Despite the successes achieved with surgery, the trend in surgery is moving away from destructive techniques and toward the non-destructive—namely, deep brain stimulation (FIGURE 1). In brief, instead of destroying the thalamus, globus pallidus, or subthalamic nucleus, we can block its function by implanting an electrode in it and applying continuous pulses of electrical stimulation via a pacemaker-type device implanted in the anterior chest.<sup>4</sup>

The advantages of deep brain stimulation over surgical ablation are many:

- It avoids purposeful destruction of the brain.
- It causes fewer complications. For example, between 15% and 20% of patients with Parkinson disease also have dementia. Ablative surgical procedures may increase the risk of cognitive impairment, but the newer brain stimulation techniques may not.
- It is adjustable. The electrode has four metal contacts near its tip. The physician can fine-tune the stimuli by choosing any combination of these contacts, and also by varying the strength and frequency of the electrical pulses delivered.

To date, in patients with Parkinson disease, the Food and Drug Administration has approved stimulation of the thalamus only. However, most experts believe that the bene-


fits of stimulating the thalamus are more limited than those of stimulating the globus pallidus or subthalamic nucleus.

## ■ OTHER INDICATIONS FOR DEEP BRAIN STIMULATION

**Essential tremor.** Thalamic stimulation has proven remarkably effective at improving essential tremor.<sup>5</sup> Candidates for the procedure, again, are those who cannot adequately control their symptoms with medication.

**Multiple sclerosis (MS).** Deep brain stimulation does not slow the progression of MS, but can reduce the severity of MS tremors.<sup>6</sup> It is indicated for patients who cannot adequately control symptoms with medication (although there are virtually no medications that help this tremor). In addition, the patient must not have significant weakness or sensory loss in the affected limb, and the MS must be stable for at least 6 months.

The goal of surgery for MS patients is to control the tremor in one arm. Before they are referred for surgery, patients are asked if reduction of tremor in one upper extremity will significantly improve the quality of their lives.

As with Parkinson disease, surgical treatment of MS is safe and effective. However, patients must understand that the surgery does not cure MS, nor change its natural history. 

**The substantia nigra is not a target for stimulation**

## ■ REFERENCES

1. Perry VL, Lenz FA. Ablative therapy for movement disorders: thalamotomy for Parkinson's disease. *Neurosurg Clin North Am* 1998; 9:317–323.
2. Lang AE, Lozano AM, Montgomery E, Duff J, Tasker R, Hutchinson W. Posteroventral medial pallidotomy in advanced Parkinson's disease. *N Engl J Med* 1997; 337:1036–1042.
3. Limousin P, Pollak P, Benazzouz A, et al. Bilateral subthalamic nucleus stimulation for severe Parkinson's disease. *Mov Disord* 1995; 5:672–674.
4. Pahwa R, Wilkinson S, Smith D, Lyons K, Miyawaki E, Koller WC. High-frequency stimulation of the globus pallidus for the treatment of Parkinson's disease. *Neurology* 1997; 49:249–253.
5. Benabid AL, Pollak P, Gao D, et al. Chronic electrical stimulation of the ventralis intermedius nucleus of the thalamus as a treatment of movement disorders. *J Neurosurg* 1996; 84:203–214.
6. Geny C, Nguyen JP, Pollin B, et al. Improvement of severe postural cerebellar tremor in multiple sclerosis by chronic thalamic stimulation. *Mov Disord* 1996; 11:489–494.