


ALEKSANDAR D. POPOVIĆ, MD, PhD, FESC

Dr. Popović is director of the Cardiovascular Research Center at the Dedinje Cardiovascular Institute, Belgrade, Yugoslavia. He has published the largest echocardiographic series analyzing the determinants of left ventricular enlargement following myocardial infarction.

JAMES D. THOMAS, MD

Dr. Thomas is director of cardiovascular imaging and a professor of medicine and biomedical engineering at the Cleveland Clinic. He focuses his clinical work in valvular heart disease and leads a large research group investigating applications of echocardiography in cardiac disease.

Detecting and preventing ventricular remodeling after MI

■ KEY POINTS:

Patients with infarct expansion have a poor prognosis and are more likely to suffer complications such as heart failure, aneurysms, and myocardial rupture.

Thrombolysis in acute myocardial infarction prevents early left ventricular dilatation by attenuating infarct expansion, mainly in anterior infarcts.

The beneficial effect of thrombolysis appears to be partly independent of late vessel patency. Even brief periods of reperfusion in the acute phase, with later reocclusion, may prevent infarct expansion and left ventricular remodeling.

Echocardiography is the technique of choice for routine assessment of left ventricular size and function after myocardial infarction.

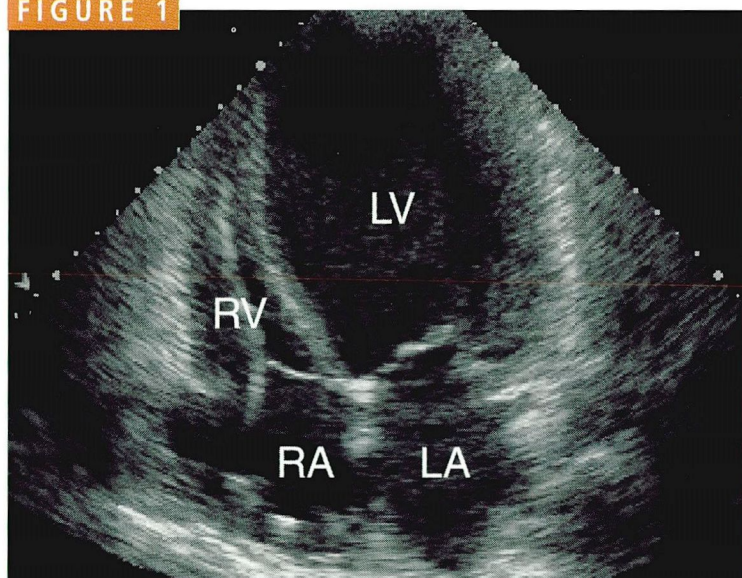
■ **ABSTRACT:** Infarct expansion carries a poor prognosis. Echocardiography can identify this condition by identifying distortion of the ventricular topography. In this review we discuss the acute and long-term effects of thrombolysis on infarct expansion and subsequent left ventricular remodeling after acute myocardial infarction.

During the first hours of an acute myocardial infarction, the left ventricle begins to undergo major architectural changes. If the infarction is extensive enough, the ventricular wall begins to thin and bulge outward in a process that can lead to increased ventricular volume and decreased left ventricular pumping function.

These findings, known as infarct expansion, carry a poor prognosis. Indeed, studies have now shown that infarct expansion is even more accurate as a negative prognostic factor than decreased ejection fraction. Moreover, the test for infarct expansion—echocardiography—is far less expensive and invasive than angiography and hemodynamic measurements. Remarkably, thrombolytic therapy appears to prevent infarct expansion even if follow-up angiograms show that the affected artery remains blocked. In this article, we review acute and long-term effects of thrombolysis on left ventricular size and function after myocardial infarction, and we argue for greater use of echocardiography to detect and assess these changes.

■ EARLY CHANGES: INFARCT EXPANSION

Hutchins and Bulkley¹ defined infarct expansion as acute dilatation and thinning of the infarcted area that cannot be explained by additional necrosis. Histologic studies show that the thinning is probably the result of myocyte elongation, which decreases their number in the

**FIGURE 1**

An echocardiogram (apical four-chamber view) shows remodeling of the left ventricle (LV) in a patient after myocardial infarction. Note the expansion of the left ventricle in relation to the right ventricle (RV), right atrium (RA), and left atrium (LA). (Courtesy of Ellen Mayer Sabik, MD.)

**Anterior
infarcts are
more likely to
lead to
ventricular
dilatation**

infarcted area.^{2,3} The essence of expansion was probably best described by McKay et al,⁴ who considered it a form of intramural myocardial rupture caused by the disruption of myofibrils in the infarcted area.

Patients with infarct expansion are more likely to suffer complications such as heart failure, aneurysms, and myocardial rupture, an extreme form of early expansion in which the infarcted zone is so thin that it cannot maintain the integrity of the ventricular wall.⁵

Infarct expansion occurs most frequently in large transmural infarcts,¹ usually in the anterior apex because this part of the ventricle is the thinnest and has the greatest curvature,⁶ and thinning and decreased curvature lead to relatively stronger deforming forces there than on other left ventricular segments.⁷ Elevated blood pressure increases wall stress and predisposes to infarct expansion. Up to half of anterior infarcts may expand without therapy.

In clinical practice, expansion can be detected by echocardiography, which reveals elongation of the infarcted segment. The electrocardiogram may suggest expansion by persistent ST elevation in the infarct-related

leads, while the chest radiograph shows cardiomegaly.

■ LATER CHANGES: DILATATION, HYPERTROPHY

In the ensuing days and weeks, infarct expansion leads to further changes in left ventricular geometry and function: global left ventricular dilatation (involving both infarcted and normal ventricular segments) and hypertrophy of normal segments. This process, which may last for months, is known as left ventricular remodeling (FIGURE 1).^{4,8}

Theroux et al⁸ showed in experiments in dogs that dilatation is not confined to the infarct zone, but affects normal segments of the ventricle as well. Erlebacher et al⁹ demonstrated that repeated echocardiograms can detect dilatation of normal segments in patients with infarct expansion. McKay et al⁴ found left ventricular dilatation 2 weeks after Q-wave infarctions, associated with decreased end-diastolic pressure compared with the pressure in the acute phase. The degree of left ventricular dilatation directly correlated with the size of akinetic or dyskinetic segments.

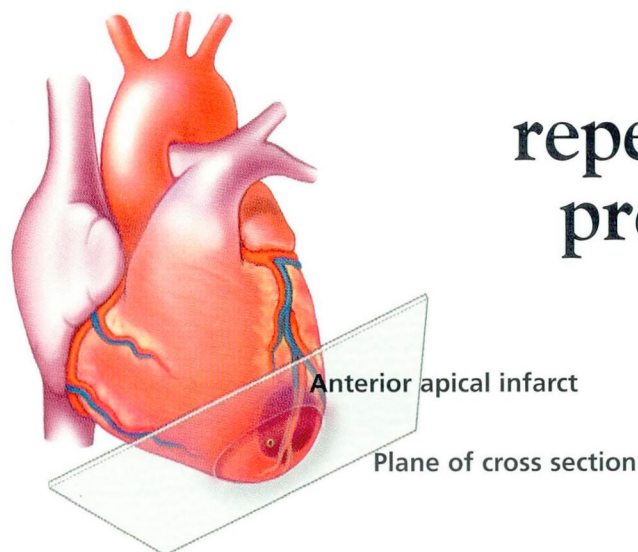
Acute left ventricular dilatation after myocardial infarction can be viewed as a compensatory mechanism, since according to the Frank-Starling law it helps maintain the stroke volume despite loss of contractile tissue.¹⁰ However, it also increases systolic and diastolic wall stress and stimulates further dilatation. Moreover, increased wall stress leads to myocyte stretching¹¹ and stimulates myocyte hypertrophy,¹² which may decrease wall stress and attenuate left ventricular dilatation. Of note, hypertrophy of normal segments in experimental rats occurs early, within 3 days of a myocardial infarction¹¹; however, the magnitude of these changes in humans is not defined yet.

■ THROMBOLYSIS AND REPERFUSION PREVENT INFARCT EXPANSION

Short-term findings

Jeremy et al,¹³ in a study of patients who did not receive thrombolytic therapy, found less

FIGURE 2



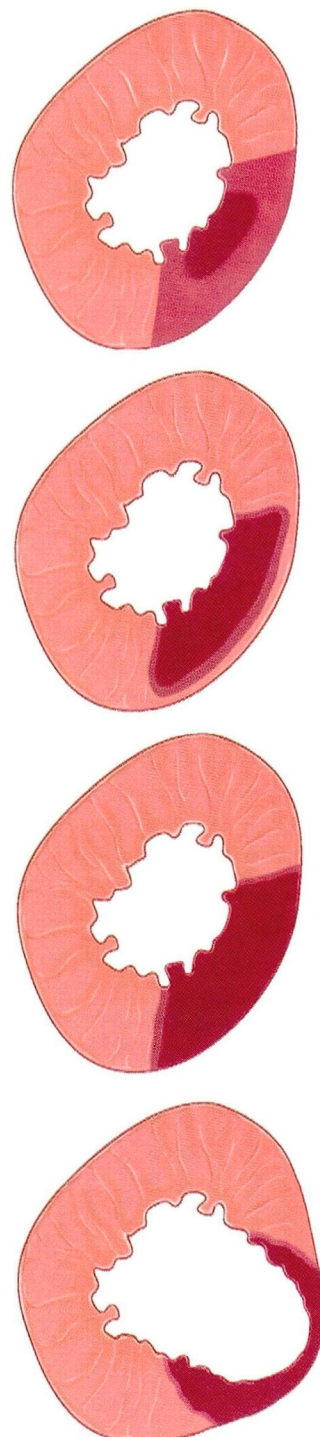
How early reperfusion may prevent infarct expansion

EARLY REPERFUSION may spare the subepicardium and border zone from necrosis. Even if the infarct-related artery later becomes reoccluded, brief periods of reperfusion may "precondition" the myocardium and limit the ultimate infarction.

LATE REPERFUSION may preserve the epicardial rim and spare some of the border zone from necrosis.

NO REPERFUSION leads to a transmural infarct.

INFARCT EXPANSION, with regional dilatation and thinning, can continue over time, leading to dilatation of the entire left ventricle and hypertrophy of normal segments.

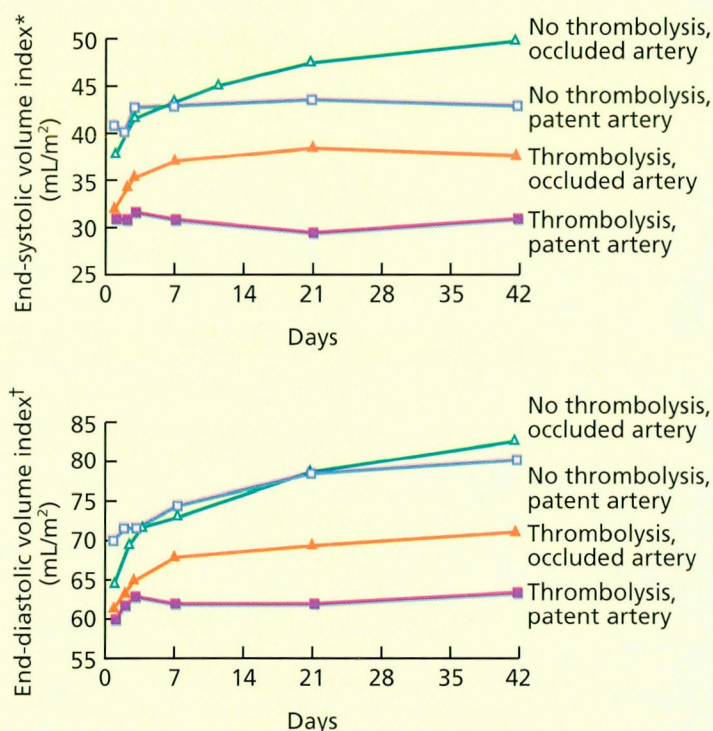


Adapted from Topol, reference 23; with permission from W.B. Saunders.



FIGURE 3

THROMBOLYSIS AND ARTERY PATENCY PREVENTED INFARCT EXPANSION



* $P = .008$, thrombolysis vs no thrombolysis; $P < .001$, patent vs occluded

† $P = .003$, thrombolysis vs no thrombolysis; $P = .021$, patent vs occluded

From Popović et al, reference 18, reproduced with permission from the American Heart Association

ventricular dilatation at 1 month in patients with patent infarct-related arteries than with occluded arteries. The same group¹⁴ also showed that left ventricular dilatation may continue over 6 months.

The GISSI study (*Gruppo Italiano per lo studio della streptochinasi nell'infarto miocardico*)¹⁵ showed that end-diastolic and end-systolic volumes at discharge and at 6 months were smaller in patients given thrombolytic therapy than without thrombolytic therapy. Lavie et al¹⁶ demonstrated that thrombolysis-induced reperfusion was associated with less ventricular dilatation 6 weeks after infarction.

Sheehan et al¹⁷ reported that thrombolysis improves left ventricular function within days after infarction.

In a 6-week study,¹⁸ we demonstrated that thrombolytic therapy prevents left ventricular dilatation in the earliest phase of infarction; the beneficial effect of thrombolysis was detectable within hours after infarction. Further, thrombolysis was beneficial even if the infarct-related vessel was not patent on follow-up angiography (performed at a mean of 26 days) (FIGURE 2). Dilatation was least in patients who received thrombolytic therapy and who had a patent infarct-related artery, whereas it was greatest in patients who did not receive thrombolytic therapy and whose arteries remained occluded (FIGURE 3).

Of interest, patients who received thrombolytic therapy but still had an occluded artery had less left ventricular dilatation than did patients who did not receive thrombolysis but who had a patent artery. A possible explanation is that even brief periods of thrombolysis-induced reperfusion during the acute phase may prevent infarct expansion and subsequent left ventricular dilatation.

A two-stage regression model that we developed for temporal analysis of ventricular volumes indicates that thrombolytic therapy and vessel patency may have independent and complementary effects: thrombolysis primarily affected ventricular size early on, and early patency was primarily predictive of subsequent changes. Additionally, we found that after 6 weeks, ventricular dilatation occurred mostly in patients with anterior infarctions (FIGURE 4). On the basis of these results, we hypothesize that thrombolysis prevents or reduces infarct expansion in the acute phase of myocardial infarction.

Long-term findings

In a longer study in patients with anterior infarctions,¹⁹ we performed serial echocardiographic studies from the onset of infarction up to 1 year, measuring the perimeter of the infarcted segment and the left ventricular volume index (ie, the left ventricular volume divided by the body surface area).

We found that thrombolysis led to a progressive decrease of the infarct perimeter, starting as early as 2 days after infarction and continuing over the subsequent year (FIGURE 5). This infarct regression cannot be related to recovery from myocardial “stunning.” Although stunned myocardium usually starts to recover several days after successful reperfusion, the process does not continue for so long as this yearlong infarct regression. Rather, infarct regression is a consequence of contraction of scar tissue, leading to a decrease in the infarcted segment.

Logistic regression analysis showed that thrombolysis was the major negative predictor of infarct expansion, more important than infarct size and late vessel patency. During 1-year follow-up, left ventricular volume continued to increase significantly in patients who had evidence of infarct expansion early on (FIGURE 6). In patients without infarct expansion, there was a mild increase in the left ventricular end-diastolic volume index, whereas end-systolic volume did not increase over 1 year. Further, both the end-diastolic and the end-systolic volume indexes were higher in patients with infarct expansion from the beginning of the study through 1 year than in patients without infarct expansion (FIGURE 6).

■ HOW DOES THROMBOLYSIS PREVENT EXPANSION?

Sparing the myocardium

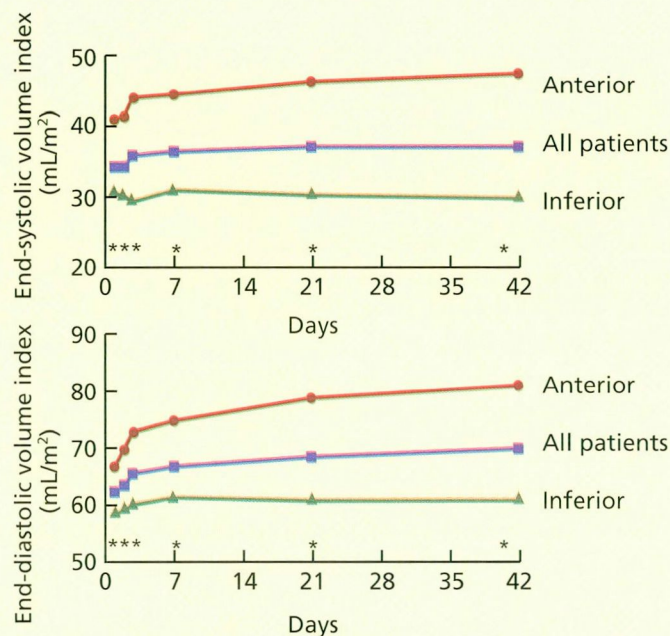
The proposed mechanism by which infarct-related artery reperfusion may prevent infarct expansion is shown in FIGURE 2. Reperfusion prevents transmural infarction, and the rim of viable subepicardial myocardium prevents elongation and thinning of the infarcted segment (ie, expansion).

“Preconditioning” the myocardium

Although the goal of thrombolytic therapy is to open the occluded infarct-related artery, it appears that thrombolysis is still beneficial (to a lesser extent) in patients whose blocked vessels initially reopened but reoccluded later. It has been suggested that angina preceding the infarction can “precondition” the myocardium and result in smaller infarcts²⁰ and better prognosis.²¹ Although the underlying mechanism for the beneficial effect of thrombolysis in patients with reocclusion remains to be determined, a hypothesis is that single or several episodes of reperfusion early

FIGURE 4

ANTERIOR INFARCTS WERE MORE LIKELY TO LEAD TO VENTRICULAR DILATATION

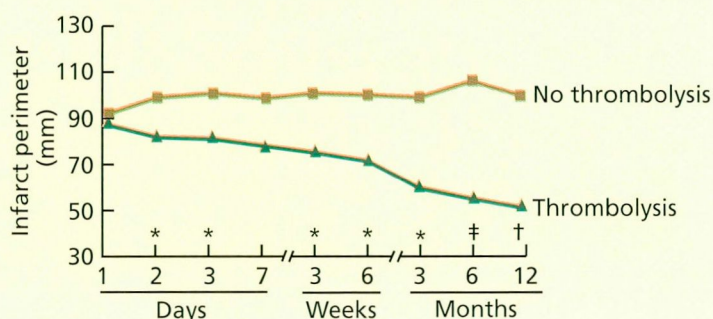


* $P < .001$

From Popović et al, reference 18; reproduced with permission from the American Heart Association

FIGURE 5

THROMBOLYSIS LED TO INFARCT REGRESSION



* $P < .05$

† $P < .01$

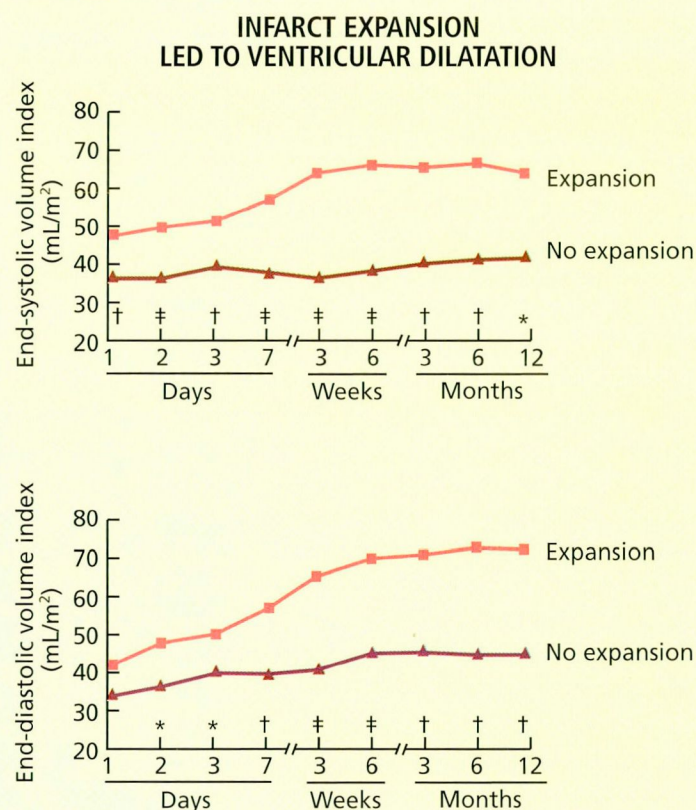
‡ $P < .001$

From Popović et al, reference 19; reproduced with permission from the American Journal of Cardiology

after acute myocardial infarction may also precondition the jeopardized myocardium. Therefore, the ultimate occlusion of the vessel may cause smaller infarcts and less ventricular dilatation.



FIGURE 6

* $P < .05$ † $P < .01$ ‡ $P < .001$ From Popović et al, reference 19; reproduced with permission from the *American Journal of Cardiology*

CLINICAL IMPLICATIONS

The studies reviewed above indicate that the left ventricular end-systolic volume index is the most sensitive predictor of changes in left ventricular geometry; as early as 1 day after infarction, this measurement shows differences between patients who did or did not undergo thrombolysis. Similarly, White et al²² showed that the end-systolic volume was the major independent predictor of prognosis after myocardial infarction—better than left ventricular ejection fraction. Although most thrombolytic trials used the ejection fraction

to assess left ventricular function after the intervention, it now seems clear that serial measurements of left ventricular volume provide better insight into left ventricular systolic function after myocardial infarction.²³

Experiments that compared direct measurements of left ventricular volume with echocardiographic measurements calculated by Simpson's method yielded a high correlation coefficient (> 0.97) and low standard errors.²⁴ Excellent correlations have also been obtained in patients.²⁵ These measurements are also reproducible, varying relatively little when different physicians perform them: 11% for end-diastolic volume and 15% for end-systolic volume in one study.²⁶ Since echocardiography is noninvasive and less expensive than other imaging techniques, it is the technique of choice for routine assessment of left ventricular size and function after myocardial infarction.

Therefore, echocardiographic determination of left ventricular volume after thrombolytic (or any other) intervention early after the onset of myocardial infarction, or at least at hospital discharge, may identify patients who are at high risk of ventricular remodeling and who may eventually develop heart failure. We favor early echocardiographic examination after infarction, assessing both global ventricular size and function and the extent of regional wall-motion abnormality. High-risk patients require more aggressive management both during the acute phase and after hospital discharge. For example, the early use of nitrate therapy followed by afterload reduction by angiotensin-converting enzyme inhibitors may prevent expansion and improve survival. ■

REFERENCES

1. Hutchins GM, Bulkley BH. Infarct expansion versus extension: two different complications of acute myocardial infarction. *Am J Cardiol* 1978; 41:1127–1132
2. Weisman HF, Bush DE, Mannisi JA, Weisfeldt ML, Healy B. Cellular mechanisms of myocardial infarct expansion. *Circulation* 1988; 78:186–201.
3. Vracko R, Thornton D, Frederickson RG. Connective tissue cells in healing rat myocardium. *Am J Pathol* 1989; 134:993–1006.
4. McKay RG, Pfeffer MA, Pasternak RC, et al. Left ven-

- tricular remodeling after acute myocardial infarction: a corollary to infarct expansion. *Circulation* 1986; 74:693–702.
5. Shuster EH, Bulkley BH. Expansion of transmural myocardial infarction: a pathophysiologic factor in cardiac rupture. *Circulation* 1979; 60:1532–1538.
 6. Burton AC. The importance of the shape and size of the heart. *Am Heart J* 1957; 54:801–810.
 7. Role L, Bogen D, McMahon TA, Abelman WH. Regional variations in calculated diastolic wall stress in rat left ventricle. *Am J Physiol* 1978; 4:H247–H250.
 8. Theroux P, Ross J Jr, Franklin D, Covell JW, Bloor CM, Sasayama S. Regional myocardial function and dimensions early and late after myocardial infarction in the unanesthetized dog. *Circ Res* 1977; 40:158–165.
 9. Erlebacher JA, Weiss JL, Eaton LW, Kallman C, Weisfeldt ML, Bulkley BH. Late effects of acute infarct dilation on heart size: a two-dimensional echocardiographic study. *Am J Cardiol* 1982; 49:1120–1126.
 10. Pfeffer MA, Braunwald E. Ventricular remodeling after myocardial infarction: experimental observations and clinical implications. *Circulation* 1990; 81:1161–1172.
 11. Olivetti G, Capasso JM, Sonnenblick EH, Anversa P. Side-to-side slippage of myocytes participates in ventricular wall remodeling acutely after myocardial infarction in rats. *Circ Res* 1990; 67:23–34.
 12. Anversa P, Loud AV, Levicky V, Guideri G. Left ventricular failure induced by myocardial infarction: I. Myocyte hypertrophy. *Am J Physiol* 1985; 248:H876–H882.
 13. Jeremy RW, Hackworthy RA, Bautovich G, Hutton BF, Harris PJ. Infarct artery perfusion and changes in left ventricular volume in the month after acute myocardial infarction. *J Am Coll Cardiol* 1987; 9:989–995.
 14. Jeremy RW, Allman KC, Bautovich G, Harris PJ. Patterns of left ventricular dilation during the six months after myocardial infarction. *J Am Coll Cardiol* 1989; 13:304–310.
 15. Marino P, Zanolla L, Zardini P. Effect of streptokinase on left ventricular modeling and function after myocardial infarction: The GISSI (*Gruppo Italiano per lo studio della streptochinasi nell'infarto miocardico*) trial. *J Am Coll Cardiol* 1989; 14:1149–1158.
 16. Lavie CJ, O'Keefe JH Jr, Chesebro JH, Clements IP, Gibbons RJ. Prevention of late ventricular dilatation after acute myocardial infarction by successful thrombolytic reperfusion. *Am J Cardiol* 1990; 66:31–36.
 17. Sheehan FH, Thery C, Durand P, Bertrand ME, Bolson EL. Early beneficial effect of streptokinase on left ventricular function in acute myocardial infarction. *Am J Cardiol* 1991; 67:555–558.
 18. Popović AD, Nešković AN, Babić R, et al. Independent impact of thrombolytic therapy and vessel patency on left ventricular dilation after myocardial infarction: serial echocardiographic follow-up. *Circulation* 1994; 90:800–807.
 19. Popović AD, Nešković AN, Marinković J, Thomas JD. Acute and long-term effects of thrombolysis after anterior wall acute myocardial infarction with serial assessment of infarct expansion and late ventricular remodeling. *Am J Cardiol* 1996; 77:446–450.
 20. Ottani F, Galvani M, Ferrini D, et al. Prodromal angina limits infarct size: a role for ischemic preconditioning. *Circulation* 1995; 91:291–297.
 21. Kloner RA, Shook T, Przyklenk K, et al. Previous angina alters in-hospital outcome in TIMI 4: a clinical correlate to preconditioning? *Circulation* 1995; 91:37–47.
 22. White HD, Norris RM, Brown MA, Brandt PWT, Whitlock RML, Wild CJ. Left ventricular end-systolic volume as the major determinant of survival after recovery from myocardial infarction. *Circulation* 1987; 76:44–51.
 23. Topol E. Thrombolytic intervention. In: Topol E, editor. *Textbook of interventional cardiology*. Philadelphia: WB Saunders, 1994:75–77.
 24. Wyatt HL, Heng MK, Meerbaum S, et al. Cross-sectional echocardiography. II. Analysis of mathematic models for quantifying volume of the formalin-fixed left ventricle. *Circulation* 1980; 61:1119–1125.
 25. Erbel R, Krebs W, Henn G, et al. Comparison of single-plane and biplane volume determination by two-dimensional echocardiography. I. Asymmetric model hearts. *Eur Heart J* 1982; 3:469–480.
 26. Himelman RB, Cassidy MM, Landzberg JS, Schiller NB. Reproducibility of quantitative two-dimensional echocardiography. *Am Heart J* 1988; 115:425–431.

ADDRESS: Aleksandar D. Popović, MD, e-mail: epopoval@ubbg.etf.bg.ac.yu
Mailing address: Cardiovascular Research Center, Dedinje Cardiovascular Institute, Milana Tepića 1, 11040 Belgrade, Yugoslavia