

DAVID L. LONGWORTH, MD, AND JAMES K. STOLLER, MD, EDITORS

A 56-year-old woman with syncope, chest pressure, and exertional dyspnea

A 56-YEAR-OLD WOMAN experienced the sudden onset of midsternal chest pressure, which lasted for 2 days. On the third day she had a syncopal episode that lasted for approximately 45 seconds, followed by a feeling of lightheadedness, shortness of breath, and fatigue. The next day she had a second syncopal episode and was admitted to a local hospital.

Continuous cardiac monitoring failed to reveal an abnormal cardiac rhythm. Electrocardiography showed no evidence of acute myocardial infarction, and cardiac enzyme levels were normal. While in the hospital, the patient had several short episodes of chest pressure. Her breathing was comfortable at rest, but even minimal exertion such as walking to the bathroom caused significant shortness of breath. She was transferred to our hospital 10 days after the first episode of midsternal chest pressure.

Her blood pressure on admission was 110/70 mm Hg, respiratory rate 16 per minute, and heart rate 102 beats per minute with a regular rhythm. No cardiac murmurs were detected. The lungs were clear to percussion and auscultation. The abdominal examination was normal. There was no peripheral edema, and all peripheral pulses were normal. The chest roentgenogram was normal. The electrocardiogram was normal except for a sinus tachycardia.

1 On the basis of these findings, what is the most likely diagnosis?

- ☐ Acute myocardial infarction
- ☐ Sick sinus syndrome
- ☐ Acute pulmonary embolism

- ☐ Aortic dissection
- ☐ Pneumonia

Given this clinical scenario, the most plausible diagnosis is acute pulmonary embolism. The normal electrocardiogram and normal cardiac enzyme levels essentially exclude acute myocardial infarction. Although sick sinus syndrome can cause syncopal episodes, it should not cause chest pressure and shortness of breath. In addition, continuous cardiac monitoring found no abnormal cardiac rhythm. Aortic dissection can present with acute syncope, chest pressure, and shortness of breath; however, because the chest roentgenogram showed a normal-sized mediastinum, a normal heart size, and an absence of pleural effusion or parenchymal infiltrates, one is led toward the diagnosis of pulmonary embolism and away from aortic dissection.

While there has been a decline in ischemic heart disease and stroke mortality in the last 30 years, the mortality rate from acute pulmonary embolism has not really changed. This case illustrates some of the reasons. The signs and symptoms of acute pulmonary embolism are nonspecific. Many physicians are not aware that syncope was present in 14% of patients in the streptokinase and urokinase pulmonary embolism trials. Syncope occurred in 22% of patients with massive pulmonary embolism. Although dyspnea occurred in 81% of all patients, pulmonary embolism is often not considered when patients present with only exertional shortness of breath. Exertional dyspnea may be a clue to severe right ventricular dysfunction and impending chronic thromboembolic pulmonary hypertension.

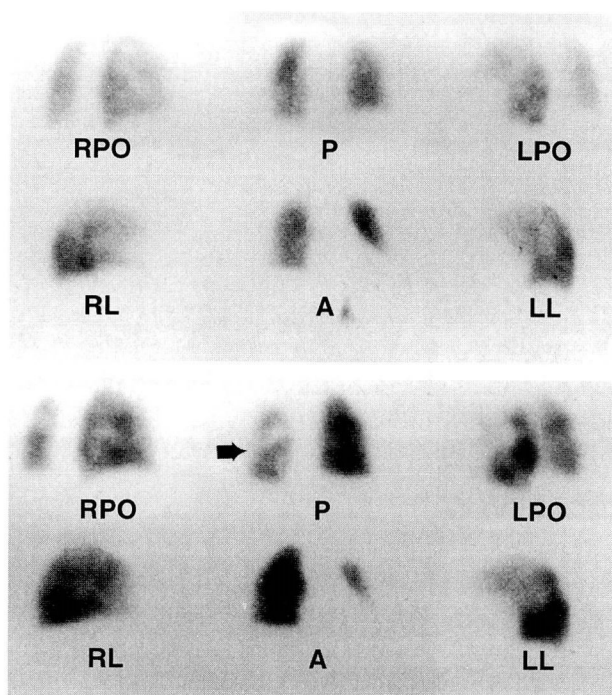


FIGURE 1. Ventilation (top) and perfusion (bottom) lung scan. RO, right posterior oblique; P, posterior; LPO, left posterior oblique; RL, right lateral; A, anterior; LL, left lateral.

2 What is the next step in the diagnosis and management of this patient?

- ☐ Pulmonary arteriography
- ☐ Ventilation and perfusion lung scanning
- ☐ Duplex ultrasonography of the lower extremities
- ☐ Bolus administration of heparin followed by continuous heparin infusion
- ☐ Lung scanning and heparin
- ☐ All of the above

Once the diagnosis of pulmonary embolism is strongly suspected, the patient should be immediately anticoagulated, provided there are no contraindications to it. A bolus of heparin should be given, and a continuous heparin drip should be started while further evaluation takes place. This protects the patient immediately against further pulmonary emboli and extension of deep venous thrombosis. Pulmonary embolism is not correctly diagnosed antemortem in approximately 70% of patients who survive the first hour. If the diagnosis is not made,

the mortality rate is 30%; if the diagnosis is correctly made, the mortality rate is 5% to 8%. Arterial blood gases should be checked at this time to determine if severe hypoxemia is present; if it is, supplemental oxygen should be given. As soon as the heparin infusion is started, the patient should be sent for a ventilation and perfusion lung scan (see Figure 1).

3 Which of the following statements about the ventilation and perfusion scan in Figure 1 is true?

- ☐ It is normal
- ☐ It shows a high probability of pulmonary embolism
- ☐ It is nondiagnostic
- ☐ It shows a low probability of pulmonary embolism

This is a “high-probability” lung scan. There is an overall decrease in radionuclide uptake in the left lung compared with the right on the perfusion scan. This difference is particularly visible in the posterior and anterior views. The ventilation portion of the scan is normal. This overall decrease in radionuclide uptake suggests a large embolism in the left main pulmonary artery. In the presence of a high-probability lung scan, the probability of pulmonary embolism is 87%.

4 What is the next step in the management and treatment of this patient?

- ☐ Continue heparin therapy and institute warfarin for a total of 3 months
- ☐ Perform pulmonary arteriography
- ☐ Place an inferior vena cava filter
- ☐ Initiate thrombolytic therapy with either tissue plasminogen activator (t-PA) or urokinase
- ☐ Pulmonary arteriography and vena cava filter placement
- ☐ Pulmonary arteriography and thrombolytic therapy

This patient is a candidate for thrombolytic therapy. Indications for thrombolytic therapy include acute hemodynamic instability, acute and subacute right ventricular dysfunction, and impending chronic thromboembolic pulmonary hypertension. The streptokinase and urokinase pulmonary embolism trials showed thrombolytic therapy can reverse acute hemodynamic instability by decreasing pul-

monary artery pressure and right ventricular pressure. While these studies did not show a significantly decreased mortality rate in the group receiving thrombolytic therapy, they did show a trend toward lower mortality in patients with massive pulmonary embolism. In a prospective study comparing t-PA with heparin, Goldhaber and colleagues showed t-PA lowers right ventricular end diastolic area and reverses abnormal right ventricular dilatation and dysfunction significantly faster and better than standard heparin anticoagulation.

A minority of patients with pulmonary embolism develop chronic thromboembolic pulmonary hypertension. This may lead to life-threatening right-sided heart failure, severe debilitation, and ultimately, death. The patient under discussion in all likelihood would have developed chronic thromboembolic pulmonary hypertension. It had been 10 to 12 days after her initial episode, and she was still severely short of breath with even minimal activity. An echocardiogram showed a massively dilated right ventricle with severe right ventricular dysfunction and 3+ tricuspid regurgitation. While the patient was not acutely unstable from a hemodynamic standpoint, she was severely limited in that she could not function outside of her bed. The indications for thrombolytic therapy in this patient were to reverse acute and subacute right ventricular dysfunction and to prevent chronic thromboembolic pulmonary hypertension.

Several studies have compared t-PA with urokinase in the treatment of acute pulmonary embolism. A recently published, randomized, controlled, double-blind trial comparing 100 mg of t-PA given over 2 hours with 3 million units of urokinase given over 2 hours showed that these agents were virtually identical in the rate of thrombus lysis and in the frequency of complications.

While a young, relatively healthy patient with a high-probability lung scan can undergo thrombolysis on the basis of the lung scan alone, this patient needed a pulmonary arteriogram, since her initial episode had occurred 10 to 12 days previously. Patients such as this will in all likelihood require a more prolonged thrombolytic infusion in order to obtain complete thrombolysis. Her pulmonary arteriograms before and after urokinase infusion are shown in Figure 2.

Stein and colleagues studied 1111 patients undergoing pulmonary arteriography. The mortality rate was 0.5%, and the combined morbidity and mortal-

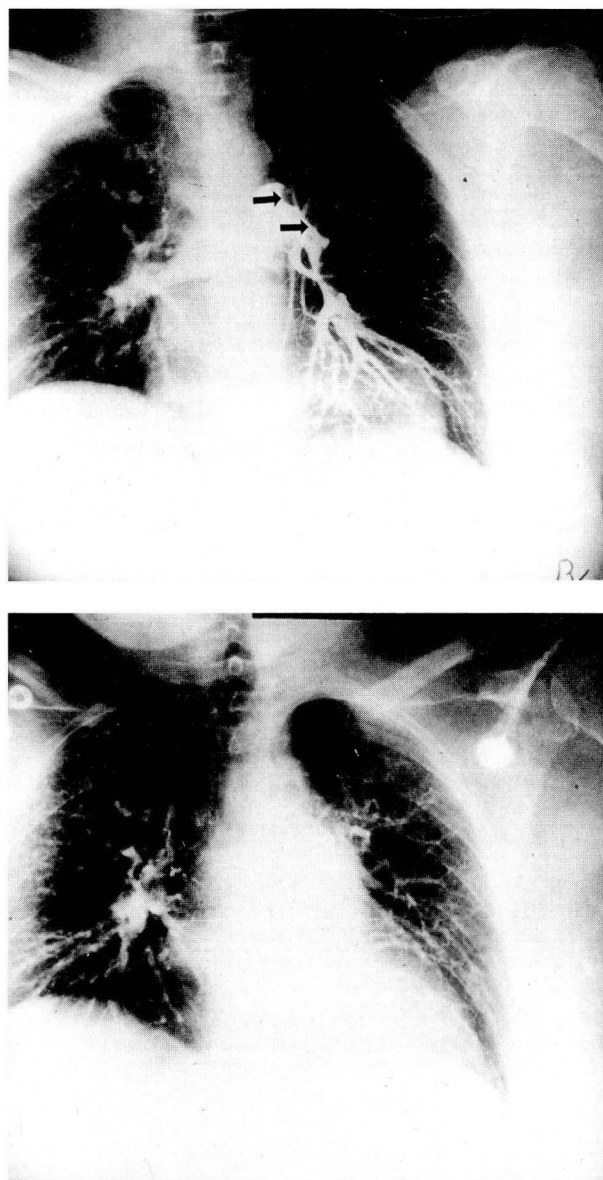


FIGURE 2. The pulmonary arteriogram before thrombolytic therapy (top). Arrows point to a large embolism completely obstructing the left main pulmonary artery. There is only a small amount of perfusion in the left lower lobe. After 18 hours of urokinase infusion (bottom) most of the thrombus has been successfully lysed, but there is still a lack of perfusion in the left apex.

ity was only 1.3%. Therefore, if the diagnosis is in doubt or if thrombolytic therapy is being considered, pulmonary arteriography can be performed safely.

This patient received urokinase in a dose of 4400 U/kg as a bolus and 4400 U/kg/hour. Following 18 hours of infusion the urokinase was discontinued.

The patient was no longer short of breath with exertion. Her activity was unlimited. She was treated with warfarin for 6 months. A repeat echocardiogram showed resolution of her right ventricular dilatation and dysfunction and of her tricuspid regurgitation.

JEFFREY W. OLIN, DO
Department of Vascular Medicine
The Cleveland Clinic Foundation

SUGGESTED READING

Carson JL, Kelley MA, Duff A, et al. The clinical course of pulmonary embolism. *N Engl J Med* 1992; 326:1240-1245.

Dalen JE, Alpert JS. Natural history of pulmonary embolism. *Prog Cardiovasc Dis* 1975; 17:259-270.

Goldhaber SZ, Haire WD, Feldstein ML, et al. Alteplase versus heparin in acute pulmonary embolism: A randomized trial assessing right-ventricular function and pulmonary perfusion. *Lancet* 1993; 341:507-511.

Goldhaber SZ, Kessler CM, Heit, JA et al. Recombinant tissue type plasminogen activator versus a novel dosing regimen of urokinase in acute pulmonary embolism: A randomized, controlled multicenter trial. *J Am Coll Cardiol* 1992; 20:24-30.

Moser KM, Auger WR, Fedullo PF. Chronic major-vessel thromboembolic pulmonary hypertension. *Circulation* 1990; 81:1735-1743.

The PIOPED investigators. Value of the ventilation/perfusion scan in acute pulmonary embolism. Results of the prospective investigation of pulmonary embolism diagnosis (PIOPED). *JAMA* 1990; 263:2753-2759.

Stein PD, Athanasoulis C, Alavi A, et al. Complications and validity of pulmonary angiography in acute pulmonary embolism. *Circulation* 1992; 85:462-468.

Urokinase pulmonary embolism trial. Phase I results: A cooperative study. *JAMA* 1970; 214:2163-2172.

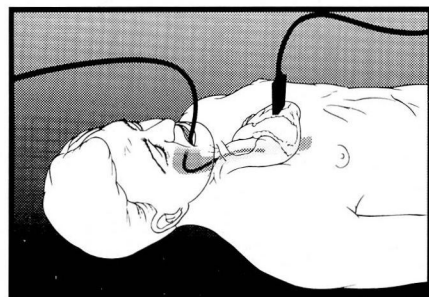
Urokinase-streptokinase pulmonary embolism trial. Phase II results: A cooperative study. *JAMA* 1974; 229:1606-1613.

Weinmann EE, Salzman EW. Deep-vein thrombosis. *N Eng J Med* 1994; 331:1630-1641.



THE CLEVELAND CLINIC FOUNDATION

presents



Invasive Echocardiography:

A Live Demonstration Course of
Transesophageal and
Intraoperative Echo

September 26-29, 1995

(Tuesday - Friday)

Bunts Auditorium CCF
Cleveland, Ohio

Featuring

LIVE DEMONSTRATIONS

and

INTERACTIVE COMPUTER
SYSTEM FOR LECTURES

Course Director

WILLIAM J, STEWART, MD
CARDIAC FUNCTION CLINIC

Objectives

To recognize the proper indications for transesophageal and intraoperative echocardiography. To determine impact of these diagnostic procedures on the natural history of the various disorders and to apply the echo information to optimum patient care.

For further information and/or a course brochure, please write or call:

The Cleveland Clinic Foundation
Department of Continuing Education - TT-31
9500 Euclid Ave.
Cleveland, Ohio 44195

(216)444-5695 (Local)

(800)762-8173 (Toll-free)

(216)445-9406 (FAX)