



# Intrahepatic cholestasis during nicotinic acid therapy

SANAT D. PATEL, MD, AND HARRIS C. TAYLOR, MD

- **BACKGROUND** Nicotinic acid, widely used to lower serum cholesterol levels, may rarely cause cholestatic jaundice.
- **SUMMARY** A 61-year-old white man with hypercholesterolemia complained of marked pruritus and became jaundiced after taking 3.0 g of crystalline nicotinic acid daily for 13 months. His total serum bilirubin level was increased at 144  $\mu\text{mol/L}$  (8.4 mg/dL) and his alkaline phosphatase level was markedly elevated at 35.00  $\mu\text{kat/L}$  (2100 U/L). Endoscopic retrograde cholangiopancreatography failed to demonstrate an obstructive lesion in the extrahepatic biliary system, computed tomography showed no intrahepatic dilatation, and ultrasonographic studies of the liver, gallbladder, and pancreas were normal; these factors all suggest intrahepatic cholestasis. Symptoms improved and liver function test results returned to normal within 51 days after stopping the drug.
- **CONCLUSIONS** Nicotinic acid-induced cholestatic jaundice may not be as rare as previously thought, and physicians should observe their patients for it.

■ **INDEX TERMS:** CHOLESTASIS, INTRAHEPATIC; NIACIN; JAUNDICE  
 ■ CLEVE CLIN J MED 1994; 61:70-75

From the Division of Endocrinology, Lutheran Medical Center, Cleveland.

Address reprint requests to H.C.T., Division of Endocrinology, Lutheran Medical Center, 2609 Franklin Blvd, Cleveland, OH 44113.

**H**YPERCHOLESTEROLEMIA is an important factor in atherogenesis<sup>1</sup> and its complications, and lowering the serum cholesterol level is associated with decreased cardiovascular morbidity and mortality.<sup>2-4</sup> Introduced in 1955, nicotinic acid (niacin) remains one of the most widely used lipid-lowering drugs.<sup>5</sup> Although many other regimens of diet and lipid-lowering agents have been designed, nicotinic acid is the only one prospectively demonstrated to decrease overall mortality, as well as cardiovascular mortality.<sup>4</sup> Minor abnormalities in liver function frequently arise in association with nicotinic acid therapy, but only 12 cases of cholestatic jaundice and severe liver dysfunction have been reported. We report the 13th such case and review the relevant literature.

## CASE HISTORY

A 61-year-old white man presented on September 29, 1988, with fatigue, pruritus, lower abdominal pain, increased frequency of bowel movements, dark orange urine, and jaundice of about 3

weeks' duration. He denied alcohol intake, previous blood transfusion, exposure to known hepatotoxins, intravenous drug abuse, and exposure to persons with hepatitis. His only medications were crystalline nicotinic acid and yohimbine. The nicotinic acid had been prescribed in February 1985 for hypercholesterolemia. The patient stopped taking it on his own in January 1987, but it was restarted in August 1987, and the dosage was gradually increased to 3.0 g/day. He discontinued it because of his symptoms on September 23, 1988, but he may have taken some afterwards. Yohimbine, an alpha-2 adrenergic blocking agent, was prescribed for impotence; he took it on an irregular basis for 6 weeks before stopping on September 3, 1988.

Physical examination revealed an obviously jaundiced white man whose oral temperature was 99°F. He weighed 134.5 lb (6 months earlier he had weighed 138 lb). The liver was palpable one to two finger-breadths below the right costal margin. There was some fullness in the right lower quadrant, but the spleen was not palpable. The results of the rest of the physical examination were normal except for a trace amount of occult blood in the stool.

The hemoglobin level was 151 g/L, the white cell count  $5.7 \times 10^9/L$ , the prothrombin time 14.4 seconds (control 11.4 seconds), and the antimitochondrial antibody titer negative. Results of serial liver function tests are shown in Figure 1. Ultrasonographic study of the abdomen on September 29, 1988, when the total serum bilirubin level was 144  $\mu\text{mol/L}$  (8.4 mg/dL), revealed a large liver without evidence of gallstones and without dilatation of the common bile duct or of the intrahepatic biliary radicles; a computed tomographic scan of the abdomen confirmed these findings. Endoscopic retrograde cholangiopancreatography on October 4, 1988,

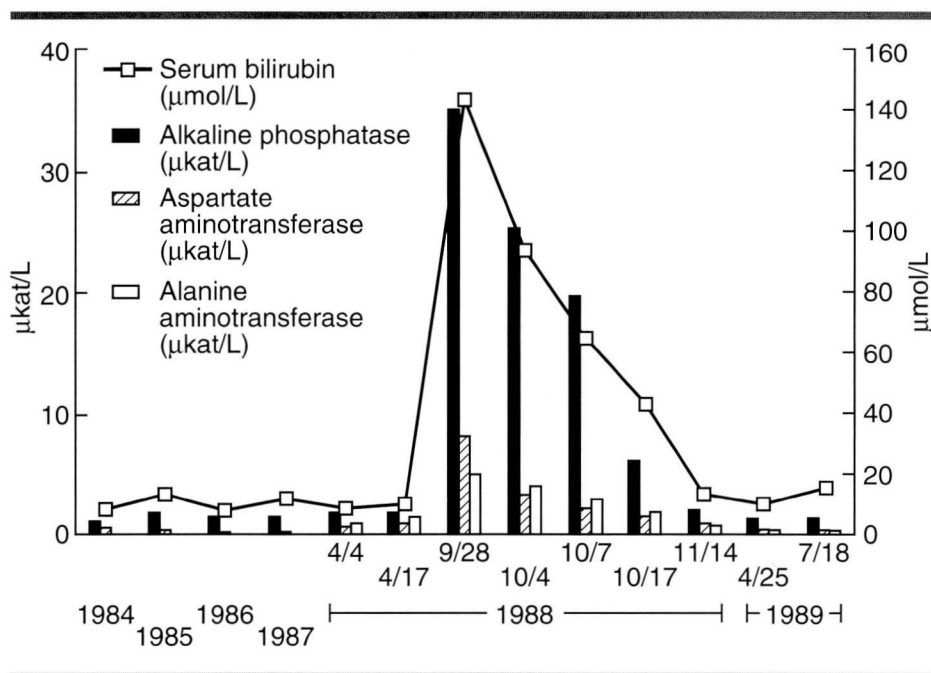


FIGURE 1. Serial liver function test results in a patient with cholestatic jaundice. Normal values for total bilirubin are 3.42 to 20.5  $\mu\text{mol/L}$  (0.2 to 1.2 mg/dL); for alkaline phosphatase 0.67 to 2.58  $\mu\text{kat/L}$  (40 to 155 U/L); for alanine aminotransferase 0 to 0.75  $\mu\text{kat/L}$  (0 to 45 U/L); for aspartate aminotransferase 0 to 0.68  $\mu\text{kat/L}$  (0 to 41 U/L).

when the total serum bilirubin level was 94  $\mu\text{mol/L}$  (5.5 mg/dL), revealed no obstruction of the biliary tree, and no stones were seen in the intrahepatic ducts, right, left, and common hepatic ducts, common bile duct, cystic duct, or gallbladder (Figure 2). The ducts drained well in a delayed film of 10 minutes. Pancreas divisum was noted, an incidental finding of no clinical significance.

Ethical considerations precluded rechallenge with nicotinic acid after resolution of the jaundice. When seen on November 22, 1988, the patient felt much better. At the patient's request and his urologist's recommendation, the yohimbine was restarted on April 1, 1989. When last seen on July 18, 1989, the patient remained well and had completely normal liver function tests despite having taken yohimbine 5.4 mg twice a day for 15 weeks.

## DISCUSSION

Mild abnormalities of liver function arise frequently in patients who receive large dosages of nicotinic acid. Parsons et al<sup>6</sup> studied 36 patients



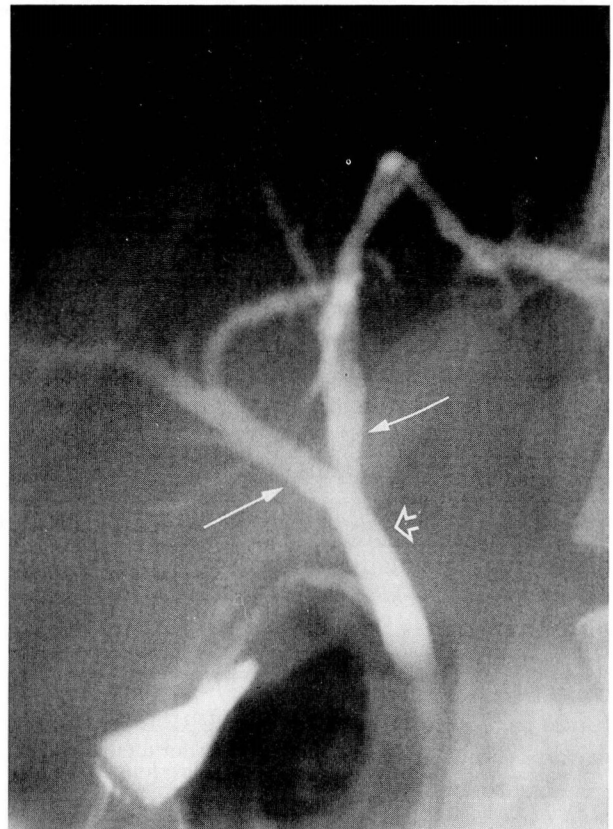
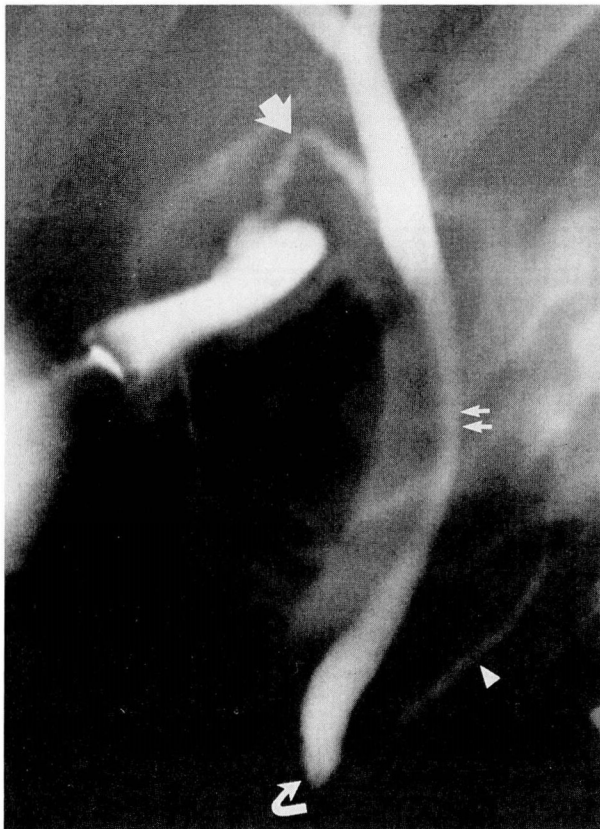

FIGURE 2. Endoscopic retrograde cholangiopancreatogram. Left, the ampulla of Vater (bottom curved arrow), pancreatic duct (solid arrow head), common bile duct (two small arrows), and cystic duct (large solid arrow), are normal and free of stones, strictures, and dilatation. Right, the common hepatic duct (open arrow) and right and left hepatic ducts (two thin arrows) are also normal.

taking nicotinic acid therapy for 2.5 years or longer. Ten patients acquired liver function abnormalities, but only one became jaundiced. We discuss this patient below. Berge et al<sup>7,8</sup> described 66 patients; 25 had at least one abnormal liver function test,<sup>7</sup> and two became jaundiced.<sup>8</sup> An increased frequency of abnormal liver function test results has been reported with long-acting preparations of nicotinic acid.<sup>8,9</sup> Nonetheless, cholestatic jaundice and severe hepatic dysfunction clearly ascribable to nicotinic acid have been described in only 12 cases, summarized in the *Table*.

The first such patient, described by Rivin,<sup>10</sup> complained of pruritus after 1 year of treatment with nicotinic acid, 3.0 g/day. Pruritus disappeared when the drug was discontinued. However, pruritus resumed and jaundice appeared when nicotinic acid was restarted. When nicotinic acid was discontinued a second time, serum enzyme and bilirubin lev-

els returned to normal and itching disappeared during a 20-day period of hospitalization. Winter et al<sup>11</sup> reported a similar case in a patient taking nicotinamide, and Patterson et al<sup>12</sup> reported another case in a patient taking nicotinic acid; both patients were rechallenged with higher dosages, and both again experienced elevated serum bilirubin levels, which resolved after the drug was stopped.

Clementz et al<sup>13</sup> described a patient who suffered hepatocellular injury with a total serum bilirubin level of 19  $\mu\text{mol/L}$  (1.1 mg/dL) while taking 3.0 g/day of nicotinic acid. The liver function test results became normal 6 weeks after stopping the drug. However, 10 weeks after restarting nicotinic acid the patient became icteric with a total serum bilirubin level of 113  $\mu\text{mol/L}$  (6.6 mg/dL). On the third hospital day his total serum bilirubin increased to 183  $\mu\text{mol/L}$  (10.7 mg/dL), and the following day stage 3 hepatic encephalopathy ensued. The patient

TABLE

SUMMARY OF REPORTED CASES OF CHOLESTATIC JAUNDICE ASSOCIATED WITH NICOTINIC ACID

Author	Drug*	Dosage (g/day)	Duration	Highest total bilirubin ( $\mu\text{mol/L}$ ) <sup>†</sup>	Highest alkaline phosphatase level <sup>‡</sup>	Highest aspartate aminotransferase level ( $\mu\text{kat/L}$ ) <sup>§</sup>	Liver biopsy	Recovery time
Parsons <sup>6</sup>	NA-C + NA-SR	3.0-4.5	15 months	120	$3.84 \times \text{ULN}$	$3.33 \mu\text{kat/L}$	Yes	2 weeks
Christensen <sup>8</sup>	NA-SR	3.0	3 months	109	$1.72 \times \text{ULN}$	$28.6 \times \text{ULN}$	No	8 weeks
Christensen <sup>8</sup>	NA-SR	3.0	1 week	60	$2.83 \times \text{ULN}$	$3.9 \times \text{ULN}$	Yes	7 weeks
Rivin <sup>10</sup>	NA-C	3.0	17 months	127	$3.46 \times \text{ULN}$	$1.52 \mu\text{kat/L}$	No	20 days
Winter <sup>11</sup>	Nde	3.0-9.0	18 months	84	$1.03 \mu\text{kat/L}$	$34.54 \mu\text{kat/L}$	Yes	3 weeks
(rechallenge)	Nde	9.0	10 days	21	...	$2.58 \mu\text{kat/L}$	No	22 days
Patterson <sup>12</sup>	NA-C	4.5	6 months	103	$9.04 \mu\text{kat/L}$	$3.47 \mu\text{kat/L}$	No	2 weeks
(rechallenge)	NA-C, Nde	4.5, 3.0	18 months	137	$6.32 \mu\text{kat/L}$	$43.34 \mu\text{kat/L}$	Yes	7 weeks
Clementz <sup>13</sup>	NA-C	3.0	1 month	19	...	$7.13 \mu\text{kat/L}$	No	6 weeks
(rechallenge)	NA-C	3.0	10 weeks	183	$3.98 \mu\text{kat/L}$	$235.71 \mu\text{kat/L}$	No	4 months <sup>  </sup>
Mullin <sup>14</sup>	NA-C, NA-SR	6.0, 6.0	17 months, 3 days	168	$6.42 \mu\text{kat/L}$	$103.22 \mu\text{kat/L}$	Yes	Liver transplanted
Sugerman <sup>15</sup>	NA-C	0.75	3 months	335	$3.42 \mu\text{kat/L}$	$1.68 \mu\text{kat/L}$	Yes	"Several months"
Einstein <sup>16</sup>	NA-?	3.0	30 months	520	$3.08 \times \text{ULN}$	$3.78 \mu\text{kat/L}$	Yes	2 months
Hodis <sup>18</sup>	NA-SR	0.5	2 months	564	$3.83 \mu\text{kat/L}$	$150.03 \mu\text{kat/L}$	No	>8 weeks
Henkin <sup>19</sup>	NA-SR	2.0	6 months	121	$38.76 \mu\text{kat/L}$	$3.78 \mu\text{kat/L}$	No	6 weeks
Present study	NA-C	3.0	13 months	144	$35.00 \mu\text{kat/L}$	$8.10 \mu\text{kat/L}$	No	51 days

\*NA-C, nicotinic acid, crystalline; Nde, nicotinamide; NA-SR, nicotinic acid, sustained-release

<sup>†</sup>Normal range for total serum bilirubin is 2 to 18  $\mu\text{mol/L}$ 
<sup>‡</sup>Normal range for alkaline phosphatase is 0.5 to 2.0  $\mu\text{kat/L}$ ;  $\times \text{ULN}$ , times upper limit of normal

<sup>§</sup>Normal range for aspartate aminotransferase is 0 to 0.58  $\mu\text{kat/L}$ 
<sup>||</sup>Except gamma-glutamyl transferase

recovered from the hepatic encephalopathy in 10 days; after 4 months, liver function test results were all normal except for a minimally elevated gamma-glutamyl transferase level. There was no mention that nicotinic acid was discontinued.

Recently, Mullin et al<sup>14</sup> described a patient with fulminant hepatic failure. The patient took crystalline nicotinic acid 6.0 g/day for 1 year without side effects, but 3 days after switching to sustained-release nicotinic acid 6.0 g/day he became jaundiced; his total serum bilirubin level was 168  $\mu\text{mol/L}$  (9.8 mg/dL). He became progressively more jaundiced, and fulminant hepatic failure followed. The patient had a successful liver transplantation.

In one of the two patients described by Christensen et al,<sup>8</sup> jaundice appeared after 3 months' use of sustained-release nicotinic acid. The maximum total serum bilirubin level was 109  $\mu\text{mol/L}$  (6.4 mg/dL), and liver function test results returned to normal in 8 weeks after discontinuing the drug. In the other pa-

tient, jaundice appeared after 7 days, the maximum total serum bilirubin level was 60  $\mu\text{mol/L}$  (3.5 mg/dL), and liver function test results returned to normal in 7 weeks after discontinuing the drug.

In Sugerman and Clark's patient,<sup>15</sup> severe cholestatic jaundice was confirmed by biopsy, cholangiography, and laparotomy. In one of the three cases reported in greater detail because of their severity by Parsons et al<sup>6</sup> (and the only one with jaundice), hepatic dysfunction most likely was attributable to nicotinic acid. Einstein et al<sup>16</sup> reported a case of jaundice with a total serum bilirubin level of 520  $\mu\text{mol/L}$  (30.4 mg/dL) in a patient who took massive dosages of multivitamins including 3.0 g of nicotinic acid daily for 2.5 years. The jaundice resolved 2 months after discontinuing nicotinic acid. However, in the patient described by Kohn and Montes,<sup>17</sup> several factors call into question the role of nicotinic acid in causing the jaundice: the patient received tolbutamide beginning 1 week before the



appearance of jaundice, and an oral cholecystogram 1 year later revealed a 2.0-cm gallstone and poor function. Hodis<sup>18</sup> briefly described a 32-year-old man in whom stage 4 hepatic encephalopathy occurred after 2 months of using a daily 500-mg timed-release niacin tablet. A peak bilirubin level of 564  $\mu\text{mol/L}$  (33.0 mg/dL) accompanied grossly abnormal hepatic enzyme levels, indicating hepatocellular necrosis. Finally, one of three patients described by Henkin et al<sup>19</sup> became jaundiced while taking 1.0 g twice daily of sustained-release niacin. The clinical picture was similar to that of our patient: the peak serum bilirubin level was 121  $\mu\text{mol/L}$  (7.1 mg/dL), the alkaline phosphatase level was 38.76  $\mu\text{kat/L}$  (2325 U/L), and only mild increases in the alanine aminotransferase and aspartate aminotransferase levels were noted.

Six of the 13 patients who became jaundiced in association with nicotinic acid therapy used the sustained-release preparation. In the patient of Einstein et al<sup>16</sup> the type of nicotinic acid therapy was not specified. One of the remaining six patients used nicotinamide, a drug not indicated for therapy of hyperlipidemia.<sup>20</sup>

Knopp<sup>9</sup> has demonstrated that the overall side effect profile of the sustained-release preparation is worse than that of the crystalline compound. Moreover, at least three of the patients with jaundice acquired it after switching from crystalline to sustained-release niacin. It seems appropriate, therefore, to discourage the use of sustained-release nicotinic acid. With the exception of Sugerman's patient,<sup>15</sup> the remaining five patients who used crystalline niacin all took dosages of at least 3.0 g/day. Although lesser degrees of liver dysfunction and adverse symptoms may occur with dosages less than 3.0 g/day of crystalline niacin, this dosage may represent a threshold for jaundice. We recommend, therefore, that particular care be exercised in monitoring patients who require larger dosages for treatment of hyperlipidemia.

The significance of the reported histologic changes for chronic liver disease remains unclear. Patients who had spontaneous resolution after stopping nicotinic acid have demonstrated a variety of histologic changes. These have ranged from marked parenchymal cell necrosis with centrilobular bile stasis in Christensen's second patient<sup>8</sup> to "acute hepatitis with evidence of submassive necrosis, marked cholestasis, and bile duct proliferation" in the patient of Einstein et al.<sup>16</sup> The liver of the patient of Mullin

et al<sup>14</sup> who required transplantation demonstrated "massive hepatic necrosis with collapse of the architecture and prominent cholestasis in the small amount of remaining viable hepatic parenchyma." On the other hand, Winter and Boyer<sup>11</sup> described a patient who demonstrated an increase in portal fibrosis which spread into the hepatic lobules. They described the following findings: "These thin fibrous septa connected several portal triads and formed pseudolobules. Bile ductules were only mildly proliferated. The limiting plates around the portal triads were intact, and there was only a sparse portal inflammatory infiltrate consisting of predominantly chronic inflammatory cells. . . . Although there was a striking absence of cell necrosis or lobular inflammation, a few mitotic figures and a number of canalicular bile plugs were present." However, this patient took nicotinamide, not nicotinic acid. The patient described by Kohn and Montes<sup>17</sup> had also used tolbutamide and had a 2.0-cm gallstone, and a liver biopsy showed "intrahepatic cholestasis with portal chronic inflammation and fibrosis probably related to drug." When the patient died 2 years later of unrelated causes, the liver demonstrated fibrosis resembling posthepatic cirrhosis.

Irrespective of the precise mechanism of hepatic injury or the significance of such injury for later chronic liver disease (both of which are poorly understood), several clinically relevant conclusions can be drawn. First, niacin must be included among drugs known to be responsible for cholestatic jaundice. Second, the disorder is being reported with increasing frequency and may not be as rare as it appears. Third, the sustained-release preparation appears to be more likely to cause cholestatic jaundice and should be avoided. Finally, the use of crystalline niacin at dosages less than 3 g/day appears to minimize the likelihood of such toxicity.

# ACKNOWLEDGMENT

We wish to express our gratitude to Peter Greenwalt, MD, for permission to study his patient.

# REFERENCES

- Steinberg D. Lipoproteins and atherosclerosis. A look back and a look ahead. *Arteriosclerosis* 1983; 3:283.
- Lipid Research Clinics Program. The Lipid Research Clinics Coronary Primary Prevention Trial results I. *JAMA* 1984; 251:351-364.
- Lipid Research Clinics Program. The Lipid Research Clinics Coronary Primary Prevention Trial results II. *JAMA* 1984;

- 251:365-374.
4. **Canner PL, Berge KG, Wenger NK, et al.** Fifteen year mortality in coronary drug project patients: long-term benefit with niacin. *J Am Coll Cardiol* 1986; **8**:1245-1255.
5. **Altschul R, Hoffer A, Stephen JD.** Influence of nicotinic acid on serum cholesterol in man. *Arch Biochem* 1955; **54**:558-559.
6. **Parsons WB Jr.** Studies of nicotinic acid use in hypercholesterolemia. *Arch Intern Med* 1961; **107**:653-667.
7. **Berge KG, Achor RW, Christensen NA, et al.** Hypercholesterolemia and nicotinic acid: A long term study. *Am J Med* 1961; **31**:24-36.
8. **Christensen NA, Achor RW, Berge KG, et al.** Nicotinic acid treatment of hypercholesterolemia. Comparison of plain and sustained-action preparations and report of two cases of jaundice. *JAMA* 1961; **177**:546-550.
9. **Knopp RH, Ginsberg J, Albers JJ, et al.** Contrasting effects of unmodified and time-release forms of niacin on lipoproteins in hyperlipidemic subjects: Clue to mechanism of action of niacin. *Metabolism* 1985; **34**:642-650.
10. **Rivin AV.** Jaundice occurring during nicotinic acid therapy for hypercholesterolemia. *JAMA* 1959; **170**:2088-2089.
11. **Winter AL, Boyer JL.** Hepatic toxicity from large doses of vitamin B3 (nicotinamide). *N Engl J Med* 1973; **289**:1180-1182.
12. **Patterson DJ, Dew EW, Gyorkey F, et al.** Niacin hepatitis. *South Med J* 1983; **76**:239-241.
13. **Clementz GL, Holmes AW.** Nicotinic acid induced fulminant hepatic failure. *J Clin Gastroenterol* 1987; **9**:582-584.
14. **Mullin GE, Greenson JK, Mitchell MC.** Fulminant hepatic failure after ingestion of sustained-release nicotinic acid. *Ann Intern Med* 1989; **111**:253-255.
15. **Sugerman AA, Clark CG.** Jaundice following the administration of niacin. *JAMA* 1974; **228**:202.
16. **Einstein N, Baker A, Gulper J, et al.** Jaundice due to nicotinic acid therapy. *Dig Dis* 1975; **20**:282-285.
17. **Kohn RM, Montes M.** Hepatic fibrosis following long acting nicotinic acid therapy: A case report. *Am J Med Sci* 1969; **258**:94-99.
18. **Hodis HN.** Acute hepatic failure associated with the use of low-dose sustained-release niacin. *JAMA* 1990; **264**:181.
19. **Henkin Y, Johnson KC, Segrest JP.** Rechallenge with crystalline niacin after drug-induced hepatitis from sustained-release niacin. *JAMA* 1990; **264**:241-243.
20. **Rader JL, Calvert RJ, Hathcock JN.** Hepatic toxicity of unmodified and time-release preparations of niacin. *Am J Med* 1992; **92**:77-81.



To earn CME Category I credit, see test on p. 80