

Multisystem autoimmune dysfunction with early onset of bullous emphysema

THOMAS M. ROY, MD; CHERYL L. FIELDS, MD; KAREN R. HABENSTEIN, MD

■ We report a patient with alopecia universalis, autoimmune dysfunction, and rapidly progressing bullous emphysema. These disorders have neither been reported together previously nor classified within a syndrome. To explain early-onset bullous emphysema associated with autoimmune disturbance requires further study; we encourage reporting of similar patients.

□ INDEX TERMS: EMPHYSEMA; LUPUS ERYTHEMATOSUS, CUTANEOUS □ CLEVE CLIN J MED 1993; 60:65-68

WE REPORT A PATIENT with rapidly progressing bullous emphysema associated with an unusual array of autoimmune signs and symptoms. These disorders have neither been reported together previously nor classified within a syndrome.

CASE HISTORY

A 29-year-old white man is currently followed for dyspnea on exertion and an abnormal chest radiograph. His family medical history is unremarkable, and he has no history of smoking, recreational drugs, or exposure to toxins.

The patient enjoyed normal growth and good health until age 14, when he developed idiopathic grand mal seizures. These were controlled with phenytoin 300 mg/day and primidone 750 mg/day.

At age 18, he experienced hair loss which resulted in

alopecia universalis. Several months later, he developed exertional muscle cramps and myotonia. Exhaustive electromyographic and nerve conduction studies failed to yield a definitive diagnosis. The patient was referred to a tertiary care center which confirmed the presence of alopecia universalis and a myotonic problem which was considered to be a forme fruste of stiff-man syndrome. No therapeutic suggestions or alterations in his antiseizure medications were made.

The patient's muscular symptoms seemed to improve with rest and time, and his seizures remained well controlled. His alopecia universalis persisted. The patient gained employment as a material handler in a carpentry shop. Posteroanterior and lateral chest radiography performed as part of his pre-employment physical examination was normal. He experienced cramping in the biceps and calves only after prolonged episodes of strenuous activity.

At age 25, chest radiographs taken as part of a routine physical examination demonstrated severe bilateral upper-lobe bullae (*Figure*). At this time, the patient developed migratory polyarthritis involving his knees, ankles, wrists, and digits of both hands. Morning stiffness was not a problem, but the patient experienced transient joint swelling without erythema,

From the Division of Respiratory and Environmental Medicine, University of Louisville School of Medicine, Louisville, Ky.

Address reprint requests to T.M.R., the Division of Respiratory and Environmental Medicine, University of Louisville School of Medicine, 550 South Jackson Street ACB-3, Louisville, KY 40292.

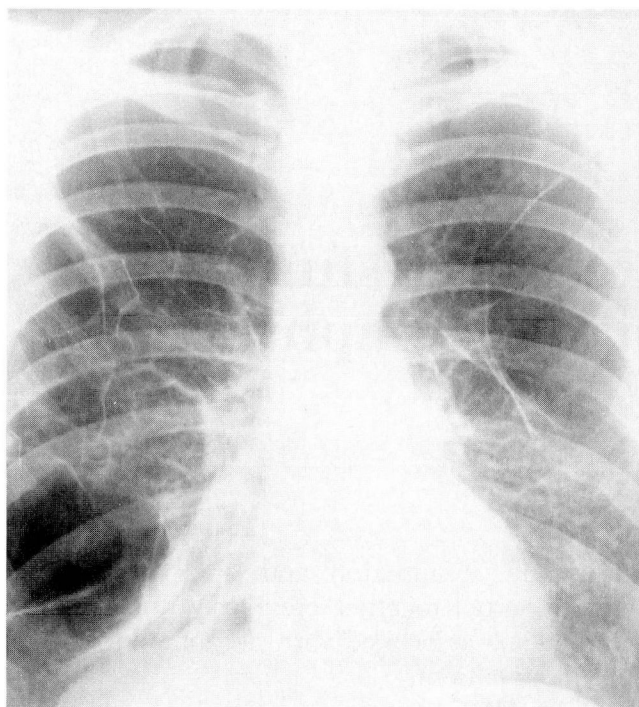


FIGURE. Posteroanterior chest radiograph at age 25 showing severe bilateral upper lobe bullae.

primarily in his wrists and elbows. The patient was referred to us for evaluation because of his employer's concern over potential spontaneous pneumothorax during strenuous activity.

Both helium dilution and body plethysmography confirmed hyperinflation of the lungs and increased residual volume. Alpha-1-antitrypsin levels and sweat chloride levels were repeatedly within normal limits. A gallium scan obtained early in the course of his evaluation failed to show evidence of alveolitis.

Rheumatologic evaluation confirmed swelling of the proximal interphalangeal joints bilaterally and the presence of subcutaneous nodules on the extensor surfaces of the forearms. Radiographs of the hands showed an erosive lesion at the base of the proximal phalanx of the right index finger and obliteration of the articular space between the right multangular joints. The diagnosis of a rheumatoid variant of arthritis was made. The patient's arthritic complaints responded to non-steroidal anti-inflammatory agents, but the development of gastric upset limited their use.

In the search for a more specific rheumatologic diagnosis, immunologic serologic tests were performed on various occasions (Table). Most surprising has been the

recent repeated finding of positive anti-mitochondrial antibodies in dilution of 1:160.

During the past 12 months, seizure activity, muscle cramping, and diarrhea recurred. The patient's seizures were controlled with valproic acid 3 g/day. Muscle fasciculations were observed in his upper extremities, and he was again directed to a nationally recognized referral center.

At age 28, the patient's height was 172 cm and his weight was 56.8 kg. Blood pressure and pulse were normal. The skin demonstrated alopecia totalis. Examination of the chest documented mild expiratory slowing, and the digits were thought to be mildly clubbed.

Extensive laboratory testing revealed decreased albumin (3.1 g/dL), mildly elevated aspartate aminotransferase (42 units/L), and significantly depressed serum cholesterol (105 mg/dL). Serum thyroxine, rheumatoid factor, and anti-DS-DNA were within normal range. The hematology profile revealed mild anemia with megaloblastic changes. The vitamin B₁₂ level was decreased at 260 ng/L. The prothrombin time was elevated at 14.9 seconds. Serum creatine kinase was 189 units/L (normal 23 to 99 units/L). A screen for heavy metals was normal. Examination of stool revealed excessive fat but no evidence of ova or parasites.

Chest roentgenography demonstrated extensive emphysematous changes in the upper lung fields with lower-lobe compression. An electrocardiogram was normal.

Electromyographic studies demonstrated both neuropathic and myopathic dysfunction. Biopsy of the sural nerve and surrounding muscle demonstrated a necrotizing myopathy with active and chronic denervation atrophy. An inflammatory response was present around the epineurial vessels. Electroencephalography showed mild generalized cerebral dysfunction with background slowing, but no lateralizing or epileptiform abnormalities were noted.

Small-bowel aspirates and biopsies showed no significant pathologic overgrowth. The small-bowel biopsy was inadequate for evaluation of villi but sufficient to rule out the presence of giardiasis. Colonoscopy with biopsies demonstrated only edema of the lamina propria.

Skin biopsies of the scalp showed lichenoid inflammation, and direct immunofluorescence biopsy revealed a weak zone of fluorescence with immunoglobulin G. These findings suggested lupus erythematosus.

DISCUSSION

No satisfactory unifying explanation of this young man's illness has been found. A sophisticated analysis of bronchoalveolar lavage fluid or an open-lung biopsy might provide additional insight into the etiology of the patient's condition; unfortunately, the patient and his family continue to refuse these investigations. However, some possible etiologies can be suggested.

Autoimmune etiologies

The early onset of bullous emphysema is not a well-documented sequela of autoimmune disturbances. Our patient suffers from erosive arthritis, myotonia, and cutaneous involvement; these features argue for an autoimmune stimulus for alveolar-capillary destruction, resulting in distal air-space enlargement. As a unifying hypothesis within current concepts of the pathogenesis of emphysema, we speculate that an immune complex may cause an imbalance of native lung proteases and antiproteases that allows proteolysis of connective tissue.

Immunoglobulins can promote lung destruction by increasing the amount of proteases (especially human leukocyte elastase) relative to the resident antiproteases. This phenomenon is seen when infection or environmental exposure activates alveolar macrophages that store human neutrophil elastase.¹

The presence of serum autoantibodies in patients with pneumonitis from autoimmune disease is well documented.² The autoantibody profile of such an individual differs from that of a similar patient with an autoimmune disorder without lung involvement. Unfortunately, the type and titer of antibody are not reliable predictors: serum markers remain nonspecific for the majority of autoimmune lung diseases.²

Circulating antibodies against endogenous tissue are found in a higher proportion of patients with significant alopecia than in the general population. These antibodies are most commonly directed against gastric parietal cells, thyroid tissue, endothelial cells, and smooth muscle.³ As may be expected by the presence of these serum markers, disorders of autoimmune pathogenesis occur with a greater frequency in patients with alopecia than would be expected by chance.⁴ However, respiratory disease, as seen in our patient, has not previously been described.

The anti-mitochondrial antibody is not usually found in patients with alopecia totalis or universalis, and its significant titer in our patient suggests a concomitant problem. Elevation of the anti-mitochondrial

TABLE
RESULTS OF SEROLOGIC TESTS

Alpha-1-antitrypsin	322 mg/dL (200-400 mg/dL)
Rheumatoid factor	Negative
Protein electrophoresis	Normal pattern
Serum aldolase	9 IU/L (1-8 IU/L)
Serum creatine phosphokinase	394 IU/L (38-174 IU/L)
Aldolase	6.5 IU/L (1-8 IU/L)
T-lymphocytes	2.6 (OKT4 1.6 + OKT8 1.0)
Testosterone	707 ng/dL (360-990 ng/dL)
Prolactin	6.8 ng/mL (0-15 ng/mL)
HIV-III antibody	Negative
Anti-smooth muscle antibody	<1:20
Anti-histone antibody	1:10
Anti-mitochondrial antibody*	
Maximum	1:160
Current	1:80
Anti-nuclear antibody*	
Maximum	1:640 Homogeneous pattern
Current	1:16

*These titers have varied during the course of the patient's disease.

antibody in nonhepatic illness occurs in less than 1% of the normal population,⁵ and some investigators speculate that a positive titer in an asymptomatic individual may be an early marker for the eventual development of primary biliary cirrhosis.⁶ Our patient's mild but persistent elevation of serum alkaline phosphatase, aspartate aminotransferase, and prothrombin time suggest some hepatic dysfunction; however, his age, history, and gender do not favor this diagnosis. Bullous emphysema has been reported in a patient with primary biliary cirrhosis, alpha-1-antitrypsin deficiency, and anti-mitochondrial antibodies.⁷

While a characteristic alpha-1-antitrypsin deficiency is not apparent in this patient, recent studies suggest that there may be mildly deficient antiprotease phenotypes that exaggerate superimposed immunologic and inflammatory lung responses.⁸ Whether the presence of antibodies in these mildly deficient phenotypes might result in pulmonary emphysema has not been established.

Another hypothesis is that a single antibody affects multiple organs. A cause-and-effect relationship between muscle disease and centri-acinar emphysema has been implied but not definitely established. An adult with extensive rod myopathy of the skeletal muscles was reported to have centriacinar emphysema on postmortem examination,⁹ and that case bears some similarity to the muscle and lung dysfunction occurring in our patient.

Sarcoidosis

Another possibility is the "vanishing lung syndrome" of giant bullae resulting from sarcoidosis.¹⁰ Sarcoidosis is a multisystem disease; its etiology is undetermined, but it is associated with autoimmune phenomena.¹¹ Giant bullae associated with sarcoidosis is very rare. It has been observed only in males and is usually an end-stage sequela of a chronic process; however, giant bullae and respiratory insufficiency have been reported in a young man with this disease without other apparent evidence of sarcoidosis.¹²

Congenital etiology

Our patient's condition may result from a congenital disorder. The hereditary occurrence of emphysematous bullae in the tight-skinned mouse with a normal complement of alpha-1-antitrypsin and multiple connective tissue abnormalities is an animal model of an autosomal-dominant mutation. Such a mutation might

be the basis for our patient's disease.¹³

Early-onset emphysema in humans with congenital disease and normal alpha-1-antitrypsin levels is also observed in Salla disease (an autosomal-recessive disorder of sialic acid metabolism),¹⁴ in the unusual familial idiopathic nonarteriosclerotic cerebral calcification syndrome (an autosomal inherited disorder),¹⁵ and in cutis laxa (a heritable elastin disorder).¹⁶ The diversity of organ involvement in our patient may represent a previously unrecognized congenital syndrome.

CONCLUSION

The explanation of this patient's early-onset bullous emphysema associated with autoimmune disturbance remains elusive; to elucidate the relationship between these disorders requires further study. To provide additional data, we encourage reporting of patients with similar conditions.

REFERENCES

1. Flenley DC, Downing I, Griening AP. The pathogenesis of emphysema. *Bull Eur Physiopathol Respir* 1986; **22**(Suppl):245-252.
2. Turner-Stokes L, Haslam P, Jones M, Dudeney C, Page SL, Isenberg D. Autoantibody and idiotype profile of lung involvement in autoimmune rheumatic disease. *Ann Rheum Dis* 1990; **49**:160-162.
3. Milgraum SS, Mitchell AJ, Bacon GE, Rasmussen JE. Alopecia areata, endocrine function and autoantibodies in patients 16 years of age or younger. *J Am Acad Dermatol* 1987; **17**:57-61.
4. Friedman PS. Alopecia and autoimmunity. *Br J Dermatol* 1981; **105**:153-157.
5. Triger DR, Charlton CAC, Ward AM. What does the anti-mitochondrial antibody mean? *Gut* 1982; **23**:814-818.
6. Munoz LE, Thomas HC, Scheuer PH, Doniach D, Sherlock S. Is the mitochondrial antibody diagnostic of primary biliary cirrhosis? *Gut* 1981; **22**:136-140.
7. Cars O, Stenram U, Stromberg A. Alpha₁-antitrypsin deficiency, mitochondrial antibodies and possible primary biliary cirrhosis. A case report and family study. *Ups J Med Sci* 1975; **80**:93-98.
8. Breit SN, Penny R. The role of alpha₁-protease inhibitor (alpha₁-antitrypsin) in the regulation of immunologic and inflammatory reactions. *Aust N Z J Med* 1980; **10**:449-453.
9. Dodson RF, Crisp GO Jr, Nicotra B, Munoz L, Albright CD. Rod myopathy with extensive systemic and respiratory muscular involvement. *Ultrastruct Pathol* 1983; **5**:129-133.
10. Miller A. The vanishing lung syndrome associated with pulmonary sarcoidosis. *Br J Dis Chest* 1981; **75**:209-214.
11. Zimmerman I, Mann N. Boeck's sarcoid—A case of sarcoidosis complicated by pulmonary emphysema and cor pulmonale. *Ann Intern Med* 1949; **31**:153-154.
12. Didier A, Legrand MF, Arlet-Suau, Leophonte P. Sarcoidosis and autoimmunity: apropos of 2 cases. *Rev Pneumol Clin* 1988; **44**:74-77.
13. Rossi GA, Hunninghake GW, Gadek JE, Szapiel SV, Kawanami O. Hereditary emphysema in the tight-skin mouse: evaluation of pathogenesis. *Am Rev Respir Dis* 1984; **129**:850-855.
14. Paako P, Ryhanen L, Rantala H, Auto-Harmainen H. Pulmonary emphysema in a nonsmoking patient with Salla disease. *Am Rev Respir Dis* 1987; **135**:979-982.
15. Kahn E, Markowitz J, Duffy L, Kenigsberg K, Davis JG, Daem F. Berry aneurysms, cirrhosis, pulmonary emphysema and bilateral symmetrical cerebral calcifications: a new syndrome. *Am J Med Genet* 1987; **3**(Suppl):343-356.
16. Turner-Stokes L, Thurton C, Pope FM, Green M. Emphysema and cutis laxa. *Thorax* 1983; **38**:790-792.