



# Atrial fibrillation and flutter with left bundle branch block aberration referred as ventricular tachycardia

RICHARD G. TROHMAN, MD; KENNETH M. KESSLER, MD; DEBORAH WILLIAMS, MD; AND JAMES D. MALONEY, MD

■ Five patients were referred for electrophysiologic evaluation of nonsustained or sustained ventricular tachycardia. In each patient, the clinical rhythm disturbance was reproduced and identified as atrial fibrillation or flutter with left bundle branch block aberrancy. All five patients demonstrated enhanced or accelerated atrioventricular conduction through the normal atrioventricular nodal-His Purkinje pathway. This rapid conduction created an electrophysiologic substrate suitable to the preferential development of this less common form of aberration. Four of five patients responded well (ventricular rate control or reversion to sinus rhythm) to verapamil therapy. Electrocardiographic criteria for differentiating supraventricular tachycardia with aberration from ventricular tachycardia exist. Nevertheless, misdiagnosis of wide complex tachycardia remains common. Electrophysiologic testing plays an important role in correctly identifying these rhythms, assessing long-term prognosis, and choosing effective therapy.

□ INDEX TERMS: LEFT BUNDLE BRANCH BLOCK ABERRANCY; ATRIAL FIBRILLATION AND FLUTTER □ CLEVE CLIN J MED 1991; 58:325-330

**E**LECTROCARDIOGRAPHIC criteria exist to aid in the differentiation of aberrantly conducted QRS complexes from complexes of ventricular origin during atrial fibrillation.<sup>1,2</sup> Additional electrocardiographic criteria aid in differentiating ventricular tachycardia from supraventricular tachycardia with aberration.<sup>3,5</sup> Aberration during atrial fibrillation or flutter is benign, and it has a right bundle branch block (RBBB) configuration in 80% of cases. Ventricular tachycardia is a potentially lethal arrhythmia requiring different and often much more aggressive treatment. Hence, the distinction be-

tween these rhythm disturbances is of obvious clinical importance. Our report describes the results of electrophysiologic testing in five patients referred for evaluation of ventricular tachycardia. In each instance, the clinical rhythm disturbance was proven to be supraventricular in origin—ie, atrial fibrillation or flutter with left bundle branch block (LBBB) aberration.

## METHODS

### Patient characteristics

The study group consisted of five adult patients (four men, one woman), ages 24 to 62, referred for evaluation of ventricular tachycardia (Table 1). Each had runs of wide QRS complex tachycardia of LBBB-type configuration, ranging in duration from five beats to sustained (greater than 30 seconds), and documented by surface electrocardiogram, ambulatory monitoring, or continuous bedside monitoring (Figure

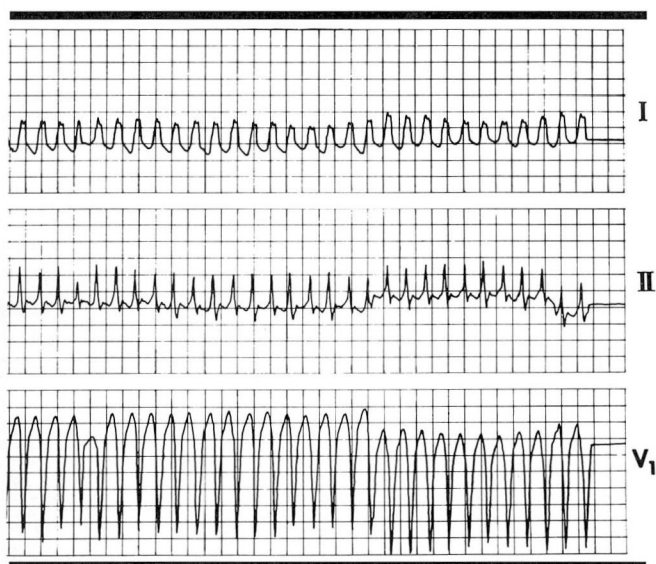
From the Department of Cardiology, The Cleveland Clinic Foundation (R.G.T., D.W., J.D.M.), and the Miami VA Medical Center (K.M.K.).

Address reprint requests to R.G.T., Electrophysiology and Pacing Section, Department of Cardiology, F15, The Cleveland Clinic Foundation, One Clinic Center, 9500 Euclid Avenue, Cleveland, Ohio 44195.

**TABLE 1**  
PATIENT CHARACTERISTICS

Patient	Age/sex	Baseline electrocardiogram	Echocardiography	Etiology of underlying heart disease	Reason for referral
1	24,F	Nonspecific ST changes	Slight biventricular dilatation	Unknown	NSVT
2	50,M	Normal sinus rhythm, left axis deviation, nonspecific ST changes	Left atrial enlargement, diffuse left ventricular hypokinesis	Ethanol	VT
3	62,M	Left atrial enlargement	Left ventricular hypertrophy	Ethanol, hypertension	VT
4	62,M	Old inferior myocardial infarction, nonspecific ST changes	Technically suboptimal normal ejection fraction	Coronary artery disease	NSVT
5	62,M	Atrial fibrillation, old anteroseptal myocardial infarction	Dilated left ventricle with decreased ejection fraction	Coronary artery disease	NSVT

NSVT = nonsustained ventricular tachycardia.  
VT = sustained ventricular tachycardia.



**Figure 1.** Rhythm strip demonstrates sustained left bundle branch block aberration (Patient 3). Electrophysiologic testing revealed atrial flutter with a rapid ventricular response and left bundle branch block aberrancy (surface electrocardiographic leads I, II, and V<sub>1</sub>).

1). One patient had biventricular enlargement of uncertain etiology. The left ventricular ejection fraction was within normal limits. Two patients had coronary artery disease with documented myocardial infarction, one of whom had ventricular fibrillation at the time of acute infarction. Two patients had histories of ethanol abuse, one with markedly reduced left ventricular function and a history of congestive heart failure, the other with normal left ventricular function by echocardiog-

raphy. Left ventricular hypertrophy was present by both electrocardiographic and echocardiographic criteria in the latter patient. Baseline electrocardiography demonstrated narrow QRS complexes in all five patients. Sinus rhythm was present in four patients; one had chronic atrial fibrillation.

### Electrophysiologic testing

Electrophysiologic studies were performed in the sedated (oral diazepam or intramuscular pentobarbital sodium [Nembutal]) postabsorptive state, with the patient taking no cardioactive medications. Three quadripolar catheters were inserted percutaneously and positioned to record high right atrial, His bundle, and right ventricular apical electrograms. In two patients, a fourth quadripolar catheter was inserted percutaneously into the coronary sinus.

Incremental pacing and programmed atrial stimulation were performed in the four patients with normal sinus rhythm. Incremental pacing and up to three extra-stimuli were delivered to the right ventricular apex and outflow tract. Rapid right atrial pacing was used to induce atrial fibrillation or flutter.

### RESULTS

#### Replication of clinical rhythm disturbance

Ventricular tachycardia was not inducible in any of the five patients. None of the patients demonstrated either atrioventricular (AV) nodal reentry or circus movement tachycardia involving a manifest or concealed accessory pathway. Atrial fibrillation or flutter with reproduction of the clinical LBBB morphology

**TABLE 2**  
ELECTROPHYSIOLOGIC DATA, RESPONSES TO PHARMACOLOGIC INTERVENTION

Patient	Baseline AH	Change in AH	Shortest CL 1:1 AV conduction	Arrhythmia	Response to verapamil
1	60	80	300	Atrial flutter, ventricular rate up to 300, LBBB aberration	120 mg tid orally decreased ventricular rate to 130
2	75	50	350*	Atrial fibrillation, ventricular rate 200, LBBB aberration	10 mg IV decreased ventricular rate to 130
3	40	55	280	Atrial flutter, ventricular rate 180, LBBB aberration	No change with oral or IV
4	80	180	300	Atrial fibrillation and flutter, ventricular rate 150–190, LBBB aberration	5 mg IV produced prompt reversion to sinus rhythm
5	—†	—†	—†	Atrial fibrillation, ventricular rate 200, LBBB aberration	10 mg IV decreased ventricular rate to 80

Baseline AH = atrio-His interval in msec, measured in the His bundle electrogram.

Change in AH = change between AH measured during sinus rhythm and AH measured during the shortest cycle achieving 1:1 AV conduction.

CL = cycle length.

LBBB = left bundle branch block.

\* = right atrial pacing at shorter cycle lengths not attempted because of tachycardia induction.

† = conduction interval not measured because baseline rhythm was atrial fibrillation.

was inducible (or present at baseline) in all five patients (Table 2, Figures 2 and 3).

### Patterns of AV conduction

There was no evidence of preexcitation in any of these patients. The crucial electrophysiologic link between them was rapid conduction via the normal pathway. All patients achieved ventricular rates greater than or equal to 200 beats per minute via conduction through the AV nodal-His Purkinje system during rapid atrial pacing or tachycardia (Figure 4).

### Coexistence of RBBB aberration

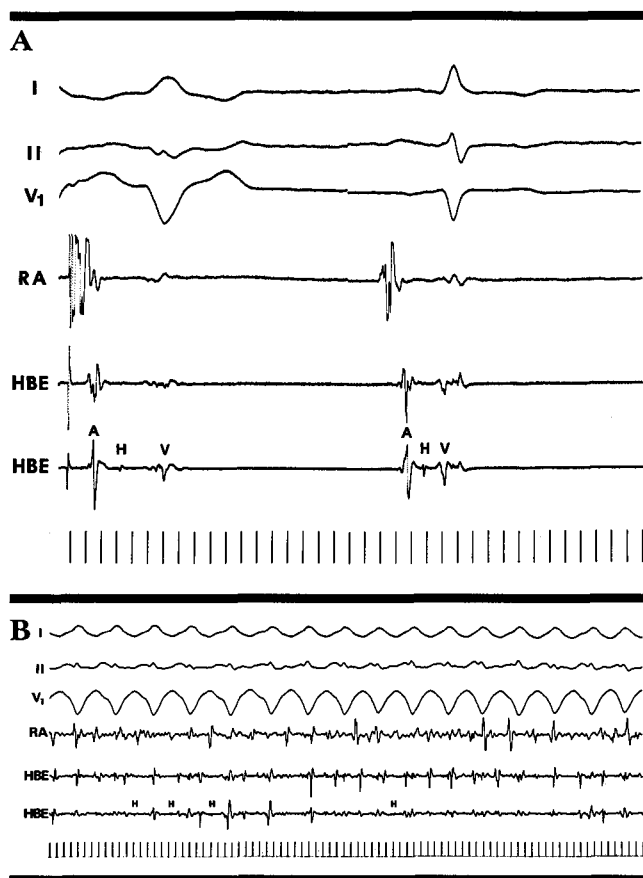
Clinical and electrocardiographic observation has suggested that LBBB aberration usually coexists with RBBB aberration.<sup>1</sup> RBBB-type beats were observed clinically (single beats only) and electrophysiologically in only two of our five patients.

### Response to therapeutic intervention

Verapamil has been suggested as a drug of choice for prompt slowing of rapid ventricular rates that occur in patients with rapid AV nodal conduction.<sup>6,7</sup> Dramatic improvement occurred after intravenous or oral verapamil therapy in four of our five patients. The fifth patient did not respond to intravenous (10 mg) or oral (80 mg four times daily) verapamil.

### DISCUSSION

RBBB aberrancy is four times more common than LBBB. Thus, runs of aberration with LBBB configuration are more often misinterpreted as paroxysmal ventricular tachycardia. Electrophysiologic testing differentiates LBBB aberration from ventricular tachycardia. This requires a stable, sharp His bundle recording, and careful determination of the HV interval during sinus rhythm, and/or narrow complex tachycardia. The His bundle recording (Figure 2) is comprised of two contiguous segments: The AH interval measures conduction time from low septal right atrium to His bundle; it primarily reflects conduction velocity through the AV node. The HV interval is measured from the onset of the His bundle deflection to the earliest ventricular depolarization; it reflects infranodal conduction velocity. Supraventricular ectopic beats will have HV intervals equal to or exceeding (infranodal conduction delay) the HV interval measured during sinus rhythm. Ventricular ectopic beats do not require prior depolarization of the His-Purkinje system to propagate. HV intervals will be absent or less than the HV measured during sinus rhythm. Wide complex tachycardias with HV intervals less than those recorded during sinus rhythm or narrow complex tachycardia are ventricular in origin. Wide

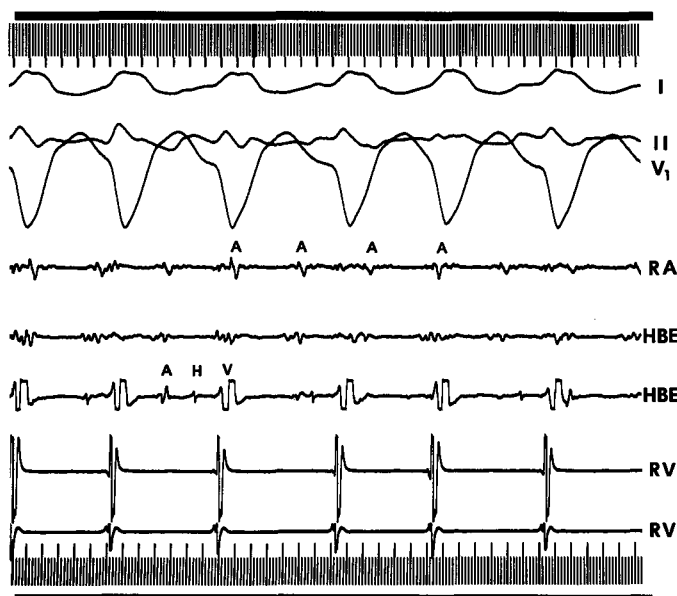


**Figure 2.** A) During right atrial pacing (beat shown on the left), left bundle branch block aberration with an HV interval measured to be 75 milliseconds was demonstrated in Patient 2. The normal sinus beat (strip is not continuous) has an HV interval of 50 milliseconds. B) Electrophysiologic testing revealed sustained atrial fibrillation with identical left bundle branch aberration induced by right atrial pacing at a cycle length of 350 milliseconds. Average ventricular rate was 200 beats per minute. The HV interval again measured 75 milliseconds. (I, II, and V1 surface electrocardiographic leads I, II, and V1. RA = right atrial electrogram. HBE = His bundle electrogram. HV interval measured from the His bundle deflection to the earliest ventricular activity [surface electrocardiogram or intracardiac recordings].)

complex tachycardias with HV intervals equal to or greater than those during sinus rhythm or narrow complex tachycardia are supraventricular in origin.

### Mechanisms of aberration

Enhanced AV nodal conduction is defined as follows: AH intervals during sinus rhythm of less than or equal to 60 ms; 1:1 conduction between the atrium and His bundle at right atrial pacing cycle lengths of less



**Figure 3.** Atrial flutter with 2:1 atrioventricular block and left bundle branch block aberration was induced in Patient 4, who had been referred for runs of nonsustained ventricular tachycardia. (I, II, and V1 = surface electrocardiographic leads. RA = right atrial electrogram. HBE = His bundle electrogram, RV = right ventricular electrogram.)

than 300 ms; and less than 100 ms difference between the AH interval measured during sinus rhythm and right atrial pacing at 300 ms was present in two patients.<sup>8</sup> These criteria could not be assessed in one patient with chronic atrial fibrillation. The other two patients were felt to have "accelerated" AV conduction.<sup>9</sup> Jackman et al<sup>10</sup> have shown that neither the baseline AH interval nor the change in AH interval with right atrial pacing is particularly useful in defining a subgroup of patients with rapid AV conduction. They found that the ventricular rate recorded during atrial fibrillation correlates highly with the shortest 1:1 cycle length during right atrial pacing. Thus no important distinction between our patients' conduction patterns was present. This rapid conduction pattern created the milieu essential to the preferential development of LBBB aberrancy.

Preferential development of LBBB aberrancy is best explained by the response of the bundle branches to rapid ventricular rates and the clinical features of tachycardia-dependent aberration.

At slow heart rates, the refractory period of the right bundle branch usually exceeds that of the left bundle branch.<sup>11,12</sup> At faster rates, the refractory



period of the left bundle branch may exceed that of the right bundle branch.<sup>11,12</sup> In our patients, fast ventricular rates occurred in association with rapid AV nodal conduction.

Tachycardia-dependent aberration may occur at critical heart rates. This phase III aberration exhibits a predominance of LBBB morphology. Development of phase III aberration is independent of the immediately preceding cycle length and occasionally appears with no, or only a slight, change in cycle length. These features differ from the usual RBBB aberrancy related to the Ashman phenomenon. Rate-dependent aberrancy generally appears at relatively slow heart rates, but may make its initial appearance at very rapid rates and is seen almost exclusively in patients with heart disease.<sup>13</sup> Our five patients had structural cardiac abnormalities. Rate-dependent aberrancy is not a common mechanism of wide QRS tachycardia. In the presence of structural heart disease, wide complex tachycardia is almost always ventricular in origin.<sup>5</sup>

In atrial fibrillation and flutter, several features contribute to persistent aberrancy at R-R intervals longer than the interval initiating aberrancy. The most important mechanism is concealed antegrade penetration of the blocked bundle branch. This results in true bundle branch depolarizations that are shorter than manifest R-R intervals. Less important roles are played by concealed transseptal activation (with block of conduction in the contralateral bundle) and time-dependent aberrancy.<sup>13</sup>

### Electrocardiographic correlates and limitations

Electrocardiographic criteria have been described to differentiate ventricular tachycardia from supraventricular tachycardia with aberration.<sup>3,4</sup> Kindwall et al<sup>4</sup> have described four criteria suggesting a ventricular origin in LBBB tachycardia: 1) an R wave in V<sub>1</sub> or V<sub>2</sub> greater than 30 ms in duration; 2) the presence of any Q wave in V<sub>6</sub>; 3) notching on the S wave downstroke in V<sub>1</sub> or V<sub>2</sub>; 4) greater than 60 ms from the onset of the QRS to the nadir of the S wave in V<sub>1</sub> or V<sub>2</sub>.

Most ventricular tachycardias have rates between 130 and 170 beats per minute and QRS durations exceeding 0.14 seconds (0.16 sec for LBBB morphology ventricular tachycardia). Four of our five patients had ventricular rates exceeding 170 beats per minute. Four patients had QRS widths during tachycardia of less than 0.14 seconds. Use of additional QRS characteristics was limited by the fact that three of our patients had nonsustained arrhythmias. When a 12-lead electrocardiogram recorded during tachycardia

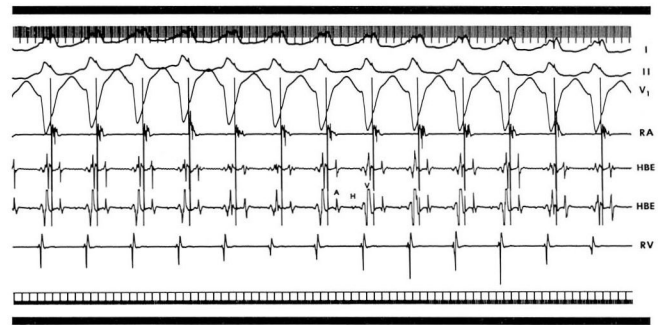


Figure 4. Atrial pacing at a cycle length of 300 milliseconds resulting in 1:1 atrioventricular conduction and left bundle branch block aberration (Patient 1).

was available, QRS characteristics supported a supraventricular origin for the tachycardias (Figure 1, lead V<sub>1</sub>). One patient had runs of narrow complex irregularly irregular tachycardia preceding wide complex beats. Although some electrocardiographic criteria suggested supraventricular origins for these tachycardias, confirmation required intracardiac electrophysiologic studies.

### Prognostic and therapeutic implications

Sustained ventricular tachycardia is a life-threatening rhythm. Aggressive therapy guided by electrophysiologic testing decreases mortality. Pharmacotherapy is often insufficient to control sustained ventricular tachycardia and surgical intervention may be required (subendocardial resection or use of an implantable cardioverter defibrillator). Nonsustained ventricular tachycardia is a potentially lethal arrhythmia and is associated with an increased risk of sudden cardiac death in patients with underlying heart disease.<sup>14</sup> Appropriate management of asymptomatic nonsustained ventricular tachycardia remains uncertain. Cardiac Arrhythmia Suppression Trial data<sup>15</sup> provide evidence that pharmacotherapy with the Type IC drugs encainide and flecainide increases mortality.

The hemodynamic effects of atrial tachyarrhythmias correlate with ventricular rate and myocardial reserve. In general, paroxysmal atrial fibrillation and flutter are not associated with sudden cardiac death. Rapid ventricular rates occurring abruptly in patients with serious cardiac disease may be devastating. However, when ventricular rates are well-controlled, these rhythm disturbances are compatible with years of uneventful survival, and contribute little to the morbidity and mortality of heart disease.<sup>16</sup>

Therapy of atrial flutter and fibrillation is initially

directed at AV nodal blockade (controlling ventricular rate). Digitalis, beta blockers, and verapamil (or combinations of these agents) usually achieve AV nodal blockade. The restoration and maintenance of sinus rhythm correlates inversely with the duration of the arrhythmia and left atrial size. Type IA antiarrhythmics are most frequently employed to control the atrial rhythm disturbance. Flecainide may also be used with efficacy similar to quinidine.<sup>17</sup>

Pharmacotherapy is well-defined and effective for atrial fibrillation and flutter. Antiarrhythmic drug

management of ventricular tachycardia is ill-defined, frequently ineffective, and fraught with the risk of proarrhythmia.

In our patients, response to pharmacologic intervention was greatly influenced by the supraventricular origin of the arrhythmias. Verapamil resulted in improvement in four patients and had no effect on one patient. This result is in contrast to drug therapy ventricular tachycardia, where serial drug testing may fail to achieve arrhythmia control and intravenous verapamil may produce hemodynamic collapse.<sup>18,19</sup>

## REFERENCES

- Cohen SI, Lau SH, Haft JJ, Damato AN. Experimental production of aberrant ventricular conduction in man. *Circulation* 1967; **36**:673-685.
- Sandler IA, Marriott HJL. The differential morphology of anomalous complexes of RBBB-type in lead V1: Ventricular ectopy versus aberration. *Circulation* 1965; **31**:551-556.
- Wellens HJJ, Bar FWHM, Lie KI. The value of the electrocardiogram in the differential diagnosis of a tachycardia with a widened QRS complex. *Am J Med* 1978; **64**:27-33.
- Kindwall KE, Brown J, Josephson ME. Electrocardiographic criteria for ventricular tachycardia in wide complex left bundle branch block morphology tachycardias. *Am J Cardiol* 1988; **61**:1279-1283.
- Akhtar M, Shenasa M, Jazayeri M, Caceres J, Tchou PJ. Wide QRS complex tachycardia Reappraisal of a common clinical problem. *Ann Intern Med* 1988; **109**:905-912.
- Castellanos A, Zaman L, Luceri RM, Myerburg RJ. Arrhythmias in patients with short PR intervals and narrow QRS complexes. In: Josephson ME, Wellen HJJ, eds. *Tachycardias: Mechanisms, diagnosis, treatment*. Philadelphia: Lea and Febiger; 1984:171-198.
- Bigger JT. Perspectives on the current treatment of cardiac arrhythmias. *Am J Cardiol* 1984; **54**:2B-7B.
- Stafford WJ, Trohman RG, Bilsker M, Zaman L, Castellanos A, Myerburg RJ. Cardiac arrest in an adolescent with atrial fibrillation and hypertrophic cardiomyopathy. *J Am Coll Cardiol* 1986; **7**:701-704.
- Holmes DR, Hartzler GO, Meredith J. The clinical and electrophysiologic characteristics of patients with accelerated atrioventricular nodal conduction. *Mayo Clin Proc* 1982; **57**:339-344.
- Jackman WM, Prystowsky EN, Naccarell GV, et al. Reevaluation of enhanced atrioventricular nodal conduction: Evidence to suggest a continuum of normal atrioventricular nodal physiology. *Circulation* 1983; **67**:441-447.
- Myerburg RJ, Stewart JW, Hoffman BF. Electrophysiologic properties of the canine peripheral A-V conducting system. *Circ Res* 1970; **26**:361-378.
- Chilson DA, Zipes DP, Heger JJ, Browne KF, Prystowsky EN. Functional bundle branch block: Discordant responses of the right and left bundle branches to changes in heart rate. *Am J Cardiol* 1984; **54**:313-316.
- Fisch C, Zipes DP, McHenry PL. Rate dependent aberrancy. *Circulation* 1973; **38**:714-724.
- Bigger JT. Identification of patients at high risks for sudden cardiac death. *Am J Cardiol* 1984; **54**:3D-8D.
- The Cardiac Arrhythmia Suppression Trial (CAST) Investigators. Preliminary Report: Effect of encainide and flecainide on mortality in a randomized trial of arrhythmia suppression after myocardial infarction. *New Engl J Med* 1989; **321**:406-412.
- Bigger JT. Mechanisms and diagnosis of arrhythmias. In: Braunwald E, ed. *Heart Disease*. 1st ed. Philadelphia: WB Saunders. 1980: 630-690.
- Borgeat A, Goy JJ, Maendly R, Kaufmann U, Grbic M, Sigwart U. Flecainide versus quinidine for conversion of atrial fibrillation to sinus rhythm. *Am J Cardiol* 1986; **58**:496-498.
- Dancy M, Camm AJ, Ward D. Misdiagnosis of chronic recurrent ventricular tachycardia. *Lancet* 1985; **11**:320-323.
- Buxton AE, Marchlinski FE, Doherty JU, Flores B, Josephson ME. Hazards of intravenous verapamil for sustained ventricular tachycardia. *Am J Cardiol* 1987; **59**:1107-1110.