

MOULAY A. MEZIANE, MD, EDITOR

Left atrial lesion in a 68-year-old

CATHRYN POWERS, MD AND KATHLEEN GLEASON BEAVIS, MD

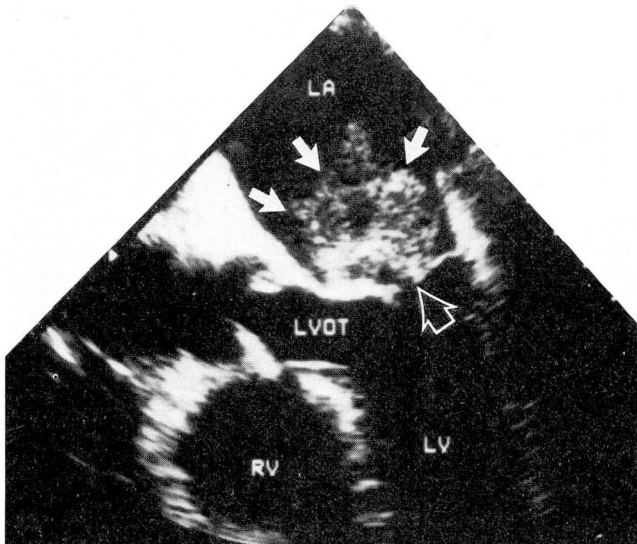


FIGURE 1. A two-dimensional echocardiogram obtained transesophageally, showing a large multilobulated lesion (solid arrows) of the left atrium abutting the mitral valve (open arrow). (RV, right ventricle; LV, left ventricle; LVOT, left ventricular outflow tract; LA, left atrium.)

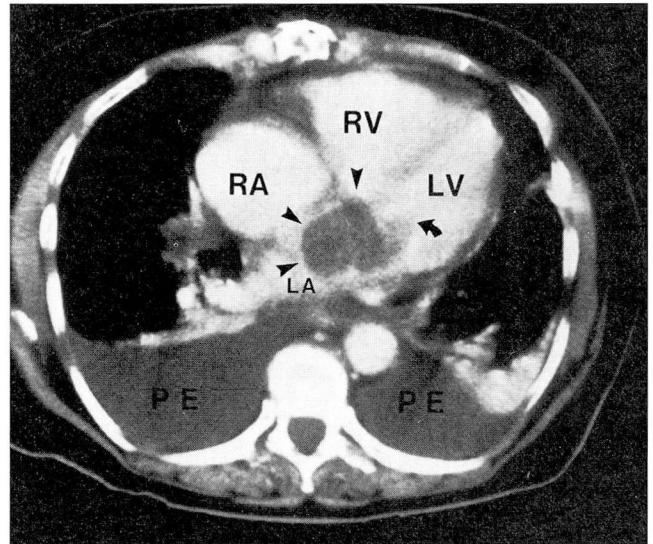


FIGURE 2. CT scan during bolus administration of intravenous contrast material, showing a 5- x 5-cm nonenhancing soft tissue lesion (arrow heads) of the left atrium extending through the mitral valve (curved arrow). Also note bilateral pleural effusions. (RA, right atrium; RV, right ventricle; LV, left ventricle; LA, left atrium; PE, pleural effusion.)

A 68-year-old woman presented with shortness of breath, orthopnea, paroxysmal nocturnal dyspnea, and lower-extremity edema. Three months earlier, she had un-

dergone resection of a left atrial lesion. A two-dimensional echocardiogram obtained transesophageally demonstrated a large multilobulated lesion of the left atrium abutting the mitral valve (*Figure 1*). Computed tomography (CT) scanning during bolus administration of intravenous contrast material demonstrated a 5- x 5-cm nonenhancing soft tissue lesion of the left atrium extending through the mitral valve (*Figure 2*). Bilateral pleural effusions were also noted.

From the Departments of Diagnostic Radiology (C.P.) and Pathology (K.G.B.), The Cleveland Clinic Foundation.

Address reprint requests to Moulay A. Meziane, MD, The Cleveland Clinic Foundation, One Clinic Center, 9500 Euclid Avenue, Cleveland, Ohio 44195.

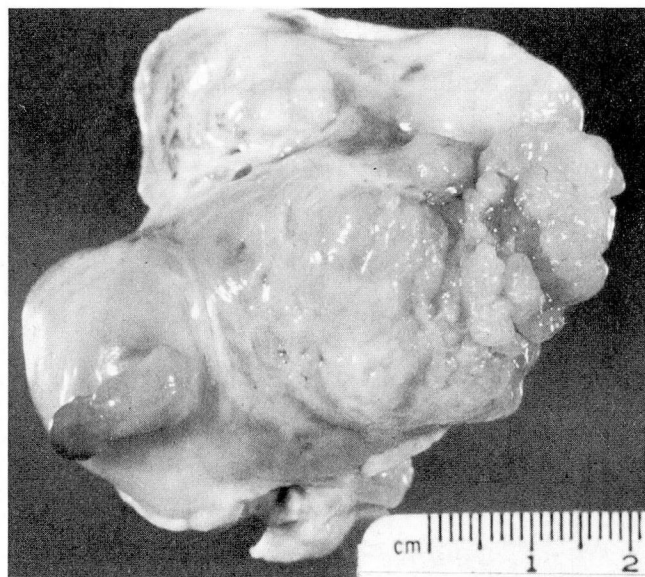


FIGURE 3. Recurrent malignant fibrous histiocytoma resected from the left atrium. The tan, glistening, multilobulated surface is uncharacteristic of other primary cardiac tumors such as myxoma or angiosarcoma.

DIAGNOSIS: RECURRENT LEFT ATRIAL
MALIGNANT FIBROUS HISTIOCYTOMA

Due to radiologic evidence of recurrence of the previously resected left atrial mass, a diagnosis of recurrent malignant fibrous histiocytoma (MFH) was made, and the patient underwent resection of the lesion. The specimen obtained was a 5.0- x 4.5- x 2.3-cm piece of firm, tan, glistening, fibrous tissue weighing 25 grams (Figure 3). A preliminary diagnosis of sarcoma was made during frozen section consultation, and the final diagnosis of recurrent MFH was established.

During resection of the left atrial mass, unresectable invasion of the left ventricle was noted. Ifosfamide/mesna/cisplatin chemotherapy was begun postoperatively, and the patient presented 10 months later with worsening cardiac failure. Axial T1-weighted spin echo gated magnetic resonance imaging of the heart (Figure 4) showed further spread of tumor to the pericardium and left hemithorax. Palliative radiation therapy of 3,600 rads to the heart and left hemithorax was administered over 4 weeks. The patient expired 17 months after the initial diagnosis.

DISCUSSION

This case involved the recurrence of a similar-sized

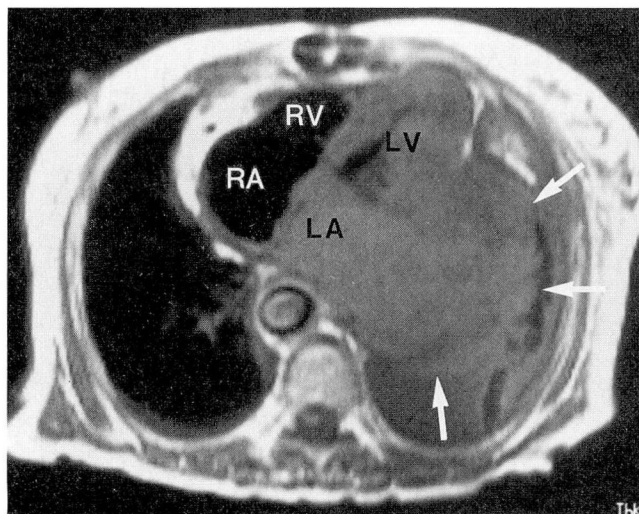


FIGURE 4. Magnetic resonance imaging of the heart (TR=728 msec, TE=22 msec) obtained 13 months after initial diagnosis demonstrated a tumor infiltrating the left atrium and left ventricle, extending through the pericardium into the left hemithorax (arrows). (RA, right atrium; LA, left atrium; RV, right ventricle; LV, left ventricle; TR, repetition time; TE, echo time.)

(5.3- x 5.0- x 2.7-cm) MFH removed only 3 months earlier. Sectioning of these tumors revealed circumscribed, bulging, whorled, fibrous areas with tan, white, and red discolorations. Microscopic examination showed a mixed pattern; some areas exhibited a myxoid hypocellular background with only occasionally reactive spindle cells and without necrosis or mitoses (Figure 5). In contrast, other areas showed the denser storiform-pleomorphic pattern, with atypical cells and large hyperchromatic nuclei characteristically seen in MFH (Figure 5).

MFH has five subtypes: storiform-pleomorphic, myxoid, giant cell, inflammatory, and angiomatoid. The majority of these lesions are storiform-pleomorphic; about 25% are of the myxoid subtype.¹ The neoplasm presented here was of the myxoid type. It featured prominent myxomatous areas combined with storiform-pleomorphic areas. The myxomatous areas can be a source of confusion at frozen section diagnosis; it is not uncommon to make an initial diagnosis of atrial myxoma, and to recognize that the tumor is an MFH only after extensive sampling.^{2,3}

MFH is of uncertain histogenesis, but the cells characteristic of this mass (mesenchymal cells, histiocytes, fibroblasts, and myofibroblasts) were identified in the first specimen by electron microscopy.

Primary cardiac tumors are rare, with an incidence of less than 0.03% from autopsy series.⁴ More than 95% of all cardiac tumors are metastatic, from carcinomas, melanomas, and hematologic malignancies. Of the primary cardiac tumors, about two thirds are benign, and the majority of these are myxomas.⁵ Of the primary malignant cardiac tumors, angiosarcoma and MFH are seen most commonly.

The first case of primary cardiac MFH was reported in 1978,³ and the literature contains at least 19 subsequent reports, 8 of them from Japan.^{6,7} In 9 of 10 cases with information available,^{5,7} the tumor presented in the left atrium, either on the septum or posterior wall. In 6 of 10 cases, the patients were under age 38; resected tumors generally recurred within the year, and the tumor was ultimately fatal in all cases.

In the evaluation of a patient with a suspected intracardiac mass, two-dimensional echocardiography is the primary screening technique. Advantages include its noninvasive nature, lack of ionizing radiation, low cost, and excellent temporal resolution with demonstration of the mobility of pedunculated tumors. Limitations include its inability to adequately image all patients due to factors such as chest wall thickness and pulmonary hyperinflation, and its inability to evaluate extracardiac spread of disease.⁸⁻¹¹ Recent advances in transesophageal technique may lessen the difficulty in imaging patients with obesity and hyperinflation.

Contrast-enhanced CT utilizing a bolus injection technique and short scan times can complement two-dimensional echo in the evaluation of intracardiac masses. The differentiation of a thrombus from a tumor within the left atrium is difficult with two-dimensional echo, whereas contrast-enhanced CT can detect a thrombus as a focal mass with an attenuation different to blood and myocardium, with smooth or discrete angulated margins, and with an origin usually along the posterior wall or in the atrial appendage. But the major advantage of CT over two-dimensional echo lies in its evaluation of the extent of disease, demonstrating the direct invasion of myocardium, pericardium, or mediastinum, neoplastic pulmonary emboli secondary to right-sided tumors, and invasion of adjacent vessels.⁹

Multiplanar cardiac gated magnetic resonance imaging can yield important diagnostic information affecting clinical management and surgical planning in patients with suspected cardiac masses, and it has an important role in the exclusion of false-positive two-dimensional echoes. Advantages of magnetic resonance imaging include providing a global view of

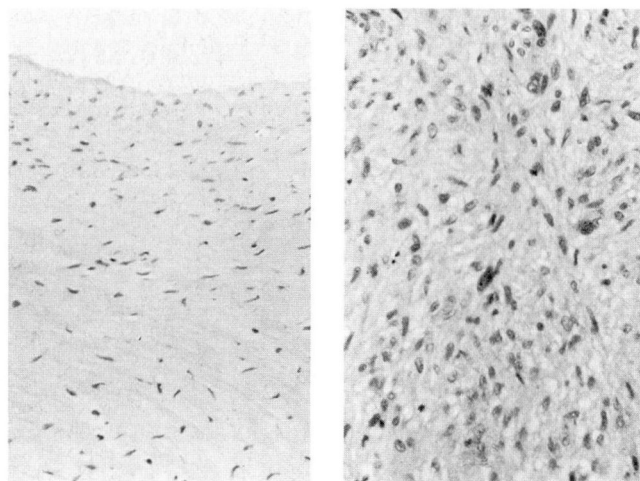


FIGURE 5. Photomicrographs illustrate the variable histologic appearances of MFH. The bland hypocellularity of the surface (left, hematoxylin-eosin, x 10) could lead to a diagnosis of myxoma if additional areas are not sampled. In contrast, the storiform-pleomorphic area with hyperchromatic nuclei (right, hematoxylin-eosin, x 20) is more characteristic of MFH.

cardiac anatomy in multiple planes, distinguishing flowing blood from soft tissue and thrombus, cinematic display, and excellent spatial resolution in the evaluation of disease extension.¹⁰

The imaging characteristics of MFH of the heart have been infrequently described in the literature due to its extremely rare incidence. Most have presented as a cardiac mass arising from the posterior wall of the left atrium as demonstrated by two-dimensional echo. As benign atrial myxoma also arises from the left atrium and has a similar clinical presentation, differentiation between a malignant tumor and myxoma is helpful for clinical management and essential for surgical planning. In two cases of primary left atrial MFH, cardiac magnetic resonance imaging accurately demonstrated extension into the pulmonary veins in both patients, and mediastinal extension in one patient which indicated the malignant nature of the disease process. The magnetic resonance signal characteristics were of non-specific intracardiac soft tissue masses, arising from the posterior wall of the left atrium, demonstrating slightly heterogeneous intermediate signal intensity on T1-weighted images and high signal intensity on T2-weighted images.¹¹ Specific CT findings of cardiac MFH have not been described.

The most common presenting symptoms in patients with cardiac tumors are dyspnea, orthopnea, or

paroxysmal nocturnal dyspnea, as occurred in this patient. The symptoms of heart failure may be paroxysmal and may be precipitated by a change in position. The location of the tumor and the degree of myocardial involvement may cause symptoms which indicate chamber obstruction and which mimic a valvular lesion, or may cause arrhythmias and murmurs. Non-cardiac manifestations include embolic disease, fever,

malaise, hematologic abnormalities that suggest chronic disease or infection, and arthralgias. Although unsuspected cardiac tumors are often discovered during the evaluation of patients with symptoms of valvular disease, the clinician should be highly suspicious of a cardiac tumor in the patient who presents with coexisting cardiac, embolic, and constitutional manifestations.^{5,7}

REFERENCES

1. Enzinger FW, Weiss SW. Soft tissue tumors. St. Louis: The C.V. Mosby Co., 1988:273.
2. Weiss SW, Enzinger FW. Myxoid variant of malignant fibrous histiocytoma. *Cancer* 1977; **39**:1672-1685.
3. Shah AA, et al. Malignant fibrous histiocytoma of the heart presenting as an atrial myxoma. *Cancer* 1978; **42**:2466-2471.
4. Smith C. Tumors of the heart. *Arch Pathol Lab Med* 1986; **110**:371-374.
5. Laya MB, et al. Malignant fibrous histiocytoma of the heart: a case report and review of the literature. *Cancer* 1987; **59**:1026-1031.
6. Rose AG, et al. Malignant fibrous histiocytoma of the heart: a case report. *S Afr Med J* 1988; **74**:418-420.
7. Bear PA, Moodie DS. Malignant primary cardiac tumors: the Cleveland Clinic experience, 1956-1986. *Chest* 1987; **92**:860-862.
8. Go RT, O'Donnell JK, Underwood DA, et al. Comparison of gated cardiac MRI and 2D echocardiography of intracardiac neoplasms. *AJR* 1985; **145**:21-25.
9. Gross BH, Glazer GM, Francis IR. CT of intracardiac and intrapericardial masses. *AJR* 1983; **140**:903-907.
10. Lund JT, Ehman RL, Julsrud PR, et al. Cardiac masses: assessment by MR imaging. *AJR* 1989; **152**:469-473.
11. Kim EE, Wallace S, Abello R, et al. Malignant cardiac fibrous histiocytomas and angiosarcomas: MR features. *J Comput Assist Tomogr* 1989; **13**:627-632.

