



Dog heartworm causing necrotizing granuloma of the lung

JOSE I. DIAZ, MD; LEOPOLDO H. LADAGA, MD; MARIA CUNDIFF, MD; JAMES BAKER, MD

■ Pulmonary dirofilariasis was diagnosed in a 70-year-old woman by tissue examination after she underwent a right thoracotomy. The preliminary clinical diagnosis was pulmonary coin lesion of probable neoplastic nature. Pulmonary dirofilariasis, caused by the dog heartworm, is occurring with increased frequency in the United States and must be considered in the differential diagnosis of pulmonary coin lesions. We describe the clinicopathological features of this case with special emphasis on the gross examination of the specimen.

□ INDEX TERMS: DOG HEARTWORM; PULMONARY DIROFILARIASIS □ CLEVE CLIN J MED 1991; 58:39-42

PULMONARY dirofilariasis is an infection caused by the nematode *Dirofilaria immitis*, the dog heartworm. Most cases of pulmonary dirofilariasis are initially misdiagnosed because of its striking radiologic resemblance to primary bronchogenic carcinoma or metastatic tumor. Serologic tests are not useful, so the pathologist's role in diagnosis is crucial. The parasite may be overlooked in both gross and histologic examinations. This potential diagnostic pitfall can be overcome by giving special attention to the histologic evaluation of a wedge resection of lung. The gross examination should include a search for white filaments with which the necrotic worm is embedded in tissue.

The first case reported in the American literature

was attributed to Dashiell¹ in 1961. Since then several reviews have been published by Dayal and Neafie² in 1975, Robinson and colleagues³ in 1977, Ciferri⁴ and Tsung and coworkers⁵ in 1982, and Ro and associates⁶ in 1989.

We report a case of pulmonary dirofilariasis and review the histopathologic features and the appropriate clinical management.

CASE REPORT

A 70-year-old woman was admitted to Sentara Norfolk-General Hospital in Norfolk, Va., for diagnostic evaluation of a right lower lobe nodule. One year before admission the patient had refused surgery and elected to be monitored by radiographs. After 1 year of observation, a slight progressive increase in the size of the nodule was documented, and the patient consented to a thoracotomy. She had always been in good health with no history of cough, sputum production, hemoptysis, chest pain, dyspnea, weight loss, or fever. She had smoked 1½ packs of cigarettes per day for the past 55 years.

From the Department of Pathology, The Cleveland Clinic Foundation (J.I.D.); and the Departments of Pathology (L.H.L., M.C.) and Internal Medicine (J.B.), Sentara-Norfolk General Hospital, Eastern Virginia Medical School, Norfolk, Va.

Address reprint requests to J.I.D., Department of Pathology, The Cleveland Clinic Foundation, One Clinic Center, 9500 Euclid Avenue, Cleveland, OH 44195.

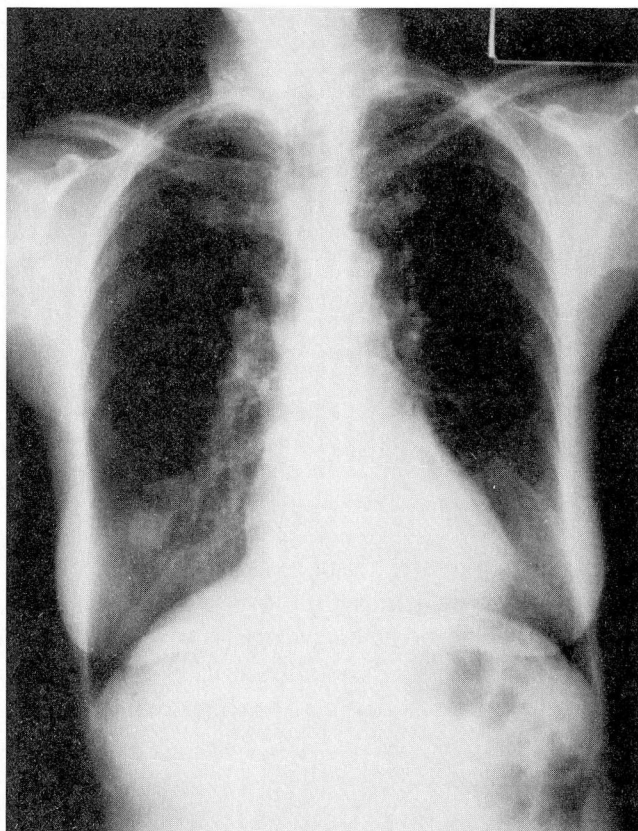


FIGURE 1. Chest radiograph demonstrating a solitary coin lesion in the lower lobe of the right lung.

Physical examination and laboratory data on admission were unremarkable. Pulmonary function tests demonstrated a moderate obstructive defect. A chest radiograph (Figure 1) and computerized tomographic scan showed a noncalcified nodule about 2 cm in diameter in the posterior aspect of the right lower lobe. No evidence of mediastinal involvement was demonstrated. The patient underwent a right thoracotomy and wedge resection of the nodule. After an uncomplicated postoperative course, she was discharged.

PATHOLOGIC FINDINGS

The specimen consisted of a wedge-shaped portion of lung parenchyma measuring $6 \times 2.5 \times 2.5$ cm. The pleural surface was smooth. The cut surface demonstrated a pale tan, firm, sharply circumscribed nodule measuring 1.7 cm at the greatest diameter, with several centrally located small firm white filaments less than 1

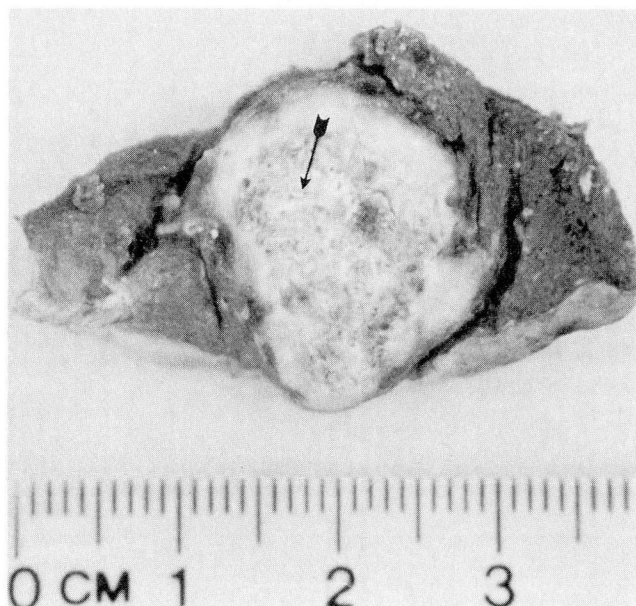

FIGURE 2. Cut surface of the surgical specimen; arrow points to the white filaments.

mm thick (Figure 2). Histologic sections demonstrated a sharply circumscribed granuloma with a central necrotic area. Necrotic zones were partially bordered by palisading histiocytes, plasma cells, and lymphocytes. Multinucleated giant cells were also identified.

An elastic stain confirmed the presence of a nonviable parasite within a small pulmonary artery (Figure 3). A nematode worm was seen, approximately 300 μ m in diameter, with a smooth layered external cuticle that had two internal thickenings in the lateral aspect. Its internal organs were necrotic and calcified. An organized thrombus adherent to the vessel wall surrounded the worm. The periphery of the granuloma demonstrated fibroplasia.

DISCUSSION

Dirofilaria immitis is a parasite of dogs in many parts of the world.⁷ Mature *D immitis* resides in the right ventricle and pulmonary arteries of its preferred primary host (the dog) where it grows rapidly and causes severe morbidity and mortality.

Many varieties of mosquito act as intermediate hosts by aspirating microfilariae from the dog's blood. The microfilariae transform into larvae that are transferred back to the dog or accidentally to humans via a mosquito bite. The larvae migrate to the heart where

they mature. In dogs, the completion of the maturation process finishes the life cycle of the worm.

In 1984, 64 cases of pulmonary dirofilariasis were reported in the United States.⁸ The infection once occurred mainly in the Atlantic and Gulf Coast states as well as in the Mississippi River Valley; but the infection has spread to all states as infected dogs have moved throughout the country.⁷

Course of infection

Mature females are 25 cm to 35 cm long and 1 mm to 2 mm thick, and mature males are 12 cm to 18 cm long by 1 mm to 2 mm thick. The worm has a layered smooth cuticle 5 μ m to 25 μ m thick except in the ventral aspect of the posterior end of the males.^{9,10} Inside the worm, abundant somatic muscles, intestine, two uteri in the female, and one reproductive tube in the male can be seen. For unknown reasons, in humans the worm dies in the heart before completely maturing, and it subsequently embolizes to the lung. Two cases of complete adult maturation in human hosts have been reported,¹¹ but no case of microfilaremia has been documented.

The nonviable worm embolizes to the pulmonary arteries and produces thrombosis, infarction, and a subsequent granulomatous reaction. An insoluble antigen may diffuse through the arterial wall, thereby inducing the granulomatous inflammatory response. This response may explain why the lesion is round and not triangular, like most occlusive infarcts. The nodule is usually found in the periphery of the lung and measures 1 cm to 3 cm in diameter. The right lower lobe is the predominant location.

Gross examination

The cut surface of the nodule is white-tan to gray with a well-demarcated peripheral rim. Grossly, the nodule can be confused with a neoplastic process. White threadlike tubular filaments less than 1 mm thick may also be seen.¹¹ These white filaments, which are part of the necrotic parasite, can easily be overlooked.

In our case we were able to identify several small filaments (Figure 2). Although this macroscopic detail is not emphasized in the literature, it is important for the diagnosis, which ultimately depends on the microscopic features of the worm.

The lesion is commonly solitary, but multiple nodules that mimic metastases have been described.¹²

A central area of necrosis is surrounded by a granulomatous reaction containing epithelioid his-

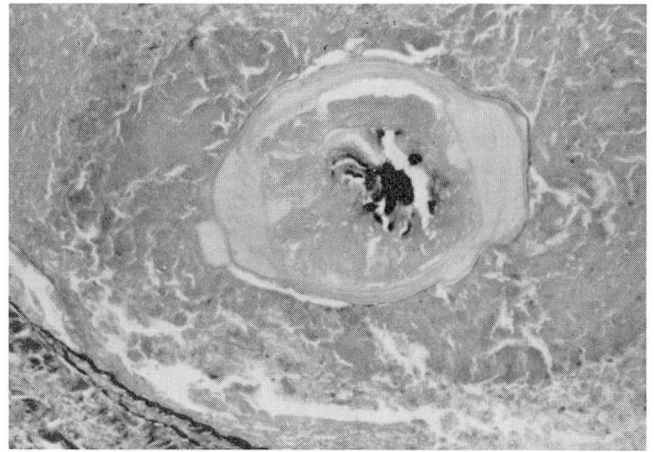


FIGURE 3. Cross section of the necrotic parasite. Arterial internal elastic can be seen at left lower corner (original magnification $\times 600$).

tiocytes, lymphocytes, plasma cells, and occasional giant cells. The granuloma is bordered by a fibrous wall with lymphocytes and macrophages. One or several cross-sections of the worm are seen inside the necrotic area in most cases. However, because of degeneration, the worm may be difficult to identify. An elastic stain demonstrates the location of the parasite within the arterial lumen.

Diagnostic features and natural history

Dimmitis infection is the most likely diagnosis when a nematode measuring 150 μ m to 330 μ m with a smooth layered cuticle is found within an artery in a pulmonary infarct.⁹ Nematodes infecting the lung are mainly located intrabronchially.¹² However, live *Brugia* and *Wuchereria* worms have been found within small pulmonary arteries in patients in India.^{9,10}

The natural history of pulmonary dirofilariasis is not well known. Two months is the shortest time reported between a normal radiograph and a well-developed nodule.⁸ Two cases of pulmonary dirofilariasis in which pulmonary infiltrates developed in 2 weeks have also been reported.⁸ The longest documented time span of progressive enlargement of the nodule is 18 months.⁷ It is uncertain whether the lesion shrinks to a smaller nodule, but it is believed that in most instances lesions ultimately calcify. Perhaps many cases of ancient granuloma of unknown cause in the lung were caused by *Dirofilaria*.⁷

Clinical and radiologic features of pulmonary dirofilariasis are nonspecific. Primary bronchogenic carcinoma, tuberculosis, fungal, and other parasitic in-

fections and hamartomas should be considered in the differential diagnosis. Most nodules are resected because of the need to exclude a malignancy. Chest radiographs usually reveal a single "coin lesion" in the peripheral lung field. *Dirofilariasis* may differ from tuberculoma or from histoplasmosis because *dirofilariasis* generally has a shaggy outer border.⁷

Approximately 60% of patients are asymptomatic, and the lesion is found incidentally by routine chest radiograph or at autopsy. Cough is a complaint in 25% of patients, and 17% have chest pain. Hemoptysis and fever have been identified in only 8.5% and 6.4% of patients, respectively.⁷ Peripheral eosinophilia is reported to be present in only 15%.⁷

Diagnostic tests

Serologic tests are available for diagnosis but it is unknown whether they have sufficient diagnostic value to eliminate the need for a thoracotomy. Most authors agree that specificity is lacking and that cross-reactivity with other helminths or other filarial parasites is a concern.

The ELISA is considered positive with titers equal to or greater than 1:32, and the indirect hemagglutination test is diagnostic for titers equal to or greater than 1:128.¹³ In one study of eight cases of histologically documented pulmonary *dirofilariasis*, five had a positive indirect hemagglutination test and six had a positive ELISA. Two patients had a false negative titer.¹³

Fine needle aspiration of the nodule is usually unsuccessful since the retrieved material is either insufficient or nondiagnostic. One case of diagnosis by aspiration has been reported.¹⁴ Thoracotomy followed by wedge resection of the nodule and histopathological evaluation is the only reasonable alternative to confirm the diagnosis.¹⁵ Medical therapy is not available.

ACKNOWLEDGMENTS

The authors wish to thank Y. Gutierrez, MD, PhD, Institute of Pathology, Case Western Reserve University School of Medicine and University Hospitals of Cleveland, Ohio, for the review of this manuscript and the constructive suggestions.

REFERENCES

1. Dashiell GE. A case of *dirofilariasis* involving the lung. *Am J Trop Med Hyg* 1961; 10:37-39.
2. Dayal Y, Neafie RC. Human pulmonary *dirofilariasis* in man: a case report and review of the literature. *Am Rev Respir Dis* 1975; 112:437-443.
3. Robinson NB, Chavez CM, Conn JH. Pulmonary *dirofilariasis* in man: a case report and review of the literature. *J Thorac Cardiovasc Surg* 1977; 74:403-408.
4. Ciferri F. Human pulmonary *dirofilariasis* in the United States: a critical review. *Am J Trop Med Hyg* 1982; 31:302-308.
5. Tsung SH, Ling JI, Han D. Pulmonary *dirofilariasis* in man. *Am J Med Sci* 1982; 283:106-110.
6. Ro JY, Panagiotis JT, White V, et al. Pulmonary *dirofilariasis*: the great imitator of primary or metastatic lung tumor: a clinicopathologic analysis of seven cases and a review of the literature. *Hum Pathol* 1989; 20:69-76.
7. McChesney T, Martinez LC, Painter MW. Human pulmonary *dirofilariasis* granuloma. *Ann Thorac Surg* 1983; 36:214-217.
8. Kochar AS, Akao N. Human pulmonary *dirofilariasis*: report of three cases and review of the literature. *Am J Clin Pathol* 1985; 84:19-23.
9. Gutierrez Y. Diagnostic features of zoonotic filariae in tissue sections. *Hum Pathol* 1984; 15:514-525.
10. Gutierrez Y. Diagnostic pathology of parasitic infections with clinical correlations. Philadelphia: Lea and Febiger; 1990:327-329.
11. Abadie H. A human case of *Dirofilaria immitis* infection. *Am J Trop Med Hyg* 1965; 14:117-118.
12. Kahn FW, Wester SM, Agger WA. Pulmonary *dirofilariasis* and transitional cell carcinoma: benign lung nodules mimicking metastatic neoplasms. *Arch Intern Med* 1983; 143:1259-1260.
13. Glickman LT. Serologic diagnosis of zoonotic pulmonary *dirofilariasis*. *Am J Med* 1986; 80:161-164.
14. Hawkins AG, Hsiu JG, Smith FP, Siddiky M, Edwards OE. Pulmonary *dirofilariasis* diagnosed by fine needle aspiration biopsy: A case report. *Acta Cytol* 1985; 29:19-21.
15. Fleisher AG, Mesina JJ, Ryan SF, Hopkins KS. Human pulmonary *dirofilariasis*: does the diagnosis require thoracotomy? *Ann Thorac Surg* 1988; 45:447-448.