

DONALD G. VIDT, MD, AND ALAN W. BAKST, PHARM D, RPH, EDITORS

Adenosine: a new drug for acute termination of supraventricular tachycardia

SERGIO L. PINSKI, MD, AND JAMES D. MALONEY, MD

■ Adenosine, recently released for the acute termination of supraventricular tachycardia, is potentially the drug of first choice for this indication. Its notable effects are transient slowing of the sinus rate and atrioventricular nodal block. Adverse effects are transient and clinically insignificant, primarily because of the ultra-short half-life of the drug. Preliminary investigations suggest that adenosine may also be useful in the differential diagnosis of wide QRS complex tachycardias.

□ INDEX TERMS: ADENOSINE; TACHYCARDIA, WIDE-COMPLEX □ CLEVE CLIN J MED 1990; 57:383-388

ADENOSINE (Adenocard, Lyphomed, Inc.) was released recently in the United States for acute termination of supraventricular tachycardia (SVT). Adenosine triphosphate (ATP), a congener, has been available for several years in Europe, where it is now the drug of choice for pharmacologic termination of paroxysmal sustained SVT.¹ Adenosine is the pharmacologically active metabolite of ATP, and we believe it is likely to become both the preferred drug for managing discrete episodes of paroxysmal SVT as well as a valuable and safe diagnostic tool for differentiating SVT with aberration from sustained ventricular tachycardia (VT).

PHARMACOLOGY

Adenosine is an endogenous compound in all human tissues. It is involved in several physiologic processes, including the regulation of the microcirculation (mostly at

the coronary level) and the modulation of neurotransmission in the autonomic nervous system.² At pharmacologic doses its most remarkable effects are transient slowing of the sinus rate and atrioventricular (AV) nodal conduction, with lengthening of the PR segment on the electrocardiogram (ECG) and of the AH interval in a His Bundle recording. Sufficiently high doses may cause transient, high-degree AV nodal block, but without significant effects on the infranodal conduction or AV accessory pathways.¹ Adenosine has no direct effects on ventricular tissue, but it may have indirect antiadrenergic effects at that level.³ All these effects depend on the binding of adenosine to a specific cell-surface receptor (A_1). Pretreatment with theophylline (a competitive antagonist of adenosine receptors) will prevent the binding and its effects.⁴ Dipyridamole blocks the uptake of adenosine into cells, enhancing its effect by allowing more time for binding to cell-surface receptors.³

Adenosine must be given intravenously, since it is rapidly taken up and inactivated by cells throughout the body. Its ultra-short half life is a hallmark of the drug, with duration of effects measured in seconds. This provides a margin of safety that negates nearly all potential adverse effects: repeated doses can be administered over short periods of time without concern about accumula-

From the Department of Cardiology, The Cleveland Clinic Foundation.

Address reprint requests to J.D.M., Department of Cardiology, The Cleveland Clinic Foundation, One Clinic Center, Cleveland, Ohio 44195.

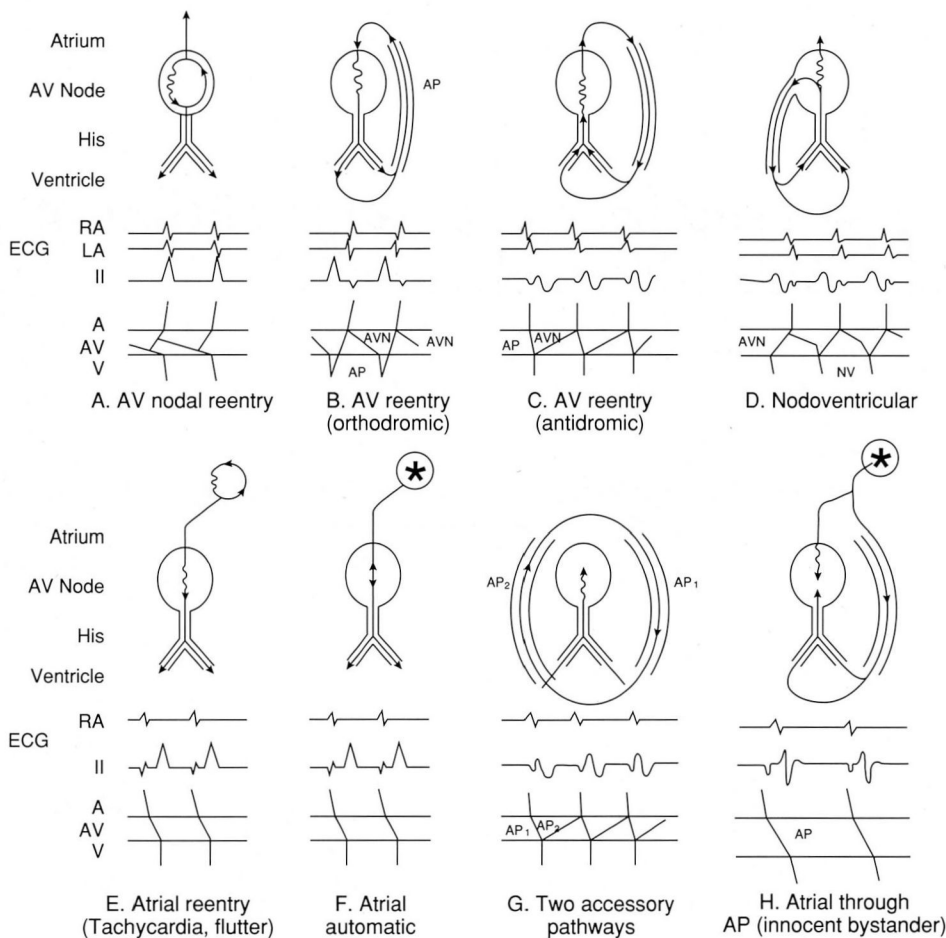


FIGURE 1. Schematic representation of supraventricular tachycardias. Types A, B, C, and D have the atrioventricular node (AVN) as part of their circuitry and therefore are adenosine-terminable. In types E and F, the AV node only determines the ventricular response; therefore, the only effect of adenosine will be a transient decrease in the ventricular rate without affecting the tachycardia. Types G and H are rare; the AVN is not part of their mechanism and adenosine will not modify them in any way. AVN: atrioventricular node; RA: right atrium; LA: left atrium; NV: nodoventricular; AP: accessory pathway.

tion, ensuring safety for both therapeutic and diagnostic use.

TERMINATION OF KNOWN SVT

Clinically occurring paroxysmal SVT is heterogeneous (Figure 1). By far the most common SVTs are the reentrant tachycardias in which the AV node is part of the circuitry (eg, AV nodal reentrant tachycardia and

AV tachycardia using an accessory pathway). In other SVTs, such as ectopic or re-entrant atrial tachycardia and atrial flutter, the AV node determines the ventricular response, but it is unnecessary for the perpetuation of the arrhythmia.

Because of its transient AV nodal blocking effects, adenosine helps to terminate more than 95% of junctional reentrant tachycardias.^{1,5-7} Other types of supraventricular arrhythmias will almost never convert, but the transient AV block induced by the drug will unmask atrial deflections in the ECG, facilitating diagnosis of the origin and mechanism of the arrhythmia.

The recommended dosage for adults is 6 mg (one vial) given as a rapid IV bolus. If given through an IV line, the line must be flushed with saline immediately afterwards. Local irritation does not occur in the event of extravasation. Of the patients who eventually respond to adenosine, half will revert in less than 30 seconds after this first injection.⁸ If the patient does not respond within 30 seconds, two subsequent incremental doses of 9 mg and 12 mg may be given 1 to 2 minutes apart. This dosing schedule

lessens the chance of side effects and yet can be completed in less than 5 minutes. The recommended dose in infants and children is 37.5 micrograms/kg, with successive increments of 37.5 micrograms/kg until a maximum of 350 micrograms/kg is reached.⁹

This treatment has limited adverse effects. Hypotension does not occur, even in patients with left ventricular dysfunction or in infants.^{9,10} Bradycardia after conversion of the SVT is short-lived (Figure 2), although in

patients with sick sinus syndrome longer pauses may be expected. Transient arrhythmias, such as atrial or ventricular premature complexes, also may appear, but they are clinically inconsequential. The most common reported side effects are cutaneous flushing, dyspnea, and chest pain, each occurring in about 20% of patients). Although sometimes quite uncomfortable, these effects are nevertheless transient and clinically insignificant. Patients will tolerate them better if informed of their nature before the injection.

There are no definite contraindications to adenosine therapy. Patients with severe sinus node dysfunction should receive the drug only if they have a functioning ventricular pacemaker. Inhaled adenosine has been shown to have bronchoconstricting effects in asthmatic patients, and the absence of data on the effects of parenteral administration suggest that the drug be used with caution in this patient population.

Patients who are already being treated with dipyridamole should be started on very low doses of adenosine to prevent untoward effects. Finally, patients who are receiving methylxanthines are refractory to conventional doses and are not candidates for treatment with adenosine. There are no data on the effects of xanthine beverages such as coffee on the efficacy of subsequently administered adenosine.

Comparison with IV verapamil

Intravenous verapamil was until now the drug of first choice for termination of SVT. It is about 90% effective in terminating reentrant junctional tachycardias, and has a good safety record, provided contraindications are respected. These include infants younger than 1 year, patients with congestive heart failure or severe left ventricular dysfunction, and those already being treated with antiarrhythmic drugs, especially beta blockers.¹¹ In patients with Wolff-Parkinson-White syndrome, there is a small chance that after verapamil therapy, the SVT will convert to atrial fibrillation or atrial flutter with a very rapid conduction through the accessory pathway.^{12,13} Adenosine lacks these drawbacks, although

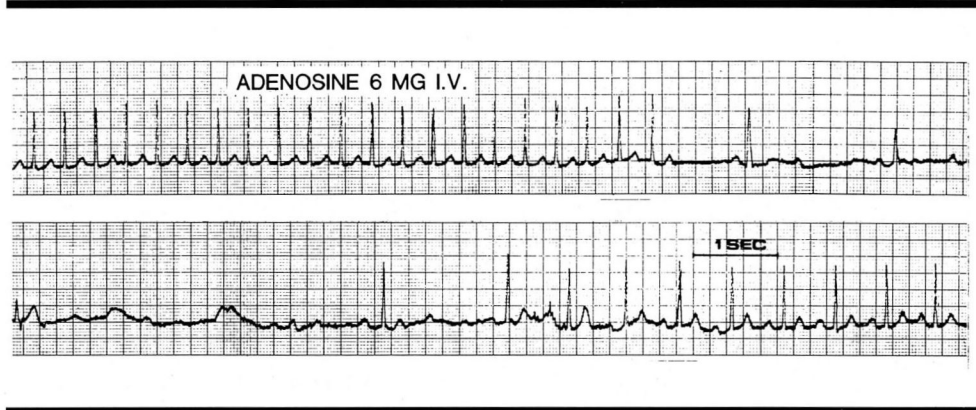


FIGURE 2. Termination of SVT by a bolus of adenosine after 10 mg of verapamil had produced no response. Note the transient bradycardia (longest pause 4.4 seconds; these pauses are inconsequential).

further information is needed on its interactions with other drugs.

A few trials have compared adenosine with verapamil in the treatment of SVT. In one well-designed crossover study,¹⁴ adenosine was slightly more effective. More important, there were no significant side effects with adenosine, while verapamil therapy was followed by transient symptomatic preexcited arrhythmias in two of nine patients with Wolff-Parkinson-White syndrome.¹⁴ Another randomized study of 135 patients showed that both drugs were almost equally effective in terminating SVT.¹⁵

Based on currently available data, adenosine can be recommended as the drug of first choice for the termination of SVT in patients with Wolff-Parkinson-White syndrome and those with contraindications for verapamil. In patients with AV nodal reentrant tachycardia, verapamil may have the advantage of a longer duration of action, making recurrences less likely while prophylactic treatment is being instituted.^{13,16}

Since the mechanism of the tachycardia is usually unknown at the time of presentation, we strongly believe that adenosine is indicated as the first choice therapy for termination of almost all episodes of SVT that are unresponsive to vagal maneuvers.

DIFFERENTIAL DIAGNOSIS OF WIDE COMPLEX TACHYCARDIAS

Patients with relatively well-tolerated, regular, wide QRS-complex tachycardia present a frequent problem in acute care settings. The differential diagnosis includes SVT with either fixed or rate-related bundle branch

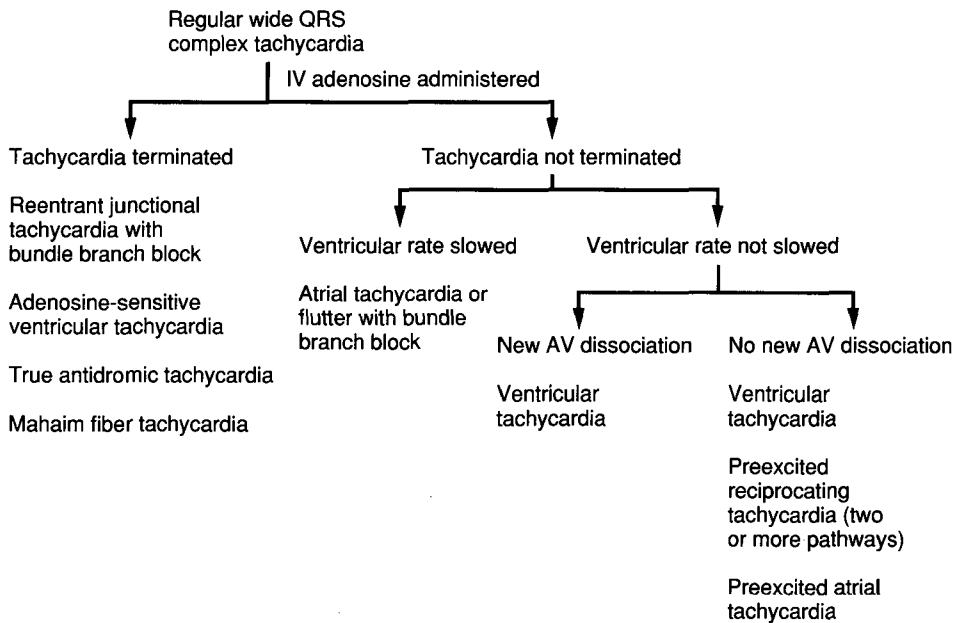


FIGURE 3. Differential diagnoses following administration of intravenous adenosine to a patient with a well-tolerated wide QRS-complex tachycardia. Most likely diagnosis in each setting is listed first.

block; preexcited reciprocating tachycardia¹⁷; reciprocating tachycardia via a Mahaim, or nodoventricular, fiber¹⁸; preexcited arrhythmias in which the accessory pathway is an “innocent bystander,” such as atrial tachycardia and flutter; and ventricular tachycardia (VT).

In general, a wide-complex tachycardia should be considered as VT unless proved otherwise, especially in a patient with a history of heart disease.¹⁹ Nevertheless, a specific diagnosis should be sought when the situation allows it, because each entity has its own prognosis and therapeutic approach. Although several clinical and 12-lead ECG findings can help in the differential diagnosis,^{19,20} none has perfect predictive accuracy or is applicable in every patient. Furthermore, considerable expertise is needed to interpret these findings, and frequently the necessary baseline ECG is missing.

Several surveys have shown wide QRS complex tachycardia is usually diagnosed incorrectly when first assessed.^{21,22} A common—and dangerous—error is to mistake VT for SVT. If IV verapamil is given in this situation, there is considerable risk of precipitating acute hemodynamic decompensation, ventricular fibrillation, or both.^{22,23}

Adenosine could fill the need for an effective diagnostic aid in this common clinical setting. Theoretically, several situations could follow the administration of adenosine in a patient with a wide QRS complex tachycardia (Figure 3), each one narrowing the diagnostic possibilities. For example, if the tachycardia is converted abruptly to sinus rhythm, the most probable diagnosis is reentrant junctional tachycardia with fixed or rate-related bundle branch block. The post-conversion ECG will make the distinction. In addition, the nodal blocking effects of the drug will favor conduction of the first several sinus beats over any existing anomalous pathway. This development can facilitate the diagnosis of the Wolff-Parkinson-White syndrome, even in

patients with subtle, intermittent, or latent preexcitation (Figure 4).¹⁴

Adenosine may terminate some relatively uncommon VTs that are similar to those responsive to verapamil. These adenosine-responsive tachycardias are thought to be due to catecholamine-dependent mechanisms. They tend to occur in young patients who have no overt heart disease, and they are frequently precipitated by exercise. Their course is usually benign.²⁴

Two other uncommon types of tachycardia may be responsive to adenosine: a bizarre tachycardia that represents true antidromic tachycardia, and a tachycardia that uses a Mahaim fiber. Antidromic tachycardia is suspected when preexcited is depicted during sinus rhythm and the polarity of the delta wave equals that of the first QRS vector during tachycardia. The Mahaim fiber tachycardia is considered when the sinus QRS is normal and the tachycardia has the typical left bundle branch block pattern reported by Bardy and colleagues.¹⁸ These types of tachycardia are difficult to diagnose even during an electrophysiologic study. Adenosine may be useful in that setting as well.

If the maximum dose of 12 mg of adenosine does not

terminate the tachycardia, then several diagnostic possibilities remain. For example, if the ventricular rate decreases secondary to the transient AV block produced by adenosine, the likely diagnosis is sinus tachycardia, atrial tachycardia, or flutter with bundle branch block. The morphology of the atrial deflection will aid in the diagnosis of the exact atrial mechanism. If the tachycardia is not slowed, the next step is to look for transient AV dissociation. A Lewis or an esophageal lead is helpful, but not essential for better visualization of AV dissociation. Although AV dissociation strongly suggests VT, it is present spontaneously in only about 50% of cases of VT.²⁰ A confident diagnosis of VT may be made if the AV nodal blocking effect of adenosine produces transient AV dissociation in patients with baseline VT with 1:1 ventriculo-atrial conduction.

If the drug has no effect on the tachycardia, or if no clear P waves are seen and it is impossible to diagnose AV dissociation, then three diagnoses should be considered—VT being the most probable. The others are preexcited tachycardias using two accessory pathways and atrial tachycardia (or flutter) in which the accessory pathway acts as an innocent bystander.

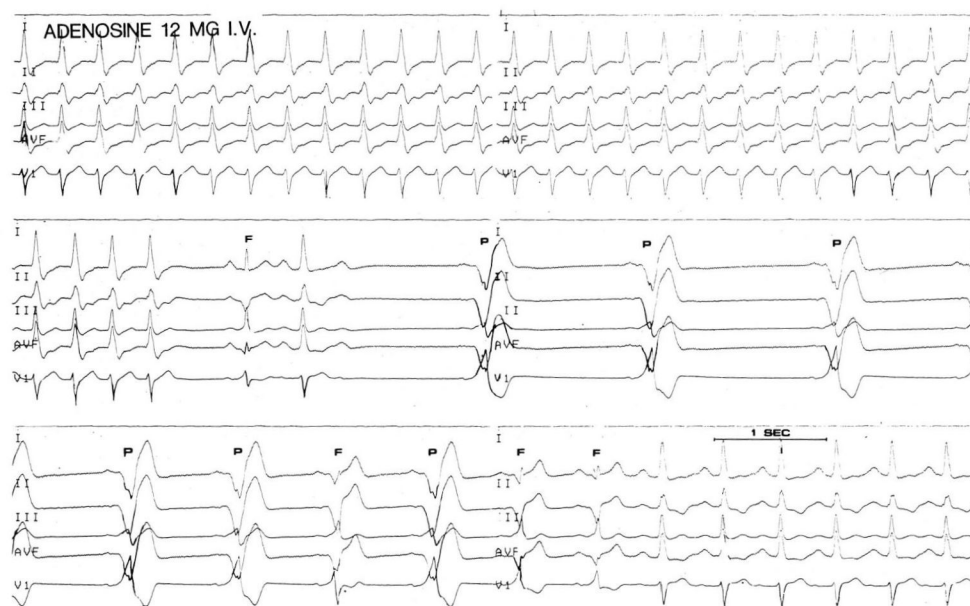


FIGURE 4. Termination of SVT by adenosine in a patient with latent Wolff-Parkinson-White syndrome. The transient bradycardia and AV nodal block allow the identification of the accessory pathway in fusion (F) or fully preexcited (P) beats.

These hypotheses have not yet been fully tested. Some small trials of adenosine as a diagnostic aid in wide QRS tachycardias, done in the controlled environment of electrophysiologic laboratories, have had encouraging results with no documented instances of hemodynamic decompensation.^{16,25} Trials are now needed from “front line” emergency rooms, intensive care units, and physicians’ offices.

REFERENCES

1. Puech P, Sassine A, Munoz A, et al. Electrophysiologic effects of purines: Clinical applications. [In] Zipes D, Jalife J, eds. *Cardiac Electrophysiology and Arrhythmias*. Orlando, Fla, Grune and Stratton, 1985, pp 443-450.
2. Pelleg A, Michelson E, Dreifus L. Introduction. [In] Pelleg A, Michelson E, Dreifus L, eds. *Cardiac Electrophysiology and Pharmacology of Adenosine and ATP: Basic and clinical aspects*. New York, Alan R. Liss, 1987, pp 13-16.
3. Daly J, Jacobson K, Ukena D. Adenosine receptors: development of selective agonists and antagonists. [In] Pelleg A, Michelson E, Dreifus L, eds. *Cardiac Electrophysiology and Pharmacology of Adenosine and ATP: Basic and clinical aspects*. New York, Alan R. Liss, 1987, pp 42-63.
4. Bailey J, Rardon D. Electrophysiological effects of adenosine and dipy-

- ridamole on cardiac Purkinje fibers and ventricular myocardium. [In] Pelleg A, Michelson E, Dreifus L, eds. *Cardiac Electrophysiology and Pharmacology of Adenosine and ATP: Basic and Clinical Aspects*. New York, Alan R. Liss, 1987, pp 119-133.
5. DiMarco JP, Sellers D, Berne RM, West GA, Belardinelli L. Adenosine: electrophysiologic effects and therapeutic use for terminating paroxysmal supraventricular tachycardia. *Circulation* 1983; **68**:1254-1263.
6. DiMarco JP, Sellers TD, Lerman BB, Greenberg ML, Berne RM, Belardinelli L. Diagnostic and therapeutic use of adenosine in patients with supraventricular tachyarrhythmias. *J Am Coll Cardiol* 1985; **6**:417-425.
7. Munoz A, Sassine A, Puech P. Cardiac electrophysiology and therapeutic use of adenosine and adenosine triphosphate. [In] Pelleg A, Michelson E, Dreifus L, eds. *Cardiac Electrophysiology and Pharmacology of Adenosine and ATP: Basic and Clinical Aspects*. New York, Alan R.

- Liss, 1987, pp 255-267.
8. Caruso A, Miles W, Klein L, Zipes D. Double-blind, placebo controlled, dose-ranging study of adenosine in patients with supraventricular tachycardia (abstract). *Circulation* 1989; 80 (suppl):II632.
 9. Overholt ED, Rheuban KS, Gutgesell HP, Lerman BB, DiMarco JP. Usefulness of adenosine for arrhythmias in infants and children. *Am J Cardiol* 1988; 61:336-340.
 10. Till J, Shinebourne EA, Rigby ML, Clarke B, Ward DE, Rowland E. Efficacy and safety of adenosine in the treatment of supraventricular tachycardia in infants and children. *Br Heart J* 1989; 62:204-211.
 11. Kieval J, Kirsten EB, Kessler KM, Mallon SM, Meyerburg RJ. The effects of intravenous verapamil on hemodynamic status of patients with coronary artery disease receiving propranolol. *Circulation* 1982; 65:653-659.
 12. Belhassen B, Viskin S, Laniado S. Sustained atrial fibrillation after conversion of paroxysmal reciprocating junctional tachycardia by intravenous verapamil. *Am J Cardiol* 1988; 62:835-837.
 13. Garrat C, Ward D, Camm A. Degeneration of junctional tachycardia to preexcited atrial fibrillation after intravenous verapamil. *Lancet* 1989; 2:219.
 14. Garratt C, Linker N, Griffith M, Ward D, Camm AJ. Comparison of adenosine and verapamil for termination of paroxysmal junctional tachycardia. *Am J Cardiol* 1989; 64:1310-1316.
 15. Adenosine Study Group. Adenosine for termination of paroxysmal supraventricular tachycardia: dose ranging and comparison with verapamil (abstract). *Circulation* 1989; 80:II-631.
 16. Rankin A, Oldroyd K, Chong E, Rae A, Cobbe S. Value and limitations of adenosine in the diagnosis and treatment of narrow and broad complex tachycardias. *Br Heart J* 1989; 62:195-203.
 17. Bardy GH, Packer DL, German LD, Gallagher JJ. Preexcited reciprocating tachycardia in patients with Wolff-Parkinson-White syndrome: Incidence and mechanisms. *Circulation* 1984; 70:377-391.
 18. Bardy GH, Fedor JM, German LD, Packer DL, Gallagher JJ. Surface electrocardiographic clues suggesting presence of a nodofascicular Mahaim fiber. *J Am Coll Cardiol* 1984; 3:1161-1168.
 19. Akhtar M, Shenasa M, Jazayeri M, Caceres J, Tchou PJ. Wide QRS complex tachycardia: reappraisal of a common clinical problem. *Ann Intern Med* 1988; 109:905-912.
 20. Wellens HJJ, Bar FWHM, Lie KI. The value of the electrocardiogram in the differential diagnosis of a tachycardia with a widened QRS complex. *Am J Med* 1978; 64:27-33.
 21. Dancy M, Camm AJ, Ward D. Misdiagnosis of chronic recurrent ventricular tachycardia. *Lancet* 1985; 2:320-323.
 22. Stewart RB, Bardy GH, Greene HL. Wide complex tachycardia: misdiagnosis and outcome after emergent therapy. *Ann Intern Med* 1986; 104:766-771.
 23. Rankin AC, Rae AP, Cobbe SM. Misuse of intravenous verapamil in patients with ventricular tachycardia. *Lancet* 1987; 2:472-474.
 24. Lerman B, Belardinelli L. Effects of adenosine on ventricular tachycardia. [In] Pelleg A, Michelson E, Dreifus L, eds. *Cardiac Electrophysiology and Pharmacology of Adenosine and ATP: Basic and Clinical Aspects*. New York, Alan R. Liss, 1987, pp 301-314.
 25. Griffith MJ, Linker NJ, Ward DE, Camm AJ. Adenosine in the diagnosis of broad complex tachycardia. *Lancet* 1988; 1:672-675.

