

Evaluation of the temporomandibular joint¹

David Piraino, M.D.

Myofacial pain can be caused by a variety of disorders including disorders of the temporomandibular joint (TMJ). Several imaging procedures provide important information useful in diagnosing TMJ disorders. Transcranial lateral radiographs and tomograms are helpful in evaluating the TMJ space and the bony structures about the TMJ. On plain radiographs, joint-space narrowing, subchondral cysts, and spurs indicate degenerative joint disease. Computed tomography is also helpful in evaluating the bony structures around the TMJ and can be used to diagnose internal TMJ derangements. Arthrography is also used to diagnose internal derangements as well as provide information about the dynamics of TMJ motion.

Index terms: Temporomandibular joint • Temporomandibular joint diseases

Cleve Clin Q 53:373-376, Winter 1986

Patients with temporomandibular joint (TMJ) dysfunction can exhibit a wide variety of symptoms, including pain, headaches, grinding noises, clicking, locking, and muscle spasm. Some patients respond to conservative therapy, but patients with persistent symptoms may have internal derangements of the TMJ.¹ Persistent symptoms

can also be related to other joint disorders, including osteoarthritis, rheumatoid arthritis, and seronegative spondyloarthropathies.

Internal derangement of the TMJ is an abnormal relationship of the intra-articular disk to the mandibular condyle and articular portion of the temporal bone. The disk is normally biconcave with thick portions anteriorly and posteriorly. The thin, biconcave portion of the disk should articulate between the mandibular condyle and temporal bone whether the mouth is open or closed (*Fig. 1*). The disk moves anteriorly with the mandibular condyle as the mouth is opened and moves posteriorly with the condyle as the mouth is closed.

In internal derangements, the articular disk is usually displaced anteriorly and medially. In disk displacement with reduction, the disk is anteriorly displaced when the mouth is closed and reduces to its normal position as the mouth opens. In disk displacement without reduction, the disk is anteriorly displaced when the mouth is closed and does not return to its normal position with movement of the condyle.²

Case report

A 35-year-old woman seen at the Cleveland Clinic had a several-year history of noises related to the TMJ. She also complained of her jaw locking on several occasions and recently had stopped eating solid food because of pain in the TMJ areas. Previously, she had been treated with a protrusion splint.

Since the patient had severe and prolonged symptoms, tomograms and arthrograms were obtained. Plain tomograms demonstrated flattening of the anterior portions of

¹ Department of Diagnostic Radiology, Bone and Joint Section, The Cleveland Clinic Foundation. Submitted for publication March 1986; accepted April 1986. pa

0009-8787/86/04/0373/04/\$2.00/0

Copyright © 1986, The Cleveland Clinic Foundation

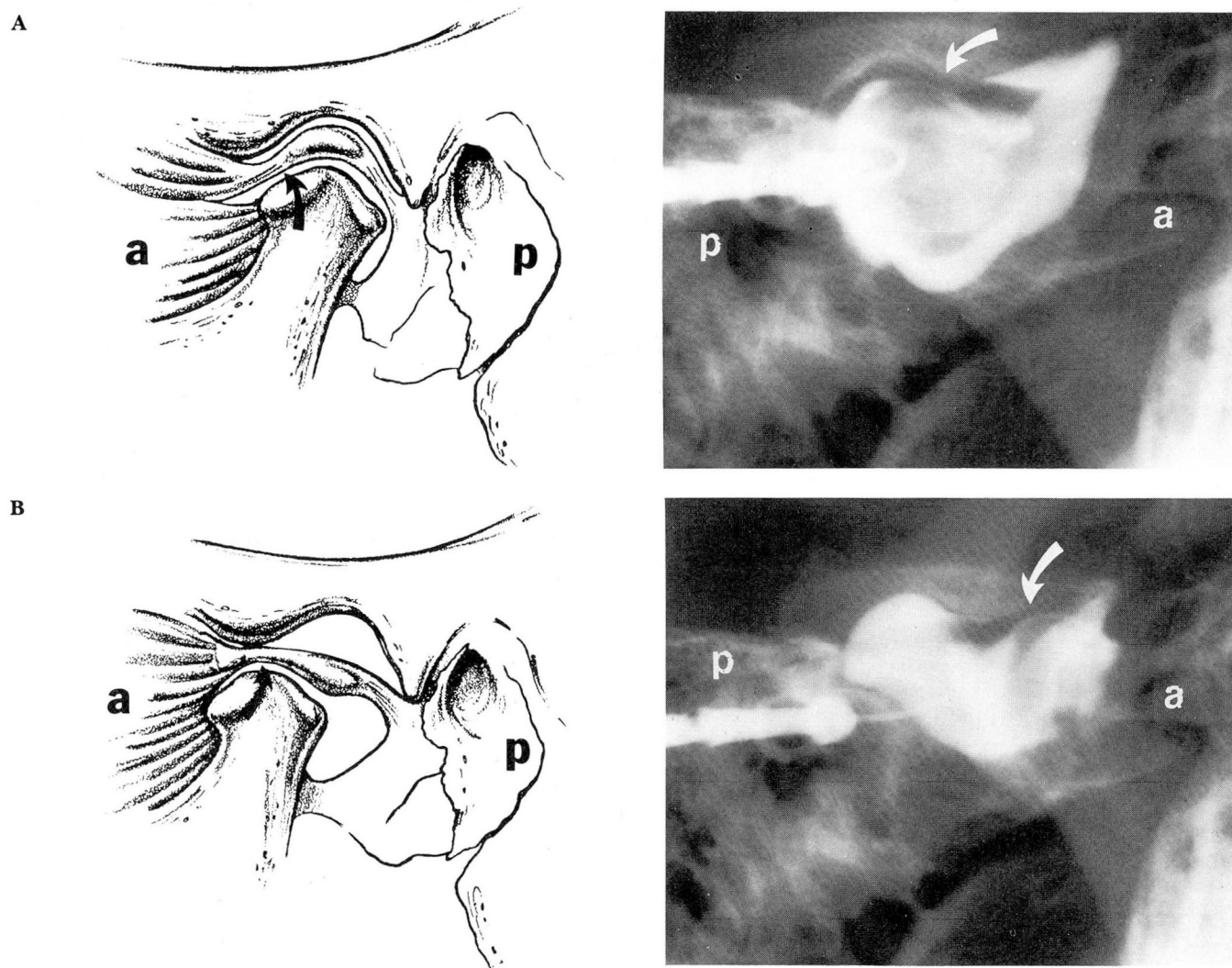


Fig. 1. A. Left: Diagram demonstrating normally positioned disk when the mouth is closed, with the thin biconcave portion (arrow) articulating between the mandibular condyle and temporal bone. **Right:** Arthrogram of the opposite TMJ from the diagram, demonstrating a normally placed disk (arrow).

B. Left: Diagram of normally positioned disk when the mouth is open, with the thin biconcave portion (arrow) between the condyle and temporal bone. **Right:** Arthrogram of the opposite TMJ from the diagram, demonstrating a normally placed disk when the mouth is open (arrow).

a = anterior, p = posterior. (Diagrams by Joseph Pangrace)

both mandibular condyles as well as osteophytes involving these portions of the mandibular condyles (Fig. 2), findings characteristic of osteoarthritis. Arthrograms of both joints showed anteriorly displaced disks, which did not reduce an opening (Fig. 3). The disks were also deformed, without the normal biconcave appearance.

Discussion

The transcranial lateral radiographs with the mouth open and closed should be used to evaluate the TMJ. A plain radiograph provides information about the temporomandibular joint space

and the bony structures around the TMJ, including the mandibular condyle and the articular portion of the temporal bone. The relative motion of the mandibular condyle in relation to the temporal bone can also be evaluated. Osteophytes, degenerative cysts, and remodeling of the mandibular condyle are hallmarks of osteoarthritis of the TMJ.³ Also, erosive changes can be seen in patients with inflammatory arthritis, such as rheumatoid arthritis.

For up to 85% of patients with TMJ dysfunc-

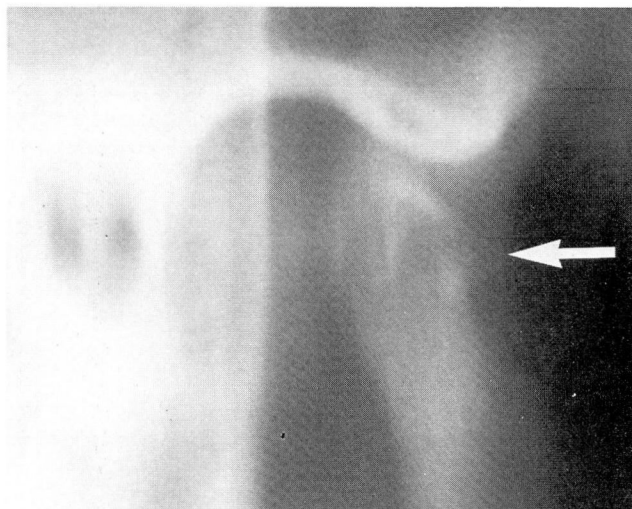


Fig. 2. Plain tomogram demonstrating a moderate-sized osteophyte (arrow) on the anterior portion of the mandibular condyle.

tion, plain radiographs show no abnormalities.⁴ In addition, transcranial lateral radiographs demonstrate a wide variation in the appearance of the TMJ because of differences in projection. Plain tomograms and direct or indirect, sagittal computed tomograms have several advantages for evaluating the TMJ, especially when bony changes are suspected: Plain tomograms blur overlying structures, providing a clear view of the mandibular condyle, temporal bone, and joint space (*Fig. 2*).

Computed tomography has the additional advantage of better soft-tissue contrast and can be useful in diagnosing internal derangements (*Fig. 4*). In recent studies, computed tomography has demonstrated 96% agreement with arthrography and surgery in diagnosing internal TMJ derangements.⁵ With computed tomography, anteriorly displaced disks are visualized as areas of increased attenuation anterior and medial to the mandibular condyle. Computed tomography is also useful for evaluating the periarticular tissues. Unfortunately, this technique cannot provide information about the dynamics of TMJ motions, which can be important in patient management.

At present, arthrography provides the most information about internal TMJ derangements. During arthrography, the motion of the intra-articular disk, as well as its position, can be evaluated, and the study can be video-taped for later review. The disk position can be seen very well, and disk perforations can also be diagnosed. The

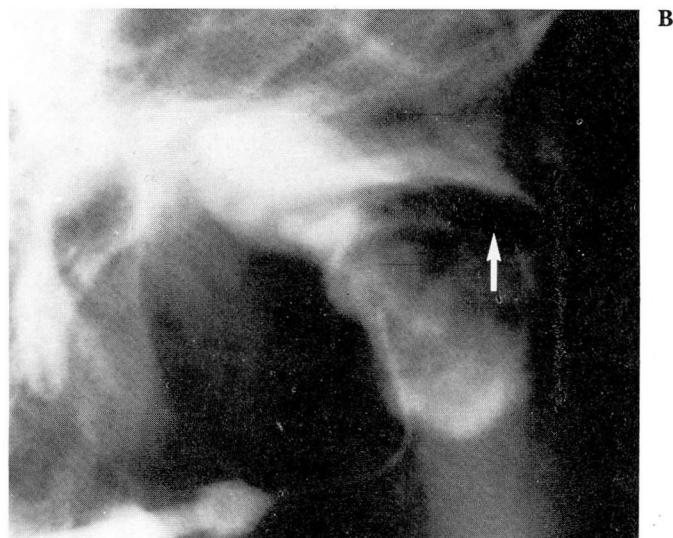
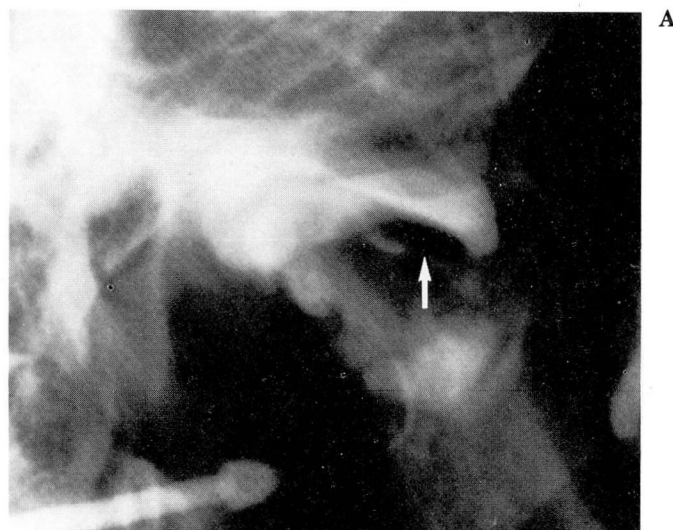

Fig. 3. A. Anteriorly displaced disk (arrow) with the mouth closed.

B. Anteriorly displaced disk with the mouth open (arrow).

major disadvantages of arthrography are its invasiveness, discomfort after the procedure, and radiation exposure.

The intra-articular disk separates the TMJ into upper and lower joint spaces. During arthrography both the upper and lower joint spaces may be injected, or only the lower joint space may be injected. An anteriorly displaced disk is diagnosed when the anterior recess of the lower joint space has a concave upper margin whether the mouth is open or closed. If the disk reduces as the mouth is opened, a rapid posterior motion of the disk in relation to the mandibular condyle

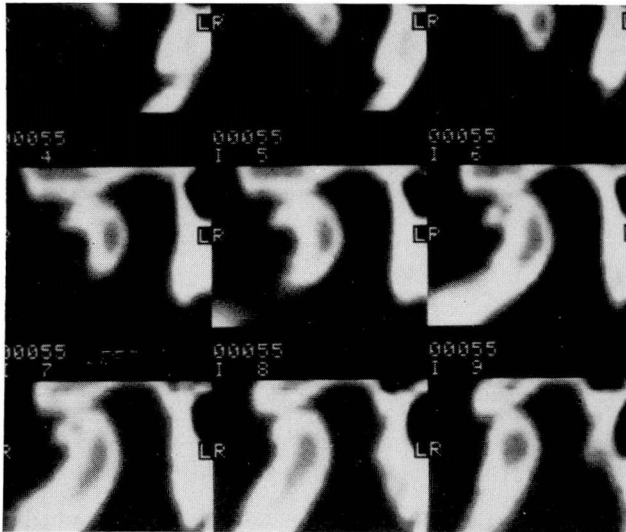


Fig. 4. Sagittal, reconstructed computed tomographic images demonstrating a degenerative spur on the anterior aspect of the mandibular condyle. (Images courtesy of Clyde Helms, M.D., UCSF)

can commonly be seen, and the patient commonly experiences clicking associated with relocation of the disk.

In conclusion, plain transcranial lateral radiographs are useful for evaluating the TMJ. However, a significant number of patients with TMJ dysfunction have normal plain radiographs. In these patients, plain tomography, arthrography, and computed tomography can provide additional information about the bony TMJ structures, and arthrography and computed tomog-

raphy can be used to evaluate the position of the intra-articular disk. Recently, magnetic resonance imaging has been used to evaluate the disk's position. This technique will probably become an important imaging tool in patients with TMJ dysfunction.⁷

David W. Piraino, M.D.
Department of Diagnostic Radiology
Bone and Joint Section
The Cleveland Clinic Foundation
Cleveland, OH 44106

References

1. Dolwick MF, Riggs RR. Diagnosis and treatment of internal derangements of the temporomandibular joint. *Dent Clin North Am* 1983; **27**:561-572.
2. Dolwick MF. Diagnosis and etiology. [In] Helms CA, Katzberg RW, Dolwick MF, eds. *Internal Derangements of the Temporomandibular Joint*. Radiology Research and Education Foundation, San Francisco, 1983, pp 31-41.
3. Berrett A. Radiology of the temporomandibular joint. *Dent Clin North Am* 1983; **27**:527-540.
4. Volger JB III, Helms CA. Conventional radiography. [In] Helms CA, Katzberg RW, Dolwick MF, eds. *Internal Derangements of the Temporomandibular Joint*. Radiology Research and Education Foundation, San Francisco, 1983, pp 43-62.
5. Helms CA, Richardson ML, Volger JB III, Hoddick WK. Computed tomography for diagnosing temporomandibular joint disk displacement. *J Craniomandib Practice* 1985; **3**:23-26.
6. Katzberg RW, Dolwick MJ, Helms CA, Hopens T, Bales DJ, Coggs GC. Arthrotomography of the temporomandibular joint. *AJR* 1980; **134**:995-1003.
7. Harms SE, Wilk RM, Wolford LM, Chiles DG, Milam SB. The temporomandibular joint: magnetic resonance imaging using surface coils. *Radiology* 1985; **157**:133-136.