

Congenital lymphedema of genitalia and extremities¹

Jacob W. E. Dijkstra, M.D.
Wilma F. Bergfeld, M.D.
Robert Kay, M.D.

A boy presented at birth with congenital lymphedema of the genitalia. During the following two years, lymphedematous swelling of the right arm and lymphangiectasias, as shown by microscopic examination of noninvolved skin of the other extremities, developed. These generalized lymphatic malformations are rare. The clinical and histopathological changes are detailed, and the possible consequences of further-developed systematized lymphedema and/or lymphangiosarcoma are discussed. Conservative management, including compression therapy, was ineffective. The initial results of surgical reconstruction were satisfactory.

Index terms: Dermatology features • Lymphangiectasis • Lymphedema, congenital

Cleve Clin Q 51: 553-557, Fall 1984

Primary lymphedema is caused by an abnormal development of the subcutaneous lymphatic system. Of the three forms (congenital lymphedema, lymphedema praecox, and lymphedema tarda), the congenital type is the least frequent.¹ Congenital lymphedema usually involves the extremities and sometimes the genitalia.² Involvement of the upper extremities is less frequent

than the lower extremities³ and has been associated with systemic lymphatic malformations.⁴

Reports of lymphangiosarcoma arising in congenital lymphedema after many years⁵ indicate that the disease is more than a cosmetic, functional, and psychological burden for the patient.

We were able to observe a male infant who presented with congenital lymphedema of the penis and scrotum. Swelling of the right arm and, as shown by microscopic examination, lymphedematous changes of all extremities subsequently developed. These findings suggested a generalized malformation of the lymphatics. This case report describes the clinical and histological findings.

Case report

A four-month-old boy was seen at The Cleveland Clinic Foundation in January 1982 with progressive swelling of the penile foreskin and scrotum since birth. Circumcision at one month of age had been difficult and was followed by leaking of a yellow fluid. Urination was noted as normal before and after circumcision. No similar lymphatic malformation was observed in any family members.

The physical examination showed marked brawny edema of the foreskin and scrotum (*Fig. 1*). The testes were normal. There were no palpable abdominal masses. Initially, no abnormalities of the extremities were noted. However, after one-and-a-half years, swelling of the right arm was observed. An ultrasound examination of the pelvis and abdomen, excretory urogram, and voiding cystourethrogram were normal. Conservative treatment, including a Jobst stocking for the penis, was ineffective. Surgery was performed when the patient was two years old. Redundant fibrotic tissue and

¹ Department of Dermatology, The Cleveland Clinic Foundation. Submitted for publication Apr 1984; accepted June 1984. sb

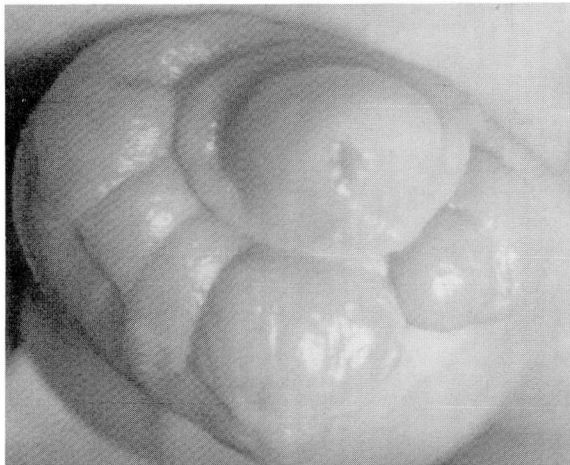


Fig. 1. Brawny edema of foreskin and scrotum.

all subcutaneous tissue were removed. Primary skin closure was accomplished without the use of skin grafts. The cosmetic postoperative result was excellent.

Histopathology

A histopathological examination of the foreskin specimen obtained at circumcision showed marked dermal fibrosis and ectasia of lymphatics and small blood vessels (*Fig. 2*). Additional biopsies of the penile and scrotal skin, performed one-and-a-half years later, showed an increased number of endothelial-lined vascular spaces devoid of red blood cells. In addition, dermal fibrosis was

marked and contained ectatic lymphatic vessels (*Fig. 3, A and B*). Specimens from the right arm and from the nonedematous skin of the left and right thigh, suprapubic area, and left arm showed dilated lymphatic vessels within the superficial and deep dermis. Lymphatic angioplasia was not observed (*Fig. 4*).

Discussion

Lymphedema of the extremities has been reviewed extensively by Taylor and Young.⁶ Most cases of primary lymphedema are caused by hypoplasia of the lymphatics, although occasionally either aplasia or hyperplasia with varicose ectasia of the lymphatic channels is noted.^{1,7} Primary lymphedema is classified as congenital when the swelling is present at birth.⁶ In Milroy's disease, there is also a hereditary component. In lymphedema praecox, the swelling occurs before the patient is 35 years old; this is the most common type of primary lymphedema and frequently affects females. The late-onset type is referred to as lymphedema tarda.

Although several reports in the literature deal with congenital lymphedema of either the genitalia, legs, or arms,^{2,3,5,7-10} the simultaneous occurrence of lymphedema in both the genitalia and lower and upper extremities seems to be rare. Of particular interest in our patient is the microscopic finding of lymphangiectasias in clin-

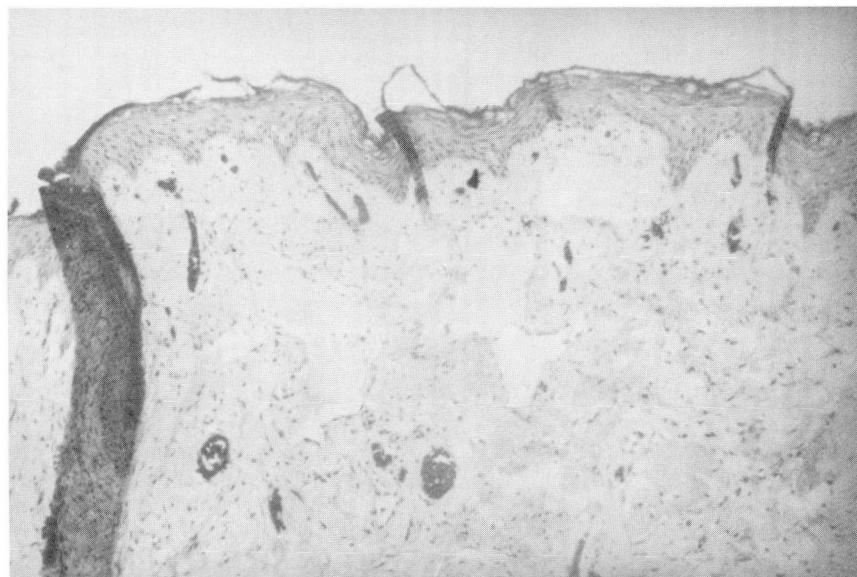


Fig. 2. Foreskin specimen. Dilation of superficial lymphatics is shown (×40).

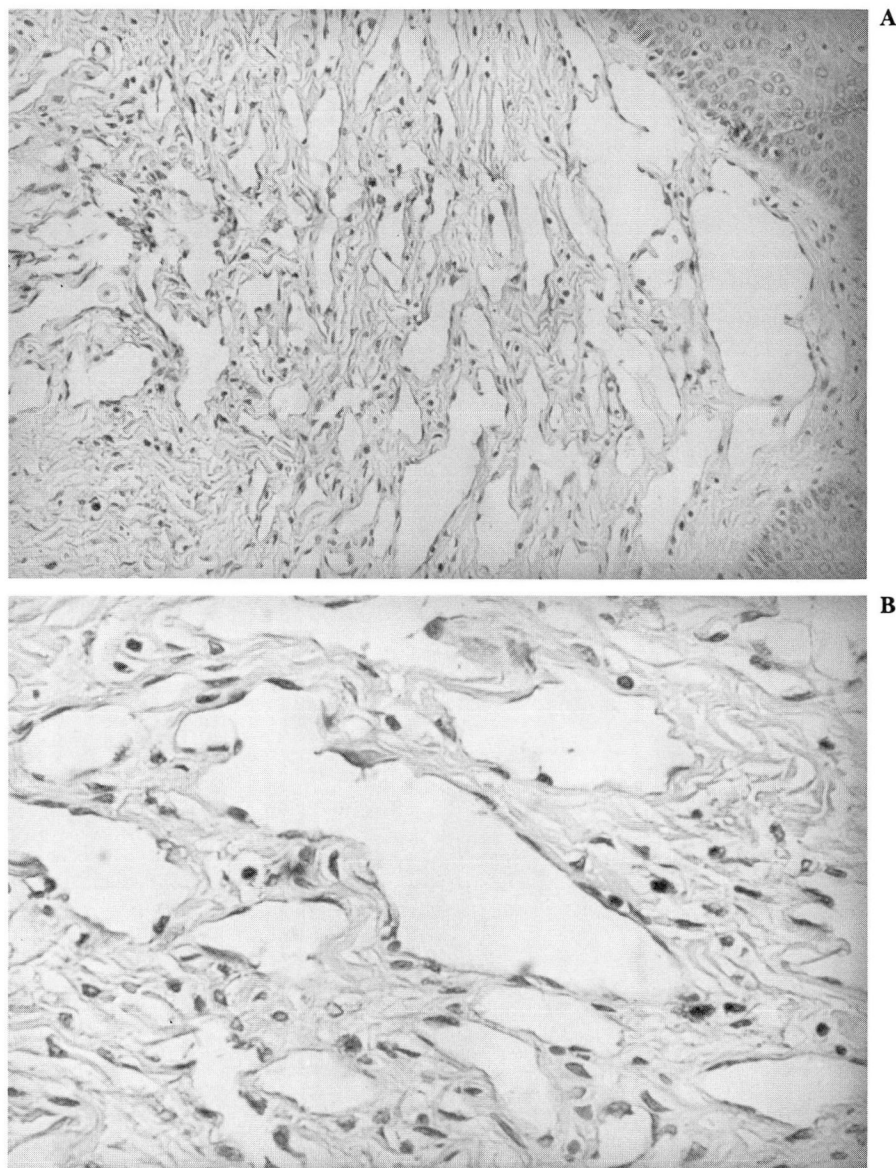


Fig. 3. A and B. Foreskin biopsy specimen. Note the increased amount of dilated vascular space (A, $\times 100$; B, $\times 250$).

ically nonedematous skin of both thighs, the suprapubic area, and the left arm, in addition to the lymphedematous swelling of the genitalia and right arm. The combination of congenital lymphedema of both the genitalia and upper extremities was described in four children (two boys and two girls) by Fonkalsrud in 1977.⁴ Two patients also had intestinal lymphangiectasias. These widespread lymphatic malformations might be more common in congenital lymphedema of the upper extremities than in cases

involving the lower extremities.⁴ As yet, there is no indication of any such systemic involvement in our patient.

Reports of lymphangiosarcoma in congenital lymphedema, analogous to Stewart-Treves syndrome in post-radical mastectomy lymphedema, are increasing.^{5,8-10} It probably takes at least 20 years for this complication to develop.⁵ In our patient, no atypical histological changes were noticed in the biopsy specimens. However, the penile skin showed a progression from simple

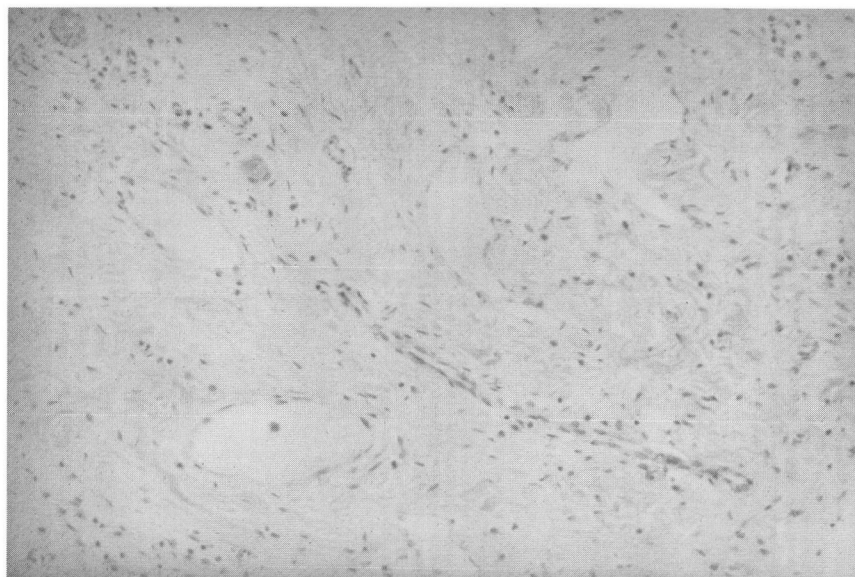


Fig. 4. Skin biopsy specimen of the left arm. Dilated lymphatics are in the superficial and deep dermis ($\times 100$).

lymphangiectasia at one month of age to lymphangiomatous changes one-and-a-half years later.

These changes, together with the increased dermal fibrosis, are consistent with previously described microscopic findings in congenital lymphedema.³

Conservative treatment is usually unsatisfactory,⁴ as it was in our patient. Several surgical approaches have been recommended^{2,4,11} which are probably best performed when the patient is two years old.⁴ It is imperative that all fibrotic and lymphedematous tissue be removed and coverage of the penis be accomplished with residual penile skin or harvested skin grafts.

Wilma F. Bergfeld, M.D.
Department of Dermatology
The Cleveland Clinic Foundation
9500 Euclid Ave.
Cleveland OH 44106

References

1. Kinmouth JB, Taylor GW, Tracy GD, Marsh JD. Primary lymphoedema. *Br J Surg* 1957; **45**:1-10.
2. Feins NR. A new surgical technique for lymphedema of the penis and scrotum. *J Pediatr Surg* 1980; **15**:787-789.
3. Fonkalsrud EW, Coulson WF. Management of congenital lymphedema in infants and children. *Ann Surg* 1972; **177**:280-285.
4. Fonkalsrud EW. A syndrome of congenital lymphedema of the upper extremity and associated systemic lymphatic malformations. *Surg Gynecol Obstet* 1977; **145**:228-234.
5. Dubin HV, Creehan EP, Headington JT. Lymphangiosarcoma and congenital lymphedema of the extremity. *Arch Dermatol* 1974; **110**:608-614.
6. Taylor JS, Young JR. The swollen limb. *Cutis* 1978; **21**:553-560.
7. Kinmouth JB. *The Lymphatics: Diseases, Lymphography and Surgery*. Baltimore, Williams & Wilkins, 1972, pp 194-219.
8. Mackenzie DH. Lymphangiosarcoma arising in chronic congenital and idiopathic lymphoedema. *J Clin Pathol* 1971; **24**:524-529.
9. Merrick TA, Erlandson RA, Hajdu SI. Lymphangiosarcoma of a congenitally lymphedematous arm. *Arch Pathol* 1971; **91**:365-371.
10. Laskas JJ, Shelley WB, Wood MG. Lymphangiosarcoma arising in congenital lymphedema. *Arch Dermatol* 1975; **111**:86-89.
11. Tapper D, Eraklis AJ, Colodny AH, Schwartz M. Congenital lymphedema of the penis: a method of reconstruction. *J Pediatr Surg* 1980; **15**:481-485.