

# Exertional angina pectoris associated with post-exercise ST segment elevation and nearly normal coronary arteries<sup>1</sup>

H. David Millit, M.D.  
Rajesh Gaglani, M.D.<sup>2</sup>  
James P. Antalis, M.D.<sup>3</sup>

**The authors describe a patient with effort-induced angina pectoris and nearly normal coronary arteries who had ST segment elevation after stress ECG in the postexercise recovery period. The patient experienced angina only during exercise. Exercise-induced ST segment elevation, although uncommon, may be secondary to a variety of causes. Selective coronary angiography is often indicated for the diagnosis and appropriate management of the patient.**

**Index terms:** Angina pectoris • Coronary vessels • Electrocardiography

**Cleve Clin Q** 51:71–75, Spring 1984

The traditional value of stress electrocardiography in the evaluation of chest pain has been the documentation of exercise-induced ST segment depression. Recently, there has been renewed interest in ST segment elevation at rest, with exercise, and in the postexercise period. We wish to describe a patient with only effort-induced angina pectoris and nearly normal coronary arteries who exhibited ST segment elevation after stress ECG in the postexercise period.

## Case report

A 38-year-old white man presented to Wheeling Hospital, Wheeling, West Virginia, with a two-year history of chest

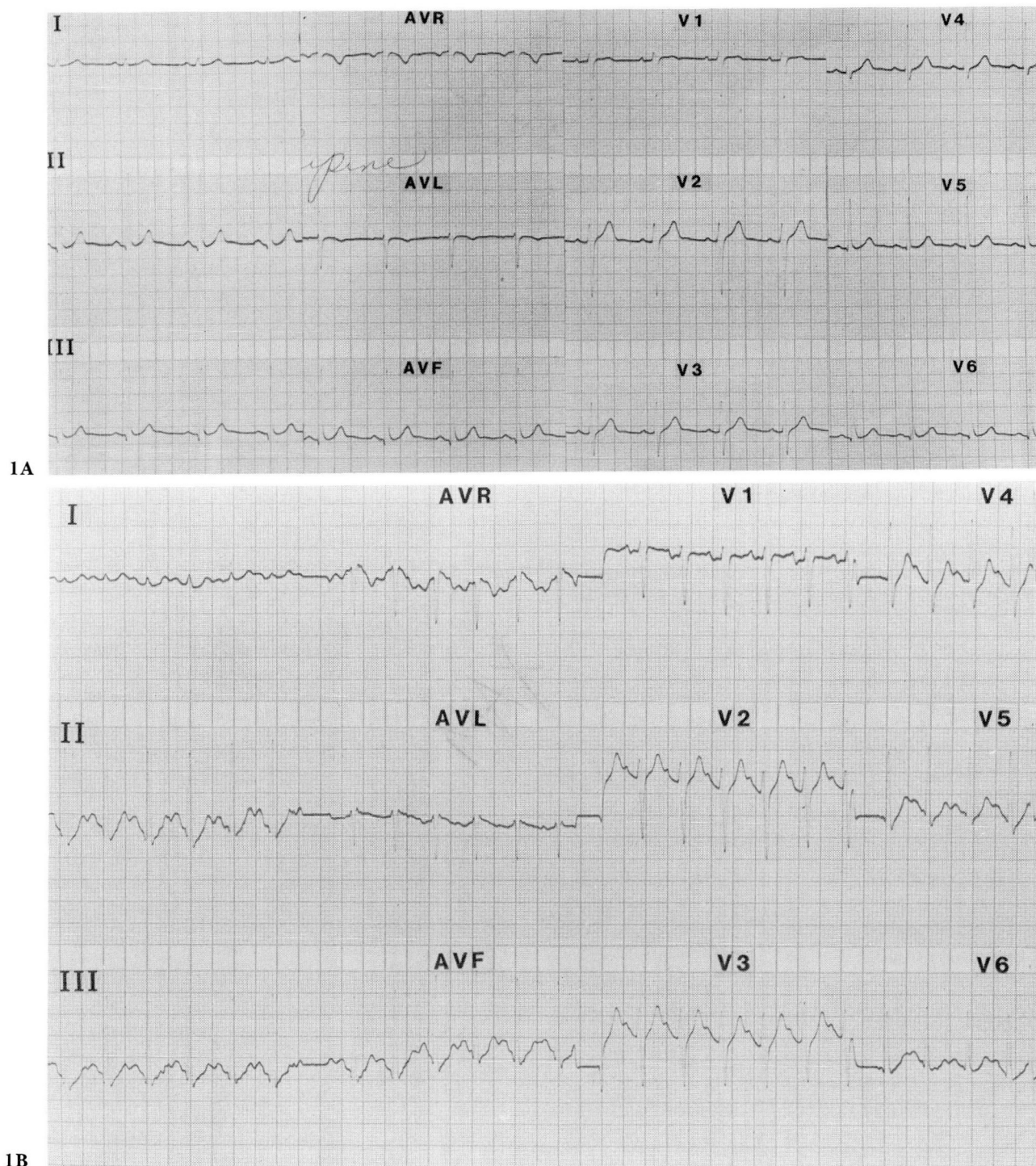
discomfort and occasional palpitations. On each occasion, the chest discomfort was precipitated by exertion and relieved within ten minutes by rest. The patient denied any episodes of nonexertional chest discomfort, and his only other complaint was intermittent heart pounding, or skipping. Results of physical examination were essentially normal. Blood pressure was 120/80 mm Hg; pulse was 70 beat/min and regular. There was no jugular venous distension, and carotid upstroke was normal. Lungs were clear. Cardiac examination revealed normal heart tones and an apical S<sub>4</sub>. The remainder of the examination was unremarkable. A Holter monitor documented sinus rhythm (SR) with periods of symptomatic ventricular bigeminy; no chest discomfort or repolarization changes were noted during the monitor period. A resting ECG was normal.

The patient's symptomatic rhythm disturbance was controlled with disopyramide phosphate (Norpace), and he was given nitroglycerin for use as necessary. His activities were limited until cardiac workup could be completed, and he remained free of pain until stress testing. At that time, he underwent a graded treadmill exercise test using the Naughton protocol. Twelve-lead ECGs were recorded every minute with continuous monitoring of lead V<sub>3</sub>. The patient exercised for 12 minutes to a heart rate of 164 beat/min without chest discomfort or abnormal ECG response (*Fig. 1*), with termination of the test because of dyspnea. Occasional premature ventricular contractions (PVCs) were noted at rest, which did not increase in frequency with exercise. At one minute into the recovery period, while supine, the patient exhibited ST segment elevation, and by two minutes he complained of his typical "chest pain." Further ST segment elevation to a maximum of 9 mm had occurred by three minutes into the recovery period, with an injury current noted in leads II, III, aV<sub>F</sub>, V<sub>5</sub>, and V<sub>6</sub> (*Fig. 2*). He was given nitroglycerin for what was thought to be exercise-induced coronary artery spasm, with complete resolution of the chest discomfort and ECG changes over the next 15 minutes (*Fig. 3*). The patient was hospitalized in view of the acute ECG changes, but no evidence of myocar-

<sup>1</sup> Cardiology Specialists, Ltd. (H.D.M.), Professional Center, Medical Park, Wheeling, WV 26003. Submitted for publication April 1983; accepted July 1983.

<sup>2</sup> Dr. Gaglani is a Cardiology Fellow at Mount Carmel Medical Center, Columbus, OH.

<sup>3</sup> Dr. Antalis is a family practitioner in Shadyside, OH.



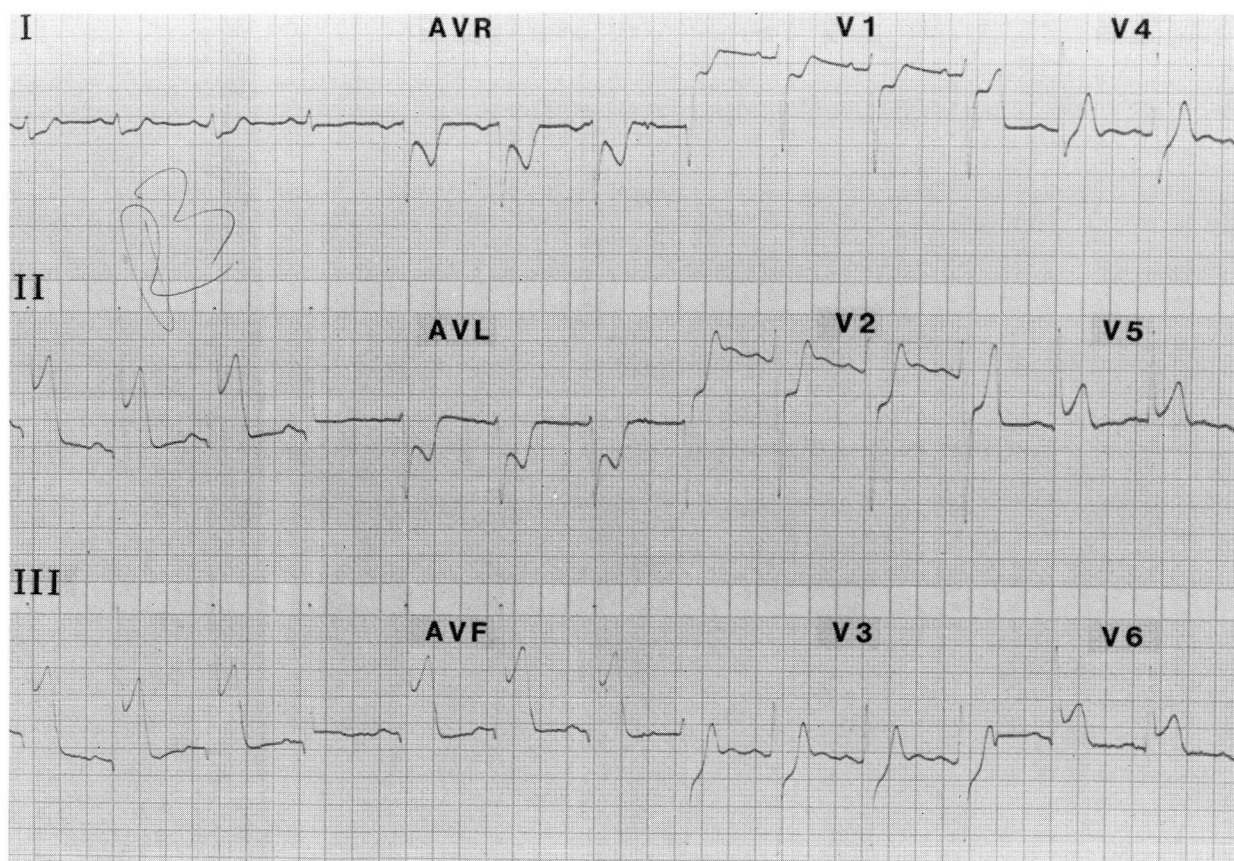
**Fig. 1.** Electrocardiograms taken (A) prior to exercise and (B) at maximum effort. Resting tracing was unremarkable with normal electrocardiographic response noted at termination of exercise.

dial infarction was demonstrated by either enzyme or ECG criteria.

The patient was thereafter started on a course of long-acting nitrates and referred for coronary angiography. Angiograms revealed a 30% stenosis in the middle third of the dominant right coronary artery, an essentially normal left

coronary artery system, and normal left ventriculogram. Although often used to document coronary artery spasm, ergonovine maleate testing was not performed at the time of the catheterization because of the prior ECG documentation of the ST segment elevation. In view of the angiographic findings and the lead location of the injury current





**Fig. 2.** Electrocardiogram taken at three minutes of recovery with patient complaining of chest discomfort demonstrates injury current in the inferolateral leads.

occurring after exercise, we thought that spasm of the right coronary artery was responsible for the patient's discomfort. He was given nifedipine 10 mg po q 8 hr. Two days after initiation of calcium-blocking therapy, a repeat stress ECG was completely normal. Subsequently, the patient has returned to his usual activities with no further episodes of chest discomfort.

### Discussion

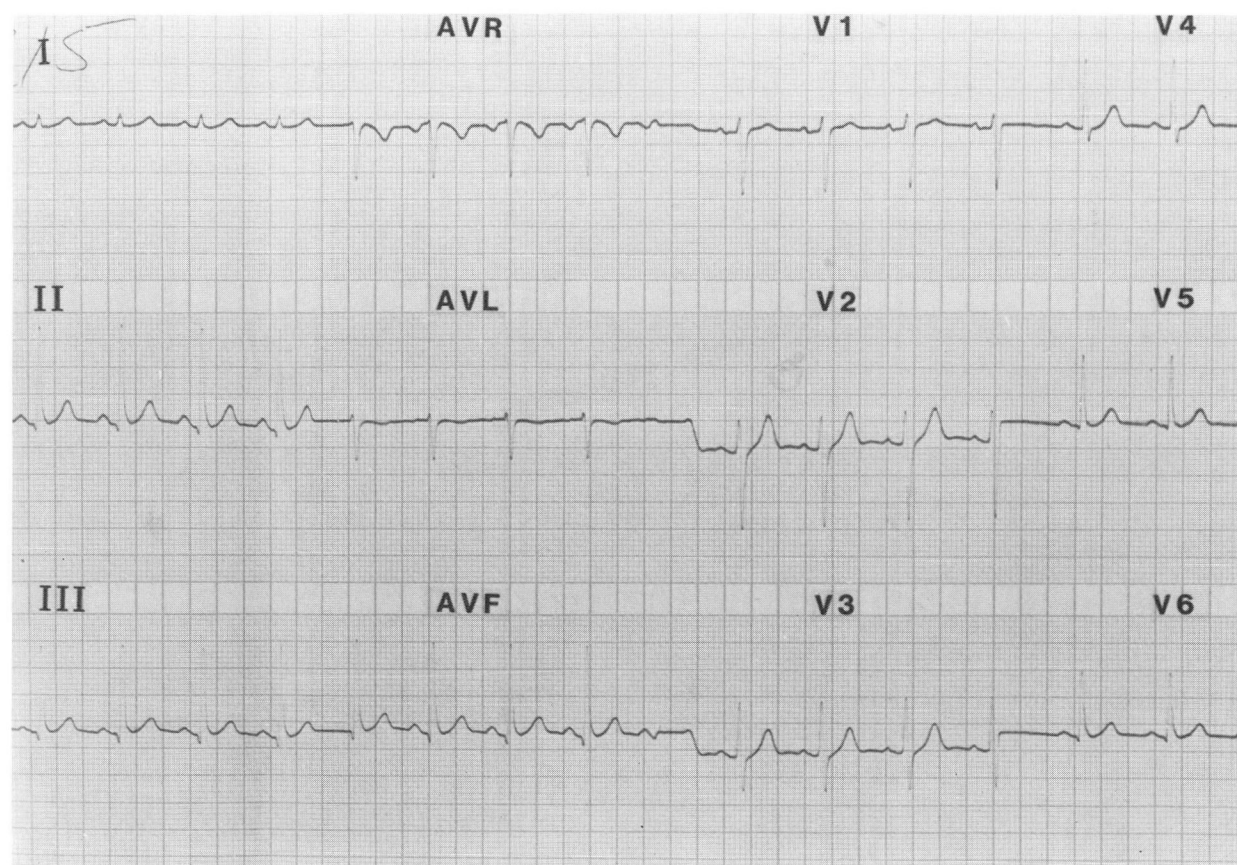
This case represents the rather unusual situation of "classic" or effort-induced angina pectoris associated with what is usually not considered hemodynamically significant coronary artery stenosis. In our patient, the absence of rest pain prior to stress ECG made the likelihood of coronary artery spasm seem remote, but the attempt to demonstrate exercise-induced ECG changes resulted in ST segment elevation during the recovery period rather than ST segment depression during maximal myocardial oxygen consumption. This case demonstrates the difficulty sometimes encountered when attempting to use the history to differentiate fixed coronary artery obstruction, coronary artery spasm, and coronary

artery spasm superimposed on fixed obstruction. One should consider all of these possibilities when confronted with the diagnosis of angina pectoris, although the history usually suggests the predominant mechanism.

Angina occurring during exertion is explainable on the basis of fixed coronary artery obstruction and is most often secondary to coronary atherosclerosis. Pain occurs because myocardial oxygen supply cannot increase proportionally to demand. The ECG manifestation is ST segment depression. Angina occurring at rest and associated with ST segment elevation was recognized by Prinzmetal et al<sup>1</sup> to result from a different mechanism, that of coronary artery spasm. This entity is now well accepted and has been documented angiographically.<sup>2</sup> Both mechanisms may be operative in the same patient.

In the noninvasive laboratory, one may be able to precipitate ST segment elevation with exercise.<sup>3-10</sup> This finding is uncommon, the reported prevalence ranging from 2%<sup>11</sup> to 3.5%.<sup>6</sup> Chahine et al<sup>6</sup> reviewed 29 cases of ST segment elevation





**Fig. 3.** Electrocardiogram taken at 15 minutes of recovery after patient had received sublingual nitroglycerine. Tracing has returned to normal.

occurring during exercise and suggested that in addition to coronary artery spasm, ST segment elevation may be secondary to anterior myocardial infarction, critical proximal left anterior descending coronary artery obstruction, and left ventricular apical aneurysm. ST segment elevation occurring only during the postexercise period has most often been seen in patients with some history of rest pain, which leads one to suspect underlying coronary artery spasm. Weiner et al<sup>12</sup> have documented postexercise ST segment elevation in 4 patients, 3 describing rest pain and 2 with fixed coronary artery obstruction. His second patient was similar to ours, both admitting to exertional chest discomfort only and both without significant fixed coronary artery obstructions. The case described by McLaughlin et al<sup>13</sup> (chest pain after exertion) agreed more closely with the temporal relation of ST segment elevation occurring after an exercise test, coronary arteriography in that case revealing normal coronary arteries with spasm induced by ergonovine maleate. Others<sup>4, 14</sup> have also documented ST

segment elevation occurring after exercise, but those cases represent severe coronary atherosclerosis with imminent myocardial infarction or death.

The prognostic implication of exercise-induced ST segment elevation is not entirely clear. Lahiri et al<sup>8</sup> described 5 patients with angina who exhibited ST segment depression during treadmill exercise testing followed by ST segment elevation and chest pain in the postexercise period. Three of these 5 patients experienced myocardial infarction within eight weeks of the exercise test, and 2 died. All 5 patients demonstrated significant coronary atherosclerosis. In another study<sup>10</sup> of 82 patients with variant angina, 25 had ST segment elevation during exercise, and 3 of these sustained myocardial infarctions within three months of the exercise test. Two of the 3 had severe coronary atherosclerosis, and both died suddenly. Cipriano et al<sup>15</sup> observed a group of 25 patients for a mean of 2.7 years after documented coronary artery spasm. A more serious prognosis was associated with significant

fixed coronary artery narrowing than with normal or nearly normal coronary arteries.

Coronary artery spasm may be implicated in almost all of the different clinical manifestations of myocardial ischemia, may or may not be associated with fixed coronary artery obstruction, and may lead to ST segment elevation either in the exercise or postexercise period. Every effort should be made to define the underlying mechanism of the anginal syndrome in a given individual, since this may help to determine proper therapy. Worsening of angina pectoris associated with high doses of beta blocker may even suggest coronary artery spasm.<sup>16</sup> Apart from exercise testing, a 24-hour recording of ambulatory ECGs demonstrating ST segment elevation may be useful in the detection of coronary artery spasm. More recently, transtelephonic monitoring<sup>17</sup> has been suggested for the patient with extremely infrequent episodes of resting angina pectoris. Finally, coronary arteriography with interventions such as ergonovine maleate<sup>18</sup> or cold pressor testing<sup>19</sup> may have to be included in the investigation of the anginal syndrome to define the true physiologic mechanism.

## References

1. Prinzmetal M, Kenamer R, Merliss R, Wada T, Naci B. Angina pectoris. I. A variant form of angina pectoris. *Am J Med* 1959; **27**:375-388.
2. Oliva PB, Potts DE, Pluss RG. Coronary arterial spasm in Prinzmetal angina. Documentation by coronary arteriography. *New Engl J Med* 1973; **288**:745-751.
3. Fortuin NJ, Friesinger GC. Exercise-induced S-T segment elevation. Clinical, electrocardiographic and arteriographic studies in twelve patients. *Am J Med* 1970; **49**:459-464.
4. Kemp GL. Value of treadmill stress testing in variant angina pectoris. *Am J Cardiol* 1972; **30**:781-783.
5. Detry J-MR, Mengeot P, Rousseau MF, Cosyns J, Ponlot R, Brasseur LA. Maximal exercise testing in patients with spontaneous angina pectoris associated with transient ST segment elevation. Risks and electrocardiographic findings. *Br Heart J* 1975; **37**:897-903.
6. Chahine RA, Raizner AE, Ishimori T. The clinical significance of exercise-induced ST-segment elevation. *Circulation* 1976; **54**:209-213.
7. Specchia G, De Servi S, Falcone C, et al. Coronary arterial spasm as a cause of exercise-induced ST-segment elevation in patients with variant angina. *Circulation* 1979; **59**:948-954.
8. Lahiri A, Subramanian B, Millar-Craig M, Crawley J, Raftery EB. Exercise-induced S-T segment elevation in variant angina. *Am J Cardiol* 1980; **45**:887-894.
9. Sriwattanakomen S, Ticzon AR, Zubritzky SA, et al. S-T segment elevation during exercise: electrocardiographic and arteriographic correlation in 38 patients. *Am J Cardiol* 1980; **45**:762-768.
10. Waters DD, Szlachet J, Bourassa MG, Scholl J-M, Théroux P. Exercise testing in patients with variant angina: results, correlation with clinical and angiographic features and prognostic significance. *Circulation* 1982; **65**:265-274.
11. Bruce RA, Gey GO, Cooper MN, Fisher LD, Peterson DR. Seattle heart watch: initial clinical, circulatory and electrocardiographic responses to maximal exercise. *Am J Cardiol* 1974; **33**:459-469.
12. Weiner DA, Schick EC, Hood WB, Ryan TJ. ST-segment elevation during recovery from exercise. A new manifestation of Prinzmetal's variant angina. *Chest* 1978; **74**:133-138.
13. McLaughlin PR, Doherty PW, Martin RP, Goris ML, Harrison DC. Myocardial imaging in a patient with reproducible variant angina. *Am J Cardiol* 1977; **39**:126-129.
14. Sweet RL, Sheffield LT. Myocardial infarction after exercise-induced electrocardiographic changes in a patient with variant angina pectoris. *Am J Cardiol* 1974; **33**:813-817.
15. Cipriano PR, Koch FH, Rosenthal SJ, Schroeder JS. Clinical course of patients following the demonstration of coronary artery spasm by angiography. *Am Heart J* 1981; **101**:127-134.
16. Robertson RM, Wood AJJ, Vaughn WK, Robertson D. Exacerbation of vasotonic angina pectoris by propranolol. *Circulation* 1982; **65**:281-285.
17. Ginsburg R, Lamb IH, Schroeder JS, Harrison DC. Long-term transtelephonic electrocardiographic monitoring in the detection and evaluation of variant angina. *Am Heart J* 1981; **102**:196-201.
18. Heupler FA, Proudfit WL, Razavi M, Shirey EK, Greenstreet R, Sheldon WC. Ergonovine maleate provocative test for coronary arterial spasm. *Am J Cardiol* 1978; **41**:631-640.
19. Raizner AE, Chahine RA, Ishimori T, et al. Provocation of coronary artery spasm by the cold pressor test. Hemodynamic, arteriographic and quantitative angiographic observations. *Circulation* 1980; **62**:925-932.