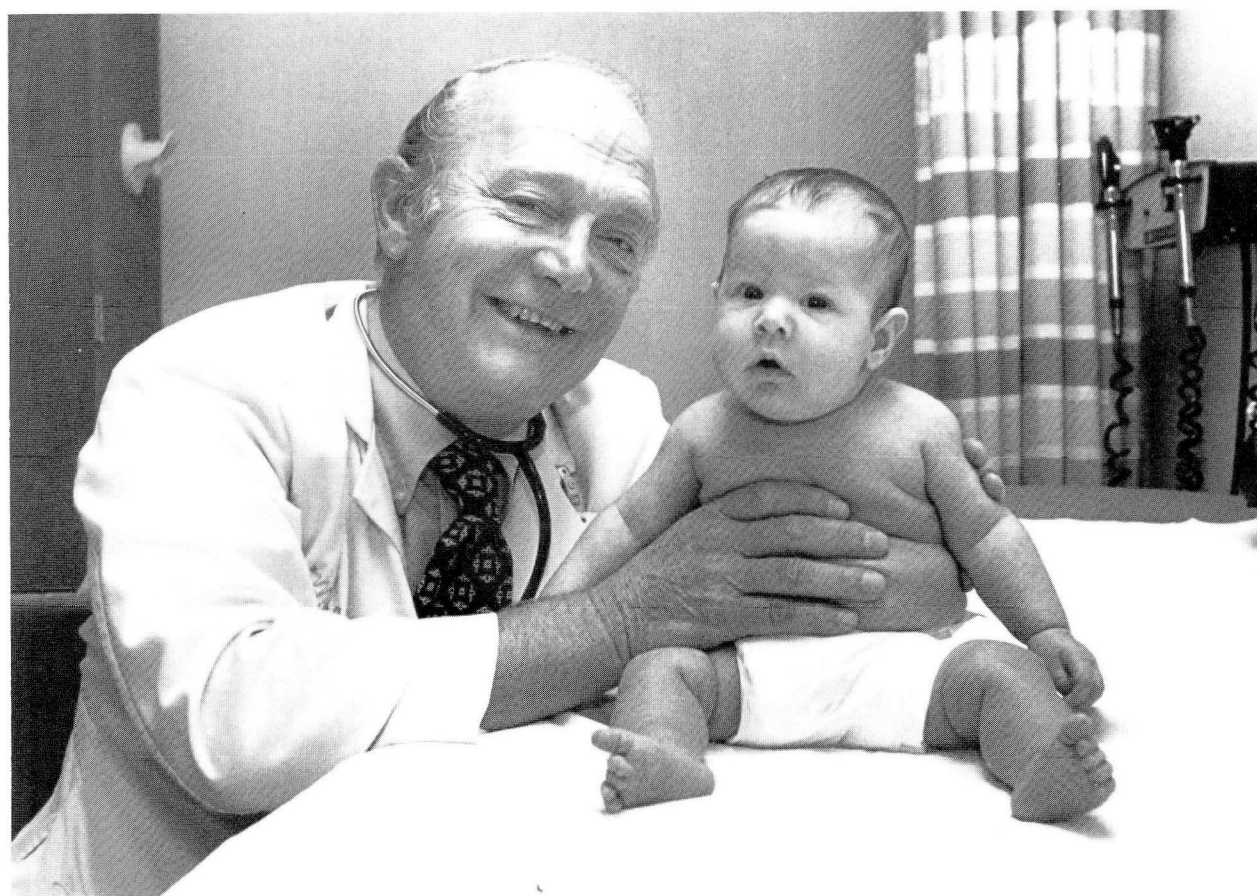


How to examine a baby or a small child and keep your cool

Robert D. Mercer, M.D.¹



Robert Dean Mercer, M.D., and small friend.

The examination of a baby can be a pleasant experience if the physician has nothing against babies and is not intimidated by them. Every examination is preceded by a thorough medical

history. It is best to take the history from the parents since the baby seldom understands the questions. Grandparents who are present must be ignored. They are really testing to see if you agree with their diagnosis. Grandparents should be politely, but firmly, pushed out of the room. Fathers can also be ignored. They usually know

¹ Senior physician, Department of Pediatric and Adolescent Medicine, The Cleveland Clinic Foundation. Dr. Mercer retired in December 1982.

the name and the sex of the baby but little else. They may be allowed to stay in the room if they sit quietly out of the way.

The details of the medical history are not the purpose of this paper. It is like any other history, with additional attention to the pregnancy, birth, newborn period, and the development of the baby. Physical and intellectual development go hand in hand. If a baby walks by 10 months of age, the child will usually do well in school. My best advice is that you listen carefully to what the mother has to say. She has been living with the baby, and her observations are usually correct. Write down the mother's chief complaint, and write it verbatim if you can. This is instructive and sometimes amusing. If the complaint is "colic," the mother means that the baby has paroxysmal fussiness, which may mean nothing, indigestion, brain damage, or a nervous and irritable mother who upsets her baby. If the complaint is "bealed ears," this specifically means acute or chronic otitis media. If the only complaint is that the mother wants you to do a "complete examination," she means that she wants you to inspect the genitalia. She may be startled if you do a rectal examination. Mothers can usually supply exhaustive details about their babies with correct dates and times for everything you wish to know and much that you do not. Look out for the mother who can supply no data about birth weight or the landmarks of development. Such a mother is either mentally ill or criminally neglectful.

The examination begins with the attire of the physician. All Boston-trained pediatricians wear bow ties. I think this is because Dr. Charles Janeway wore a bow tie, but they claim it is to protect their tie from being soiled by any of the products of the baby. A well-buttoned white coat will do as well. Only baby boys are really dangerous, and they are more apt to get you in the face. This knowledge keeps the physician observant and alert.

Hand-washing is the next step. There is something religious and mystical about hand-washing, and it is to be done whether your hands are dirty or not. Parents expect this. The result of hand-washing is that your hands get cold, which can make the baby cry and ruin your day. Never wash your hands if your purpose is to check for undescended testicles. Cold hands have a remarkable effect on the cremasteric reflex!

It pays to be observant when you approach the baby. If he is happy and relaxed, things will

probably go well. If the baby is frightened and suspicious, you might let him stay in the mother's lap while you make social contact. Smile and be friendly. Offer a present. I usually offer a tongue blade since it really does not matter what you offer as long as you offer something. Talk to the baby. It does not destroy your dignity to act a little like a grandfather or an auntie if by so doing you gain some cooperation. The difference in the quality of your examination of a happy, friendly baby over the baby who is screaming and fighting is so great that anything you can do to gain friendship is justified even if you look a little silly.

I often nod my head in a "yes" or "no" fashion while talking to a baby. Whether it is because I have a bald head or because I wear glasses, I do not know, but the baby often becomes so involved in following my movements that he forgets about being frightened. I think snake charmers use this technique. I usually ask the baby to tell me about his troubles. When the baby smiles and wiggles his feet and vocalizes in return, everyone feels good about it. The older child responds equally well to compliments. I usually ask little girls if they know how pretty they are and little boys if they know how good they are. So far, everyone has answered in the affirmative.

Start your examination with the feet. I am not really sure why you should, but I was told to do this about 40 years ago by Dr. James Wilson, and it seems to work. Babies seem to like to have their feet played with. If they object to this, you are in trouble all the way. You might even find something. Forefoot varus is best seen by holding the feet up and looking at the plantar surfaces. Hallux valgus is best seen from the tops of the feet. Pay no attention to flat feet, minor degrees of pronation, or minor syndactyly. None of these need treatment. The lower legs of a baby are often bowed a little in association with intrauterine position. This is usually self-correcting. Severe tibial torsion requires the help of an orthopedist.

The deep tendon reflexes come next. I percuss with my index finger for the patellar tendon and use a reflex hammer on the Achilles tendon and about the elbow. So far, this examination has been absolutely worthless except in an infant with obvious neurologic disease. It is a waste of time on a healthy-looking baby but seems to be expected and does help you establish friendly contact.

Always examine the hips carefully. It is tragic

to miss the diagnosis of a dysplastic or dislocated hip. Resistance to abduction and asymmetry is the key to this diagnosis. Roentgenograms are needed for confirmation. Dysplasia and/or dislocation of the hip is associated with an apparent discrepancy in the length of the legs and asymmetry of the skin folds of the upper legs and buttocks. Asymmetry of the skin folds may be seen in normal children, but such asymmetry does indicate special care in your examination.

Palpate the femoral artery while you are in this region. This is not always easy with a fat little baby, and it is embarrassing to miss a coarctation of the aorta. If you have problems, cross-check with the blood pressures in the arms and the legs. If you still have problems, ask someone else to check the examination.

Look at the genitals and the anus. Most of the mistakes in diagnosis I have seen have been made just because nobody looked. When you see the testicles in the scrotum, there is no need for further palpation. If the chief complaint is related to undescended testes, you will need a bit of extra skill in your examination. Make sure your hands are warm. Skip all of the preliminaries and examine the testicles first. Remove the diaper or underpants without touching the skin. Your first contact is to place the thumb and index finger of your left hand in position to block the inguinal canals. This leaves those little mice with no holes to hide in, and locating them with your right hand is easy. Before you decide the testes are undescended, get the little boy in position so that he is standing on his knees. For some reason or other, this releases the cremasteric reflex, and the testes, if present, will appear in the scrotum. Always demonstrate the testicles to the parents so that they will believe you.

If the complaint has to do with a small penis in a fat little boy, don't believe it. Micropenis does exist, but it is exceedingly rare. Just push back the pubic fat, and you will generally demonstrate a perfectly normal penis. Show this to the parents. They will feel relief and pride. Look at the vaginal opening in little girls. Check the size of the clitoris. An enlarged clitoris means overproduction of adrenal gland hormones. A pseudovaginal atresia due to sealed labia minora is not uncommon. Usually no treatment is needed. If you happen to be examining the baby as a "pre-operative clearance" when she is scheduled for surgery for supposed vaginal atresia, by all means fix it yourself. You can do this easily by stroking the area with the smooth tip of a glass thermom-

eter and with the help of lubricating jelly. Your success will ruin the surgeon's day.

You may miss a true vaginal atresia since a short vaginal cavity can be present in this condition. An excellent view of the vaginal cavity can be obtained with the infant or little girl in the knee-chest position. Vaginoscopy with an otoscope and an ear speculum is sometimes recommended, but when I think that sort of examination is needed, I refer to a pediatric gynecologist or at least to someone that I can trust to be gentle.

Look at the anus. It may not be there in a newborn, and your reputation is better if you find out about this before the nurse does when she tries to take the rectal temperature. The anus may be apparently displaced forward on the perineum. If so, it is probably not an anus at all but an imperforate anus with a perineal fistula. I was once consulted because a baby had "two anuses." This was a baby with a normal-looking anus but a short blunt-ended anal canal plus a perineal fistula. No one deserves more than one anus.

A "routine" rectal examination is not indicated in babies and small children. A rectal examination should be done only if something in the history or physical examination justifies the procedure. Use lots of lubrication and be gentle. Don't push your finger in there in a hurry. You would not like that either. Just a little pressure on the anus plus a little patience will result in relaxation of the sphincter. With an older child, this is a good time to get the patient actively engaged in conversation. When people are busy talking, they don't seem to worry about what is going on at the other end.

Abdominal examination of the child is easy. Look before you touch. When a tumor is present, it can often be seen. This is particularly true of Wilms' tumor, which tends to be large. Distention of the bowel and peristaltic waves can be seen in patients with pyloric stenosis or other types of bowel obstruction. Great distention means great accumulation of air in the intestinal tract—in a baby who chokes while feeding, this may mean the presence of an H-type tracheoesophageal fistula. The fistula is a two-way passage. Babies choke as fluid flows from the esophagus to the trachea, and they also become distended as air is pumped into the esophagus. For no logical reason, the air tends to traverse the entire intestinal tract instead of seeking the short way out in a burp. The passage of flatus may be spectacular and disturb the neighbors.

Examination of the chest is also easy. Again, look before you touch. Marked asymmetry may be associated with pulmonary agenesis or, conversely, with unilobar emphysema. Babies often have a gynecomastia, a reminder of the mother's active hormones. Breast enlargement related to precocious sexual development may be seen in very young girls. This is often asymmetrical and is seldom associated with endocrine disease. A very small nipple and agenesis of the pectoralis major muscle on the same side usually means agenesis of breast tissue on that side. This is a disaster for the female, and plans can be made for appropriate surgical help when she matures. The combination of agenesis of the breast, small nipple, absence of the pectoralis major muscle, and a poorly developed arm and hand on the same side is known as the Poland anomaly. This has nothing to do with ethnic jokes but is named for Mr. Alfred Poland, an anatomist of Guy's Hospital, London, in 1841.

The only problem with auscultation of the lungs and heart is that you hear too much. It helps if you use a stethoscope with a relatively small head. The breath sounds of a small baby are best heard if the baby is held on the mother's shoulder, facing her in the customary fashion. As a matter of fact, I often do most of the examination when the baby is on the mother's lap feeling safe and secure. I put the baby back on the table to examine the throat—at that point, friendship is abandoned—but loud yelling helps you to see the anatomy.

A mother likes to pat the baby held on her shoulder, but this has to be stopped if you value your eardrums. Nevertheless, even a crying baby is best examined in the over-the-shoulder position. Crying is associated with nice deep inspirations, and that is the time you listen for breath sounds. The heart is also easy to examine in infants. It is a good idea to learn to recognize some of the more common murmurs. I will not discuss murmurs in detail, but I would warn you not to be too certain that a given murmur is innocent. An echocardiogram is easy to obtain, and the diagnosis of ventricular septal defect has been made much more frequently since this technique has been available.

It is worthwhile for you to be able to recognize the innocent venous flow murmur. This sounds much like a ductus arteriosus but is most prominent at the right base rather than at the left and changes character markedly as the position of the

baby is changed from supine to erect. I once had a baby referred from Peru for surgical correction of a ductus when there was only an innocent venous hum present. It was very embarrassing to tell these people that the long trip was for nothing, and there were some vague remarks made about the beneficial effects of high altitude on heart murmurs as well as the reassurance that their baby needed no operation.

Necks are interesting. If you dislike litigation, it is wise to check a febrile baby's neck for the stiffness of meningitis. Note the position of the baby's head. If the head remains constantly tilted to one side, torticollis is present. Palpation of the sternocleidomastoid muscle on the side to which the head is turned will reveal a tight muscle and sometimes a small, firm mass in the muscle. This can be relieved with physical therapy if recognized early. It is really a nuisance if recognized late since surgery will be needed, and the baby's head and face rapidly become asymmetrical when held constantly in one position. Look for little pits or dimples along the sides of the neck. These indicate branchial cleft remnants. Check the anterior midline of the neck for the dimple or cyst of a thyroglossal duct remnant.

The face itself is next. Not all babies are cute and pretty, and you should at least be curious if they are not. First look at the parents. Neanderthals beget Neanderthals, and this may be the answer. The heavy dull face and large tongue of a cretin should be recognized as early as possible for replacement thyroid therapy. The heavy dull face and prominent brows of Hurler's syndrome or other varieties of storage disease may be rather subtle in the young baby and very obvious as he or she grows older. If a baby looks cretinoid and has a very large tongue but is a big baby, it probably has the Beckwith-Wiedemann syndrome. Cretins or seriously hypothyroid babies do not grow well. It also pays to learn to recognize fetal alcohol syndrome. As you learn to recognize the narrow eyes and thin upper lip in a child of small stature with delayed development, you will make this diagnosis more and more frequently. There are literally hundreds of syndromes that you can diagnose by characteristic facial features, and there are several good books illustrating these conditions. Doctors dealing with children should have access to these references.

You seldom find a surprise when you examine the mouth of a baby. However, it is a good idea

to do so since it seems to be expected of doctors. I often have my left hand on the baby's head in a friendly manner as I am conducting the examination. Then, reaching around the head, I tap or stroke the baby's lower lip as I ask him to open his mouth. When the baby responds normally by opening his mouth to the lip-tapping reflex, it seems that he is minding me, and everyone is happy. A little sleight of hand does no harm. The negative two-year-old may be impossible, and all that you can do is abandon friendship and use brute strength. If he yells loudly enough, you get a good look clear down to the epiglottis. The cooperative older child can bring his epiglottis into view easily. I seldom use a tongue blade with such children.

It seems to me that the ear examination is always easy except when it is really needed; then cerumen is in the way. With a cooperative baby or child, I examine the patient supine on the examination table. A fussy baby is best examined on the mother's lap. It is then convenient for the mother to help restrain the child. The child's head should be on the mother's right shoulder as you face the mother, sitting a little to her right side. If you try this with the baby's head on the mother's left shoulder, you will find yourself in a very intimate position in respect to the mother's person. This may be misinterpreted by strangers passing down the hall.

I usually examine the ears with just the light and magnifying glass of the Welch-Allyn otoscope and do not use an ear speculum. I open the ear canal by grasping the ear gently with my thumb and index finger while pushing forward on the area of the tragus with my middle finger. In most babies and children, you can see the drum reasonably well without putting an instrument into the ear canal. I usually get the baby to look in the direction I wish by using the otoscope as an attractive object and then—presto!—move the light quickly into position while the baby wonders where it went.

Fundoscopy can be frustrating. I start with a general inspection using the magnifying otoscope with no speculum. Next comes the ophthalmoscope. You should at least identify the normal red pupillary reflex. If anything like the reflex of a cat's eye shines back at you, the patient is in trouble, and you need an ophthalmologist. Major cataracts are also obvious. With care you can see the edge of a dislocated lens in the patient with Marfan's syndrome or homocystinuria. I survey

all patients with the pupil undilated and dilate the pupil only when I feel there are specific indications. The optic disc can almost always be seen, but the periphery of the retina cannot be seen unless the pupil is dilated. Older children will look where you ask them to look; little children and babies require a great deal of patience. With this examination, it is important to keep your head lateral to and parallel with the patient's head. It is not right for you to ask a patient to look someplace and then put your head exactly in the way so that he cannot follow your instructions. With the patient supine, I stand to the patient's right side, facing the patient. I use my right hand and right eye and move in from the right so that my head covers the minimum of the patient's private space. To examine the left eye I walk to the top of the examining table and, standing at the patient's head, I move in from his left, again using my right hand and right eye. I know you have been taught to use your left hand and left eye when examining the patient's left eye. I can't do it that way since I see much better with my right eye. If you have the same problem and try to look at the left eye of the patient, the result is that you wind up in the kissing position. This is all right with babies, but with older patients you could be in trouble. When you feel this examination is important and you are dealing with a small baby, it is necessary to dilate the pupil. One trick that I use when I am desperate is to put the baby in the mother's lap, get into position, and have the father light a match over my shoulder at a respectable distance from my ear. The baby will usually fix on the flame long enough for me to get a good look.

Somewhere in your examination, remember to check the blood pressure. This is important, and it is the single important examination that is most often omitted. There is no problem at all in taking blood pressures on small children; just make sure the cuff is of an appropriate size. Little babies can be difficult. Again, the cuff should be of an appropriate size, but if you are looking at that very small 1-inch-wide cuff, throw it away. Most of the time this is too small, and you get a falsely elevated blood pressure. When you cannot hear the pulse in a chubby little arm, just feel the pulse. You can almost always do this. It will give you a reasonable approximation of the systolic pressure.

Next is the skin. It makes no difference whether you check the skin at the beginning or

at the end of your examination, but for heaven's sake, check the skin. You should be very familiar with the flat or flame nevus and with the elevated or strawberry nevus. Everybody knows that a flat flame nevus over one side of the face, particularly involving the upper inner eyelid, is associated with Sturge-Weber syndrome. Most people forget that this syndrome is also associated with glaucoma on the involved side. A patient can have a flame nevus plus glaucoma and still not have Sturge-Weber syndrome since there may be nothing whatsoever in the way of vascular malformation in the brain. The Sturge-Weber syndrome is a good thing to keep in mind because it does serve to tell you that the flame nevus may be associated with something hidden. This is also true when the flame nevus is elsewhere, so be careful and search for AV malformations when a large flame nevus is seen. This warning does not generally apply to the strawberry nevus. Most of those are not associated with AV malformations. Check the skin for brown spots, which are also called cafe-au-lait spots. Anybody can have one or two of these with no great significance, but if there are five or six measuring 0.5-cm or larger, this means the child has neurofibromatosis. Neurofibromatosis (von Recklinghausen's disease) is a common dominant trait of great importance. Hypopigmented spots are also common. These should be looked at with a certain degree of suspicion—when plentiful, they may be pathognomonic for tuberous sclerosis. The hypopigmented spot in tuberous sclerosis has the lanceolate shape of an ash leaf. Any baby with hypopigmented spots and convulsions probably has tuberous sclerosis. Look also at the fingernails. An abnormally thickened appearance and pitting of the nails is more likely to be the first sign of psoriasis than fungus; however, both must be considered. Be sure to include the hair in your general examination of the skin. Bald spots from alopecia areata may be recognized by the exclamation mark hairs along the edge of the growing border. Young children with sparse hair may be twiddling their hair and pulling it out. This is a nuisance, but if they swallow the hair, it can be a more serious problem since it can collect in the stomach and form a trichobezoar. Curiously twisted and glistening hair looking for all the world like a cheap wig made of plastic is probably pili torti or congenital twisted hair. This in turn may be associated with aminoaciduria and mental retardation and represents Menkes' syndrome.

Look at the patient's back. Scoliosis is not common in small children and babies, and when it is present, it usually indicates a serious malformation of the spine. It may also be associated with devastating central nervous system abnormalities such as cerebral palsy. Check the entire midline of the back. A small flame nevus is often present at the occiput. This is also sometimes called a salmon patch or, by grandmothers, a stork bite. It has no ominous meaning and can be considered a variation of normal. Pits or dimples along the upper spine, particularly when associated with a little tuft of hair, should always be considered seriously. These are dermal sinuses and can penetrate to the spinal canal. Rarely on the ventral side of the cord there may be an associated neurenteric cyst. If there is the slightest suggestion of neuropathology of the lower extremities, get a CT scan of the area. You are probably looking at a diastematomyelia, a curious anomaly with a spicule of bone separating a partially reduplicated cord. Pits and dimples of the lower sacrum and coccygeal area are developmental anomalies similar to those mentioned in the thoracic or upper lumbar area but are seldom as serious.

Now the end. Remember to look at the buttocks. A good buttocks person can make lots of useful diagnoses, and it can even become a hobby. Prominent buttocks and lumbar lordosis in a black person are normal. It is a remembrance of certain South African tribes. Prominent buttocks, lumbar lordosis, and short extremities in any race are indicative of achondroplasia. Very small buttocks, looking as if they had been added as an afterthought, may be associated with agenesis of the sacrum. Get an x-ray. Asymmetry of the buttocks with one small side and one normal side is a variation of the same thing, and one side of the sacrum may be missing with the other assuming a scimitar-like curve on the x-ray. These may be associated with an anterior myelomeningocele. Dimples on the buttocks are usually due to injections. Large flat hemangiomas of the buttocks may be associated with large arteriovenous malformations of the lower spinal canal. Listen for the continuous murmur at the base of the spine. This combination is the Cobb syndrome.

If the small child is able to walk, encourage him to do so before you finish your examination. You might even discover a mild hemiplegia missed on your standard examination. Check the

feet again as the child walks. If they are rotated outward, ignore it. They will usually straighten in time, and special shoes are not needed. If the feet rotate inward, check your examination of the lower extremities again. You may have missed forefoot varus or tibial torsion. If neither of these conditions is present, look at the kneecaps. When one or both of these are cross-eyed, the child probably has femoral anteversion. This can be diagnosed by checking the legs for excessive inward rotation, and the degree of anteversion can be accurately measured with appropriate x-rays. The best thing you can do about this condition

is ignore it, and it will improve with time. If it does not improve and the child is handicapped by tripping over his own feet, he will need a surgical derotational osteotomy of the femur. This is no small matter. Special shoes are never going to cure this condition; as a matter of fact, I doubt that they cure anything.

Finally, you are done. The real reward of a successful examination is when the small person climbs up into your lap for further friendly play. You know then for sure that you have done a good job and established a new friendship in the process.