

Teratoma of the tongue in a newborn¹

Julia V. Ashley, M.D.²
Alan D. Shafer, M.D.³

A large teratoma of the tongue was removed from an infant 32 hours after birth. Microscopically the tumor contained elements of all three germ layers, with immature neural tissue predominating. There was no histologic evidence of malignancy. Serum markers, initially elevated, are negative two years later. Only four teratomas of the tongue that were present at birth have been reported, which we review here. No malignant teratomas of the tongue in the newborn have been reported; prognosis of teratoma of the tongue in the newborn is unknown.

Index terms: Neoplasms, in infants and children • Tongue, neoplasm • Teratoma
Cleve Clin Q 50:34-37, Spring 1983

Tumors of the tongue, with the exception of squamous carcinoma, are rare. Granular cell myoblastoma is well known because of its unique histologic appearance. Familial ectopic thyroid and thyroglossal cysts, hemangiomas, and lymphangiomas¹ of the tongue occur in infants and children. Less well known and occurring even less frequently are dermoid cysts, hamartomas,² and gliomas.^{3,4} One case of rhabdomyosarcoma in a newborn has been reported.⁵ Teratomas of the tongue have been described in only 4 patients.⁵⁻⁸ We report the case of a fifth patient. Teratomas of the tongue, unlike ovarian, testicular, or mediastinal tumors, have shown no evidence of malignancy.

Case report

A 3260-g full-term, Caucasian male had marked enlargement of the anterior two thirds of the tongue (*Fig. 1*). The mass

measured 10 × 12 cm. The mucosal surface was intact; both the Apgar and recovery scores were 9 at one and five minutes, respectively. No respiratory distress was noted. There is a paternal history of twins.

To reduce tumor size and attempt to define histology, the mass was aspirated with a large-bore needle, and about 8 cc of seromucinous fluid was obtained. At 32 hours, the tentative preoperative diagnosis was teratoma and the mass was completely excised. As the mass was lobulated, noninvasive and contained in a pseudocapsule, preservation of the glossal muscle was possible. The postoperative course was uneventful and he was discharged at 13 days of age with his wound healing well, no feeding difficulties, and no masses palpable on the head or neck.

Carcinoembryonic antigen (CEA) was 3.2 ng/ml (normal, ≤2.5 mg/ml) at nine days of age. An alpha₁-fetoprotein study was also positive.

The patient was readmitted at seven weeks of age for repair of a right incarcerated inguinal hernia and a large umbilical hernia. On examination the tongue was slightly large, but otherwise normal. Repeated CEA and alpha₁-fetoprotein (AFP) were within normal limits. Urinary vanillylmandelic acid (VMA) and dopamine levels were elevated at 11 ng and 81.3 μg, respectively (normal, VMA 2-8 ng/24 hr, and dopamine 65-400 μg/24 hr), but reached normal levels at 10 months of age. The child is now two years old and doing well with no evidence of recurrent tumor (*Fig. 2*).

Pathologic examination

The excised tumor measured 5.7 × 5.5 × 4.1 cm. It was soft and irregularly lobulated. The cut surface revealed a greyish-white fleshy tumor with focal areas resembling mucoid degeneration, and small hemorrhages. Microscopic sections (*Figs. 3 and 4*) contained a mixture of tissue elements from all three germ layers. The most abundant element was immature neuroectodermal tissue. Small islands of cartilage were seen. Cysts of various sizes were lined with stratified squamous, transitional, and pseudostratified ciliated columnar epithelium. Spaces lined by goblet cells resembling colonic mucosa were also noted. No malignant tissue was seen.

¹ Department of General Surgery, The Cleveland Clinic Foundation. Submitted for publication in June 1982; revision accepted October 1982.

² Present address: 703 East Broad St., Winder, GA 30680.

³ Children's Medical Center and Wright State University School of Medicine, Dayton, Ohio.

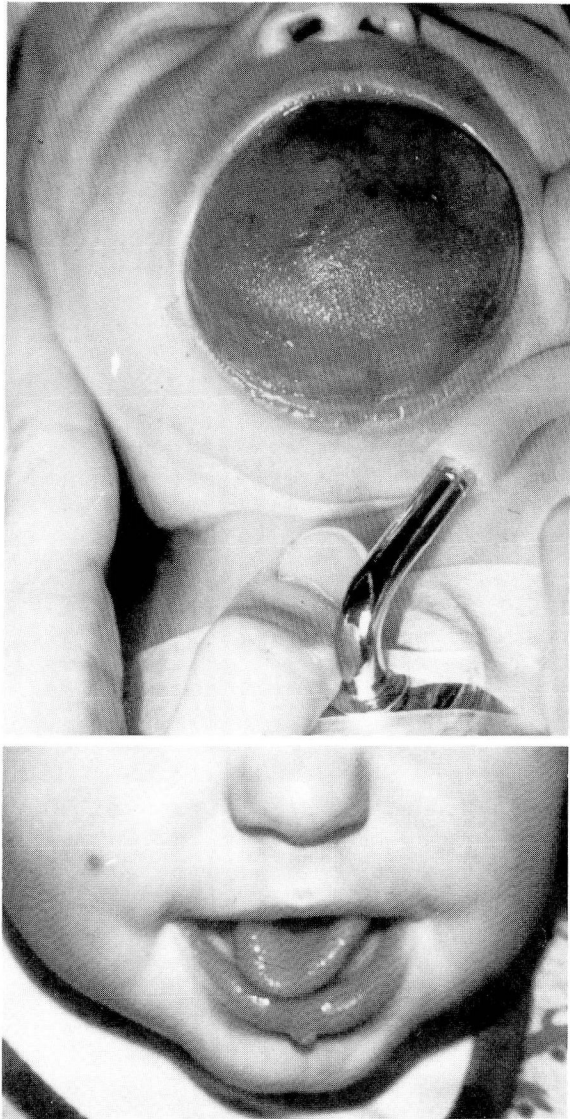


Figure 1. Teratoma of the tongue, patient at six hours of age.

Figure 2. Patient at two years of age; teratoma was removed shortly after birth.

Discussion

The congenital tumor of the tongue in the case reported here is of interest because of its rarity. Little is known about these tumors or their prognosis. This patient has survived two years with no recurrence, and it may be assumed that he is cured. Only 4 other cases of teratomas of the tongue in the newborn were found in the literature, 2 in females and 2 in males. None of the children exhibited respiratory distress even though the tumor appeared to block the oral cavity, probably because newborns are obligatory nose breathers. Feeding presents a major problem in these cases, and would have been

impossible in this patient. One of the four teratomas reported in the literature was attached to the right lateral portion of the tongue.⁹ It contained no neural elements. The teratoma reported by Grier and MacNerland⁷ was attached by a pedicle to the foramen cecum and contained mature neural elements. The teratoma described by Bras et al⁶ arose within the substance of the tongue and contained primitive neural and papillary tissue, as in the case reported here. The fourth teratoma was reported by Mahour et al,⁸ who reviewed 133 teratomas in children. These tumors ranged from 1 × 2 to 3 × 7 cm. The teratoma in the case reported here was 10 × 12 cm.

Malignancy in teratomas is an important consideration. The tumor in the case reported here did not have a true capsule, although a pseudocapsule was described by the surgeon. Sectioning disclosed no evidence of malignancy, although immature cells were present. Woolley et al¹⁰ believe that patients with teratomas containing immature but nonmalignant elements are at a 7% risk of death from tumor. The metastatic element is usually a germ cell tumor. In the case reported here the most immature element we found in the tumor was derived from neural tissue.

The presence of immature neural tissue in the case reported here and that of Bras et al⁶ requires further discussion of the malignant potential of these tumors. According to Norris's¹¹ classification of ovarian teratomas, the greater the immaturity and amount of neuroepithelium and the larger the size, the poorer the prognosis. In the series of 40 sacrococcygeal teratomas described by Gonzales-Crussi et al,¹² there was less correlation between immature elements and prognosis. A review of 405 cases of sacrococcygeal teratomas revealed that size in itself was not related to the incidence of malignancy.¹³ Mahour et al⁸ noted a higher malignancy rate in childhood teratomas detected beyond the newborn period. Teratomas of the tongue are obvious and unlikely to remain undiscovered. Because of limited clinical experience with these tumors, the relationship between immature elements and prognosis is unknown.

There has been no evidence of recurrence or metastasis at two years of age in the patient described here. The patient described by Grier and MacNerland⁷ was found to have a mass under the tongue five months after excision of the original tumor; this was considered a recurrence. Miller and Owens⁹ found no recurrence five years after excision. Histologically, neither of these teratomas contained

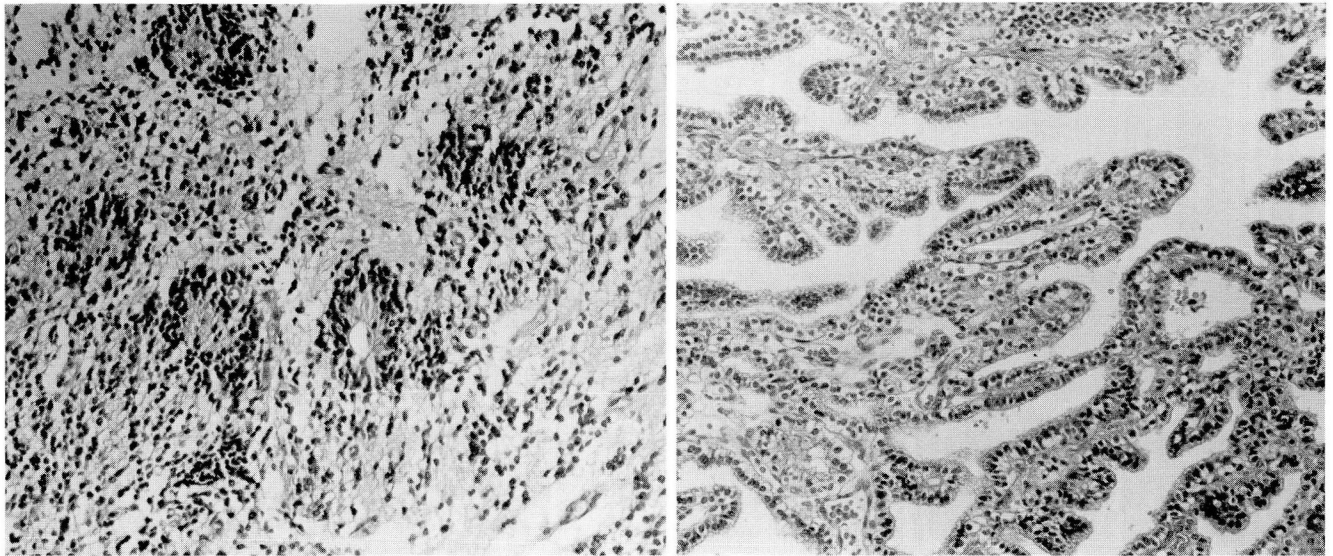


Figure 3. Immature neural tissue and several surface cysts lined by stratified squamous, transitional, and goblet cells, and pseudostratified ciliated columnar epithelium.

Figure 4. Papillary tissue (reminiscent of trophoblast) consisting of villi and trabeculae of loose fibrovascular tissue lined by a single layer of cuboidal cells.

immature neural tissue. New¹ reported the only other teratoma that histologically contained immature tissue, but there was no follow-up.

None of the previously reported patients with teratomas of the tongue were followed with serum markers. The patient reported here had minimal elevation of AFP at four days of age. Results of studies repeated at 10 months and two years of age were negative. The significance of the initial elevation is uncertain. CEA level was normal. Similarly, neural crest tumors elaborate catecholamines; the significance of the mild elevation of urinary VMA and dopamine at seven weeks of age is uncertain. Urinary epinephrines and norepinephrines were normal.

The origin of abnormal tissues in teratomas of the tongue is uncertain. Teratomas are considered to originate in a developing blastomere, with some of these cells becoming separated or displaced. Although a similar process could apply to teratomas of the tongue, other mechanisms are possible. For example, normal migrating mesenchymal cells to the tongue might be accompanied by embryonic neuroectodermal and other cells.⁶ The question as to specific cell types or totipotent cells being displaced is not answered satisfactorily. It has also been suggested that extragonadal midline teratomas, such as those of the tongue, represent incomplete conjoint twins.¹⁴ The father of the patient reported here is a twin and there are several other sets of twins in his family.

Multicentric teratomas are encountered rarely. The occurrence of a teratomatous mass under the tongue five months after initial removal in the patient described by Grier and MacNerland⁷ may represent a separate teratoma rather than a recurrence. The patient of Mahour et al⁸ had a separate teratoma of the submandibular gland. Abnormally located tissue in one area lends support to Warkanay's¹⁵ concept of teratomas arising from pluripotential primordia that escape normal organizing influences.

References

1. New GB. Congenital cysts of the tongue, the floor of the mouth, the pharynx and the larynx. *Arch Otolaryngol* 1947; **45**:145-158.
2. Patten BM. *Human Embryology*. 3rd ed. New York: McGraw-Hill Book Co, 1968, 170-171.
3. Rise EN. Dermoid cysts of the tongue and the floor of the mouth. *Arch Otolaryngol* 1964; **80**:12-15.
4. Hinshaw CT. Unusual lesions of the tongue—hamartoma. *J Kans Med Soc* 1963; **64**:154-157.
5. Wood GH, Williams JE. Rare tumor of the tongue of a newborn child. *Eye, Ear, Nose, Throat Monthly* 1952; **31**:83-85.
6. Bras G, Butts D, Hoyte DA. Gliomatous teratoma of the tongue; report of a case. *Cancer* 1969; **24**:1045-1050.
7. Grier EA, MacNerland RH. Benign teratoma of the tongue. *Illinois Med J* 1967; **132**:43-45.
8. Mahour GH, Landing BH, Woolley MM. Teratomas in children; clinicopathologic studies in 133 patients. *Z Kinderchir* 1978; **23**:365-380.
9. Miller AP, Owens JB Jr. Teratoma of the tongue. *Cancer* 1966; **19**:1583-1586.
10. Woolley MM, Ginsberg S, Di Censo S, Snyder WH, Mirabal VQ, Landing BH. Teratomas in infancy and childhood: a review of the clinical experience at the Children's Hospital of Los Angeles. *Z*

- Kinderchir 1967; 4:289-303.
11. Norris HJ, Zirkin HJ, Benson WL: Immature (malignant) teratoma of the ovary: a clinical and pathologic study of 58 cases. *Cancer* 1976; 37:2359-2372.
 12. Gonzales-Crussi F, Winkler RF, Markin DL. Sacrococcygeal teratoma in infants and children. *Arch Pathol Lab Med* 1978; 102:420-425.
 13. Altman RP, Randolph JG, Lilly JR. Sacrococcygeal teratoma; American Academy of Pediatrics Surgical Section Survey—1973. *J Pediatr Surg* 1974; 9:389-398.
 14. Ashley DJ. Origin of teratomas. *Cancer* 1973; 32:390-394.
 15. Warkanay J. Congenital malformations. Chicago: Year Book Pub, 1971; 1242-1243.