

THE TREATMENT OF CONGENITAL CLUB FEET

JAMES I. KENDRICK, M.D.

In this discussion no attempt will be made to present a review of all the aspects of the treatment of congenital club feet, but treatment of the early cases will be discussed and a method described for correction of this deformity.

Early diagnosis and prompt initiation of treatment are essential. Although the foot of an infant does not have the contour of that of an older child, very mild elements of deformity can easily be recognized by close examination and by putting the foot through ranges of motion, both actively and passively. Active movements of the foot of an infant can be observed very easily by gently stroking the inner and plantar aspects. The foot will be drawn away from the stimulus and the active range of eversion and dorsiflexion can be estimated. The foot of the normal infant is quite flexible and can be put through wide ranges of motion both actively and passively.

If treatment is begun early while the foot is flexible and composed mainly of cartilage, at least 95 per cent of the cases can be corrected by manipulations and molding alone, and if the foot is held in the corrected position for a sufficiently long period of time, cure can be effected. The logical time to start treatment is that period between birth and the time the child begins to walk. Weight bearing in the corrected position tends to maintain correction and promote normal growth. Weight bearing in the uncorrected position increases the deformity and stiffens the foot, making all later attempts at correction more difficult and the foot less serviceable after correction. Gentle manipulations and gradual molding of the deformed foot undoubtedly cause less reaction and result in a more flexible and better shaped foot than can be obtained by forceful manipulations under anesthesia.

Each club foot presents a separate problem. The degree of the elements of deformity are rarely the same even in each foot of the bilateral case. One may show only a mild degree of adduction of the forefoot (Fig. 1), another only inversion and shortening of the heel cord, while still another may show all three of these elements of deformity (Fig. 3A). These variations make me feel that treatment should be instituted only after the very closest examination and with the degree of each element of the deformity kept well in mind.

Kite¹ has discussed the advantages of the gradual correction of club feet and it is the wedging cast which he described that I have used and found to be very effective. He pointed out the necessity of correcting in succession each element of the deformity. I have found this to be most important. The adduction of the forefoot should be corrected first

and the relation between the navicular bone and the head of the astragalus restored before correcting the inversion and equinus. After the deformity in the forefoot has been corrected, the foot may be blocked into eversion and last into dorsiflexion. The normal relations of the bones should be restored and too great a degree of overcorrection should be avoided. Unless such care is taken, a very severe club foot may be enthusiastically blocked into a marked degree of overcorrection and, if held in that position for a sufficient length of time, may result in a badly pronated foot—a foot which would be better in appearance but almost as disabling as the original deformity.

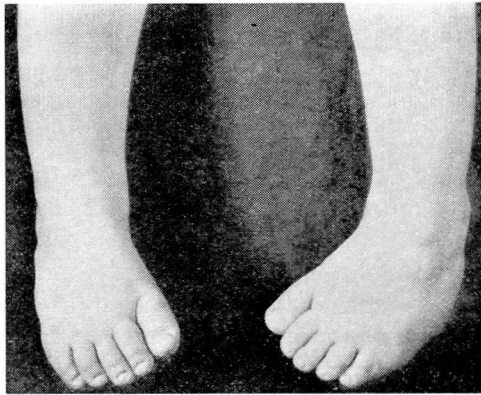


FIGURE 1 shows the case of an infant whose treatment was begun at the age of ten months. The prominent element of the deformity was adduction of the forefoot. The correction by molding in wedging plasters required ten weeks. Walking casts were then applied and the youngster learned to walk in these plasters.

There is undoubtedly a great tendency for deformity to recur but, as Kite² has pointed out, this tendency is more apt to be present in the cases in which attention has not been given to the accurate correction of each element of the deformity. When correction has been accurate and complete and when the corrected position has been maintained for a sufficiently long period of time, this tendency for recurrence of the deformity is minimized. To maintain the corrected position for a period of several months is no great problem in the infant but, in the case of the child that has learned to walk or has the desire to learn, it is difficult to keep him off his casts. For these older children, metal stirrups with a tread sole have been attached to the casts and they have been permitted to walk as soon as the corrected position has been obtained. To render these children ambulatory simplifies their care so materially that the casts can be left on for the desired length of time without the usual complaints from the parents. I feel that walking on the corrected foot, when it is held in place so accurately, helps to prevent the atrophy

THE TREATMENT OF CONGENITAL CLUB FEET

of the muscles which is seen frequently, to promote flexibility of the foot, and to bring about a morphological adaptation to the corrected position.

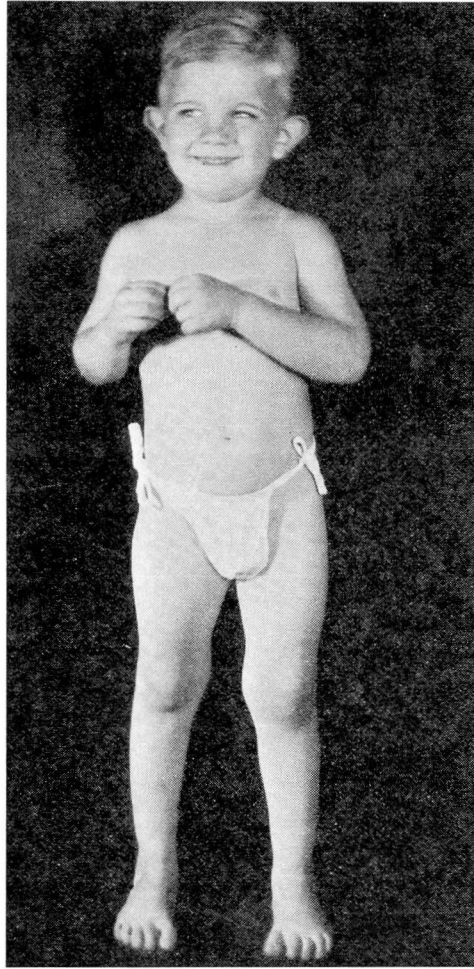


FIGURE 2 shows the child at the age of three years, twenty months after the removal of his plasters. The feet are quite flexible and actively over-correct in all the elements of the deformity.

In the very young infant, the mother is taught to carry out gentle manual manipulations. The sequence of these manipulations follows the same procedure as is used in correcting the foot in plaster. First the forefoot is manipulated to correct adduction, then the inversion is overcome and, last, the heel cord is stretched. The manual manipulations are directed toward keeping the foot flexible, as only in the mild cases are they effective in correcting the deformity. When the eighth

JAMES I. KENDRICK

to twelfth week has been reached, the foot is of sufficient size to begin correction in plaster. I feel that the foot should be of sufficient size that the wedges can be accurately removed from the casts.

In applying the wedging casts great care must be taken because, if the casts do not fit well, the wedging cannot be done as effectively and, unless

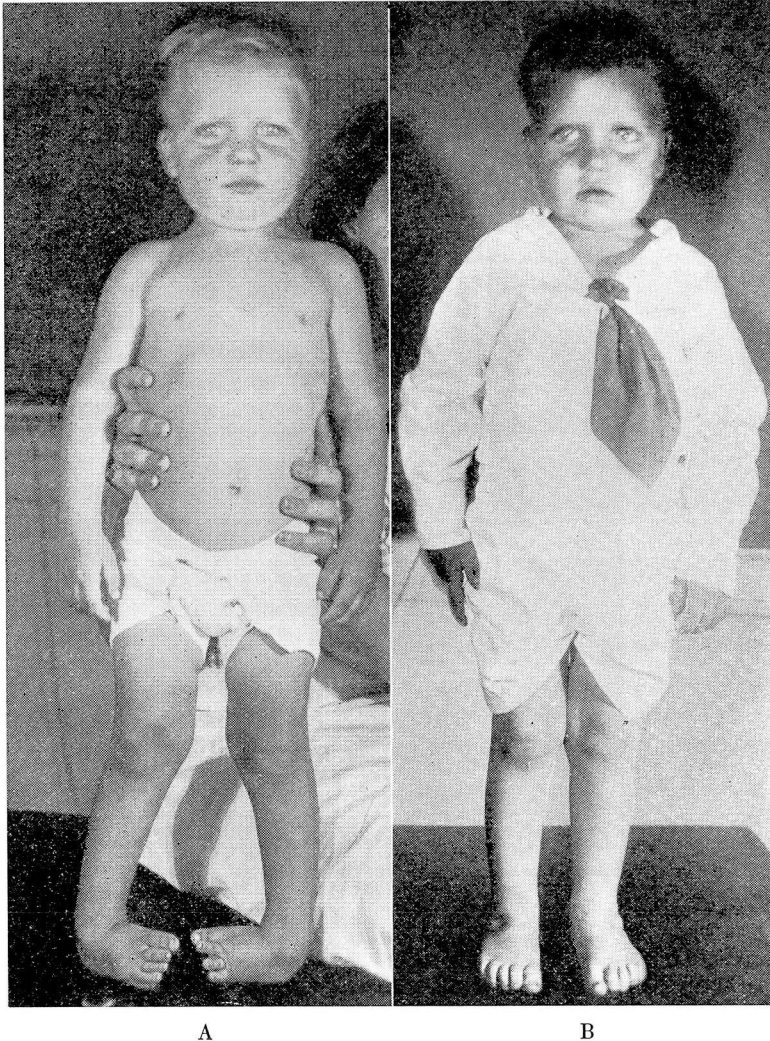


FIGURE 3: "A" shows an infant whose treatment was begun at the age of eleven months. Correction was obtained by molding in wedging plasters. Four months were required to obtain the correction. The walking plasters were applied and the child learned to walk in these plasters. The plasters were worn for a period of three months.

"B" shows the child at the age of three and one-half years, approximately twenty-two months after removal of the plasters. The feet are flexible and actively over-correct in all elements of the deformity.

THE TREATMENT OF CONGENITAL CLUB FEET

properly applied, irritation of the skin and areas of pressure may result. It is essential that a capable assistant hold the foot while the plaster is applied. The plaster is applied over a stockinette only, except over the dorsum of the foot and ankle where the wedge is to be removed. In these areas, half thickness felt is placed between the stockinette and plaster. The casts are wedged twice each week and are used as long as they are considered effective. During the period of correction the plasters are always carried above the knee, maintaining that joint in a position of ninety degrees flexion. This prevents the casts from slipping and also protects the ligaments of the knee joints against stretching as the correction progresses. I have found a small saw to be best in removing the wedges. If an assistant is to remove the wedge, the cast should be marked by the one directing the treatment so that the sequence of correcting the various elements of the deformity may be followed.

At the time of changing the casts, I do not believe that washing the feet with soap and water is advisable as this procedure makes the skin more susceptible to irritation. If the feet are powdered well at the time of changing the casts, plaster may be applied over a period of months without the least danger of irritation of the skin.

After correction has been completed and the corrected position has been maintained for a period of three to four months, the casts are removed and wedged shoes are fitted. It is my feeling that wedged shoes are all that are necessary to maintain correction if the foot has been completely corrected and held in correction for a sufficient length of time. If correction has not been complete, I have found braces ineffective in holding or further correcting the foot.

Figures 1, 2, 3A, and 3B show two typical cases and the end results.

In summarizing, I should like to emphasize the following points:

1. Congenital club feet should be treated early.
2. Gradual molding is the most effective method for correcting the deformity.
3. Maintenance of the corrected position for a prolonged period prevents recurrence of the deformity.
4. The walking plaster boot is of value in the treatment and makes the care of the child much less tedious during the period of maintaining the corrected position.

REFERENCES

1. Kite, J. H.: Nonoperative treatment of congenital club feet; A review of one hundred cases, *South. Med. J.*, 23:337-344, (April) 1930.
2. Kite, J. H.: The treatment of congenital club feet, *Surg., Gynec., & Obst.*, 61:190-200, (August) 1935.