

# Digital subtraction angiography in congenital heart disease in pediatric patients

Douglas S. Moodie, M.D.

*Department of Cardiology  
Department of Pediatrics and Adolescent  
Medicine*

Edward Buonocore, M.D.

*Department of Diagnostic Radiology*

John Yiannikas, M.D.

*Department of Cardiology*

Carl C. Gill, M.D.

*Department of Thoracic and Cardiovascular  
Surgery*

William A. Pavlicek, M.S.

*Division of Radiology*

Subtraction techniques to suppress bony and soft tissue structures in areas of angiographic interest are now used with increasing frequency. Advances in digital image processing combined with angiography have achieved high contrast sensitivity (as in computed tomography), enabling retrieval of information previously not available. Data may be converted to timed physiologic studies as well as anatomic images. We report the results of our initial experience with digital subtraction angiography (DSA) in 50 patients with congenital heart disease.

## Materials and methods

### *Imaging equipment and technique*

Data were obtained with a commercially available DSA unit (DR-960, Technicare Corporation, Solon, Ohio), which produces multiple sequential views of the cardiovascular system (*Fig. 1*). All images were made in the single-mask mode. A typical radiographic sequence utilized 80-100 kVp, 5-10 mAs/frame (2-10 msec at 1000 mA), and up to 6 frames/sec for 15 seconds. A single "best" mask was selected for immediate postprocessing. The image display was  $256 \times 256 \times 256$  shades of gray.

### *Flow analysis*

The region of interest curves were generated via keyboard-accessed flow analysis programs and the

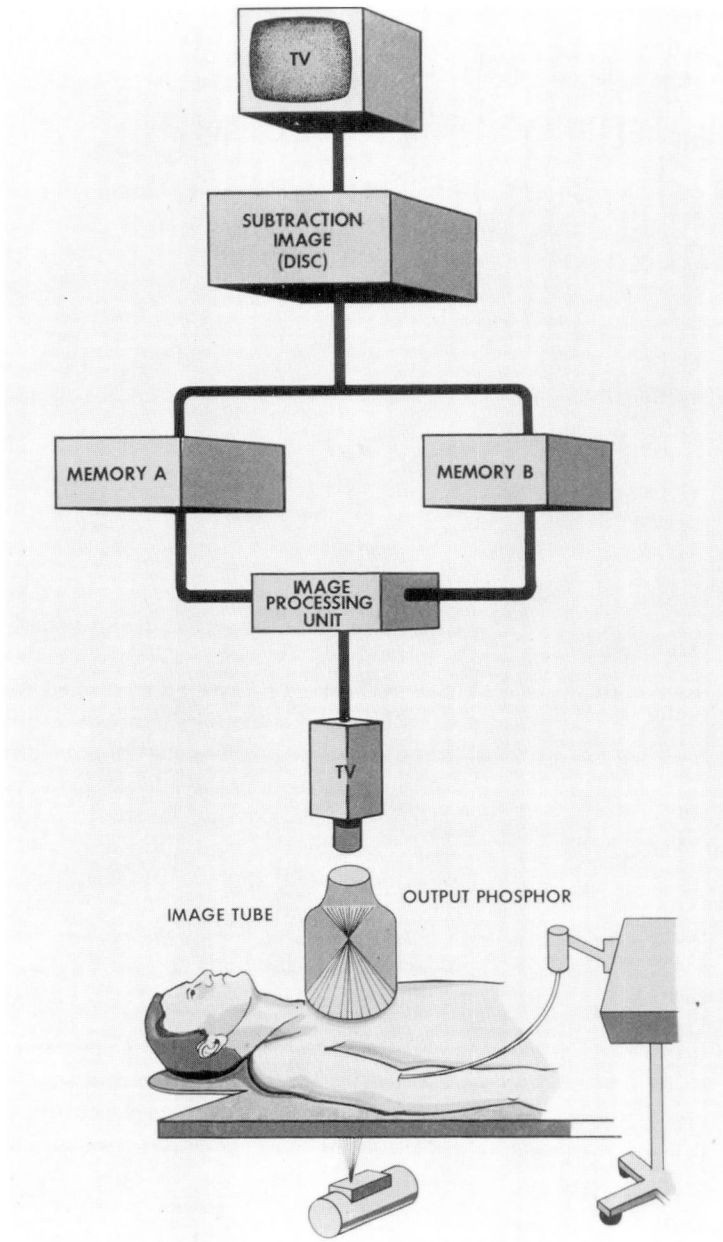


Fig. 1. Diagram of digital subtraction angiography system.

pixel values plotted against time after appropriate corrections for background. Pixel values represent change in x-ray attenuation by amount of iodine in the region of interest. These values reflect

the product of iodine concentration and vessel diameter provided appropriate corrections for radiation scatter and veiling glare are made. In our studies, however, these corrections were not ap-

plied and the data represent approximation of iodine concentration in the regions of interest suitable for comparison studies. The resultant curves were used to identify the course and quantity of contrast medium throughout the heart and great vessels, and to evaluate phasic changes of the cardiac chambers relating to systole and diastole.

### *Injection method*

In 48 of the 50 patients, contrast medium was injected into peripheral arm veins; in 2 others, intra-arterial injections were given to define coronary artery anatomy via aortic root injection. The younger patients were sedated with meperidine (Demerol), promethazine (Phenergan), and chlorpromazine (Thorazine). An 18-23 gauge angiocatheter was inserted into a peripheral vein of the arm or leg, or, when necessary, into the jugular vein in infants. The usual bolus dose of contrast material was 0.5-1 ml/kg, the average single injection ranging from 10 to 30 ml of Renografin-76. Dextrose flush of 10-25 ml followed each injection to clear the peripheral vein.

Several seconds after the injection, up to 50 frames were collected in the digital mode at the rate of 1-6 frames/sec. The first image (mask frame) was converted to digital form and stored in one of the computer's two memories (memory A), after which each subsequent frame was subtracted from the image in memory A and transferred to memory B, which displayed it on the television monitor (*Fig. 1*). Thus, the operator was given a sequence of real time subtraction images showing arrival and clearance of contrast material in the field of view. After the images are collected, the mask frame can be replaced by any subsequent image and a new sequence of subtracted images immediately becomes available. This allows selection of an optimum

mask, that is, one free of contrast material and usually made just before the arrival of contrast medium, thereby permitting optimum anatomic definition with maximum subtraction of interfering anatomy.

### *Data analysis*

The data were analyzed retrospectively, but blindly by the reviewers who interpreted the DSA studies, but they did not have prior knowledge of individual anatomic abnormalities during their analysis. All patients, except those considered normal, underwent cardiac catheterization. The normal patients had a clinical examination with chest radiographs, electrocardiograms, echocardiograms, and nuclear medicine studies.

### *Patient population*

Fifty patients with congenital heart disease were studied (28 males and 22 females) ranging in age from one month to 60 years (mean, 20 years). Seventeen were less than 15 years of age. The most common problems encountered were ventricular and atrial septal defect, tetralogy of Fallot, coarctation of the aorta, and innocent murmur (*Table*).

## **Results**

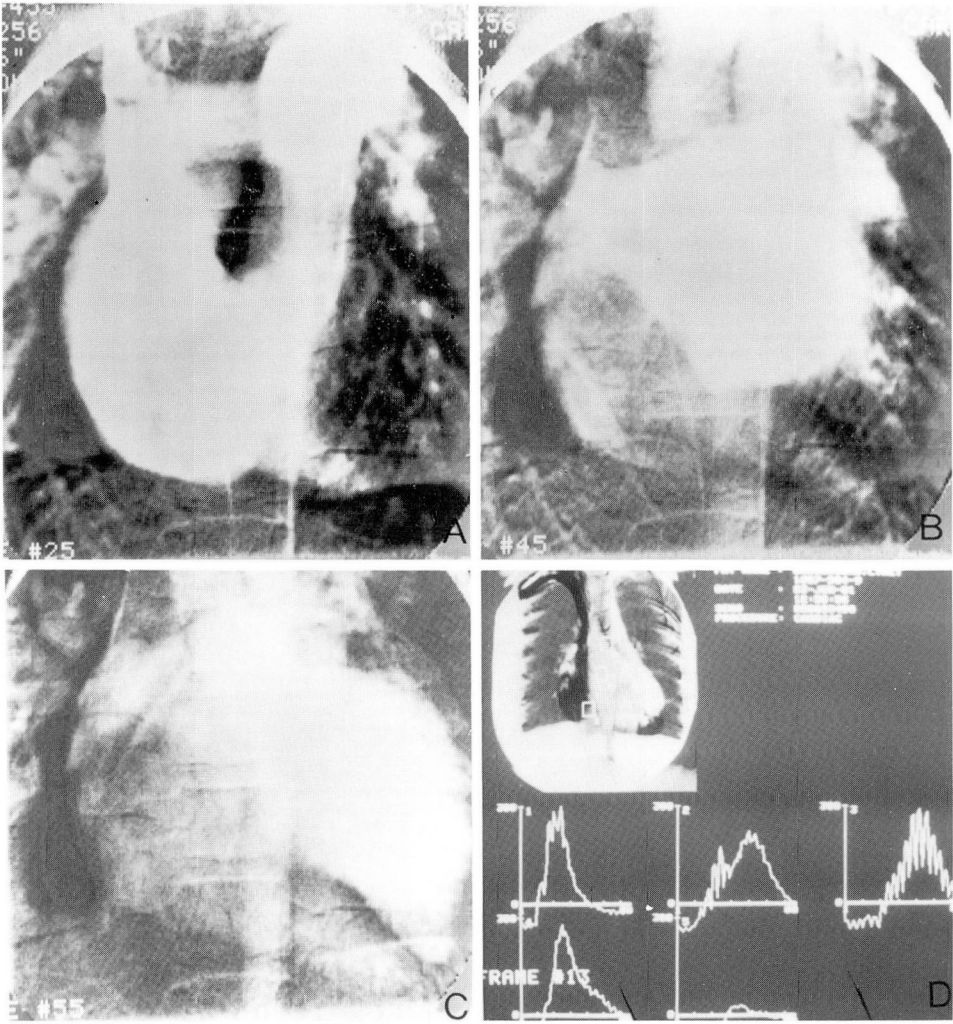
In patients with suspected congenital cardiac disorders, DSA results were retrospectively compared with clinical course, cardiac catheterization, and radionuclide and ultrasound studies. An attempt was made in each situation to evaluate the clinical usefulness of DSA in the light of clinical and laboratory results.

Ninety-three defects were evaluated in the 50 patients (*Table*). The DSA study of each defect was categorized as (1) technically unsatisfactory, (2) false-negative, (3) false-positive, or (4) correct diagnosis. All DSA studies were com-

Table. Retrospective analysis of clinical usefulness of DSA in 50 patients with congenital heart disease

Diagnosis/ anatomic site	Technically unsatisfactory	False- positive	False- negative	Clinical usefulness		
				Minimal	Moderate	Maximal
Normal	1 (Inadequate view)					7
Postoperative						14
Systemic vein						2
Right atrium and tricuspid valve						1
Interatrial septal defect				1	2 (Anomalous pulmonary veins missed)	6
Right ventricle						2
Tetralogy of Fallot						2
Postoperative tetralogy	1 (Wrong technique)				3	2
Pulmonary valve					1	3
Great vessels						3
Univentricle					1	1
Pulmonary artery					1	6
Pulmonary vein				2	1	2
Left atrium						2
Mitral valve*						1
Interventricular septal de- fect	1 (Motion)		1 (Catheterization also missed)		1	5
Aortic valve†			2			
Aorta			2		1	
Coronary					2	6
Extracardiac				1 (IV)		2 (IA)
	3	1	5	4	12	66

\* Mitral valve insufficiency.  
† Aortic valve insufficiency.



**Fig. 2A.** Normal digital subtraction angiogram in a 10-year-old patient with innocent murmur.

**B.** Levophase with filling of the left atrium.

**C.** Levophase demonstrating the left ventricle.

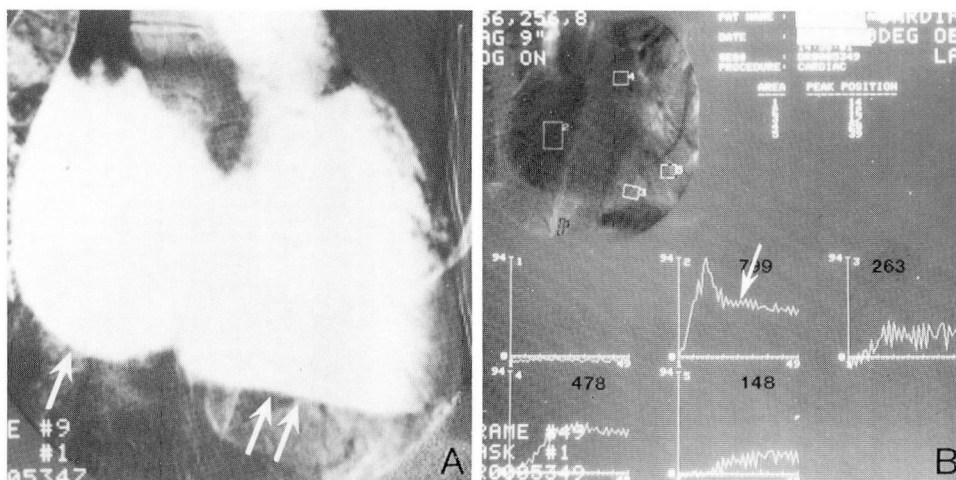
**D.** Normal digital subtraction angiogram with cursors placed over various regions of the heart. The lower portion of the figure displays intracardiac flow curves obtained from the regions outlined by the cursors in the upper portion of the diagram.

pared with standard conventional angiocardiograms. The correct diagnoses were then subdivided into three categories: (a) minimum help—DSA would not exclude further testing but gave insight into the clinical problem, (b) mod-

erate help—would have eliminated a significant amount of conventional cardiac catheterization, and (c) maximum help—would have totally excluded the need for cardiac catheterization.

Technically unsatisfactory proce-





**Fig. 3A.** Preoperative intravenous digital subtraction angiogram in a 13-year-old patient with an atrial septal defect. The single arrow points to the dilated right atrium and the double arrows to the dilated right ventricle.

**B.** Preoperative shunt curves obtained by placing cursors over the various regions of the heart. Curve 2 is a left-to-right shunt curve taken from the right atrium. The arrow points to recirculation pattern typically noted in left-to-right shunts. Because of continuous recirculation of blood into the right side of the heart and pulmonary artery, the curve does not come down to base line.

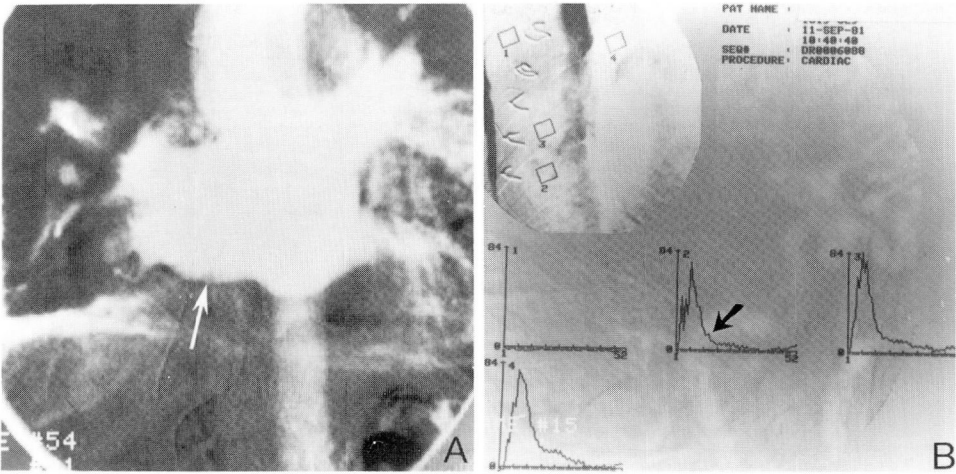
dures were noted in 3 of 93 defects. There were 5 false-negative studies and one false-positive. For the 84 defects correctly diagnosed, 4 studies were of minimum help, 12 were of moderate help in that they would have eliminated a substantial part of conventional testing, and 68 would have been of maximum help to the clinician in that they would have excluded invasive testing. Thus, 86% of the DSA examinations included important data which, in most cases, would have eliminated some of the routine cardiac catheterization studies.

Digital subtraction studies were particularly helpful in postoperative patients (*Table*). All 14 postoperative studies would have been of maximum help to the clinician as they would have excluded invasive testing. Eight of the 9 DSA studies of interatrial septal defects fell within the category of moderate and maximum usefulness (*Table*). DSA studies missed two small ventricular septal

defects, but these can be missed with oximetry in the catheterization laboratory and can be difficult to define angiographically. Just as in cardiac catheterization, it was difficult with DSA to determine the presence of partial anomalous venous return associated with an atrial septal defect versus an atrial septal defect alone.

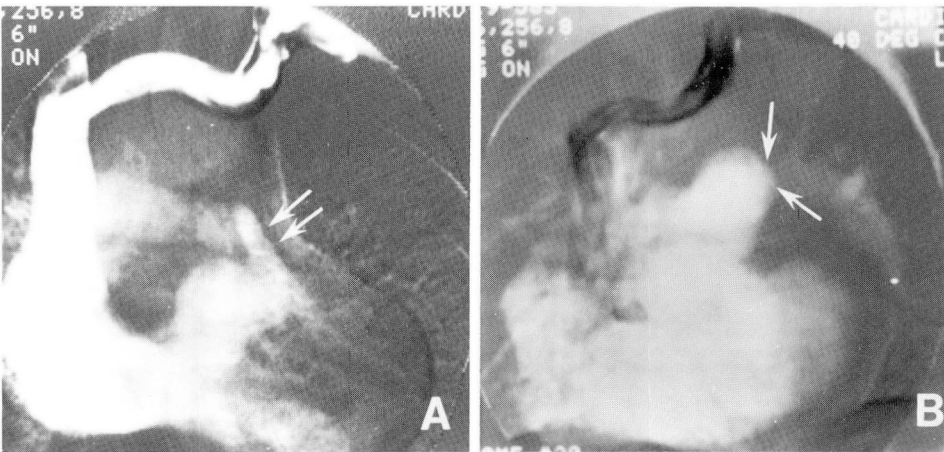
Digital subtraction angiography was particularly helpful in viewing the ascending aorta, aortic arch, and upper descending aorta, as well as the head and neck vessels. Eight of 8 studies of the aorta fell within the category of moderate and maximum usefulness (*Table*). We did not study a large number of patients with aortic or mitral insufficiency, but our preliminary work suggests that DSA will not be helpful in defining this entity although it will demonstrate enlargement of the left atrium and left ventricle.

The right ventricular outflow tract, pulmonary valve, main pulmonary ar-



**Fig. 4A.** Same patient as in *Figure 3*. Postoperative DSA, levophase, shows no evidence of residual left-to-right shunt at the atrial level. Arrow points to intact atrial septum.

**B.** Digital subtraction curves in the same patient obtained by placing cursors over various regions of the heart confirming no left-to-right shunt postoperatively. Note marked difference in the flow curves in comparison to the preoperative study (*Fig. 3B*). Black arrow points to normal flow curve.



**Fig. 5A.** Preoperative DSA in a 9-year-old patient with tetralogy of Fallot demonstrates severe right ventricular outflow tract hypoplasia and lack of flow to the left pulmonary artery. Double arrows point to the severe hypoplasia of the pulmonary valve, valve annulus and proximal main pulmonary artery.

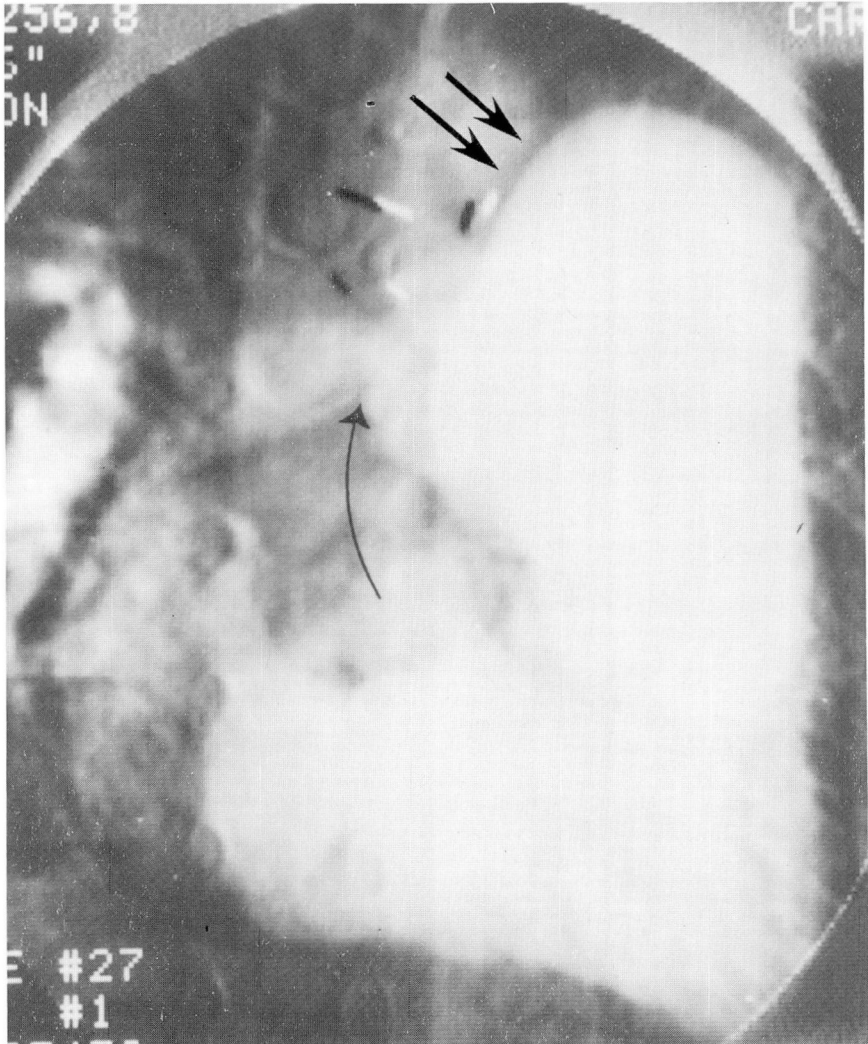
**B.** Postoperative DSA demonstrating reconstruction of the right ventricular outflow tract, with placement of a pericardial outflow patch to the distal left pulmonary artery. Arrows indicate distal anastomosis of the pericardial patch to the left pulmonary artery.

tery, and distal pulmonary arteries were readily visualized by DSA, and results in 7 of 9 studies of the pulmonary artery fell within the moderate to maximum clinical help category.

#### Examples

*Figure 2* is a normal DSA study via bolus injection of contrast medium through an antecubital vein in a 10-year-old patient with an innocent mur-





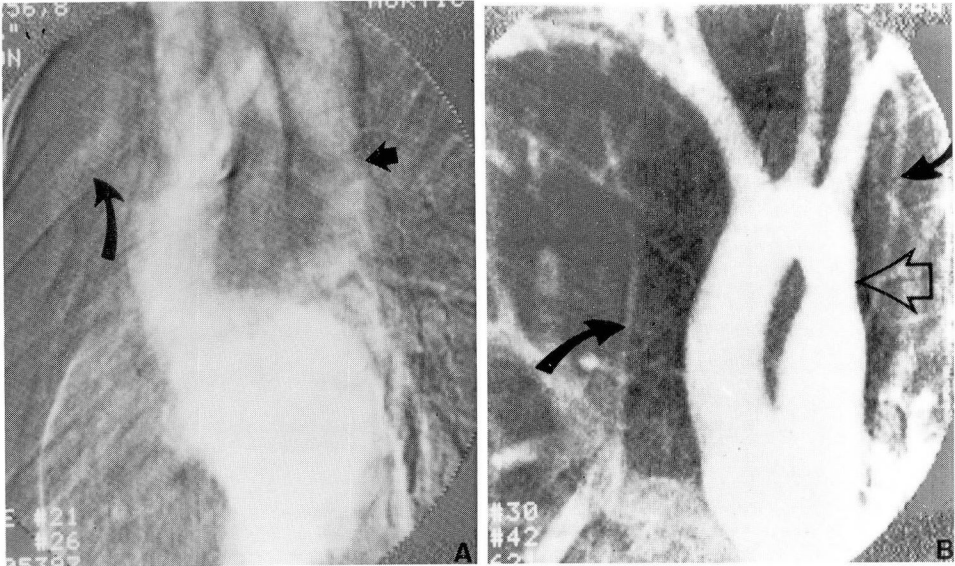
**Fig. 6.** Digital subtraction angiogram, AP view, in a 9-year-old patient two years after repair of tetralogy of Fallot. Double arrows point to a pericardial outflow patch aneurysm. Note mild stenosis of the right pulmonary artery (single arrow).

mur. Flow from the superior vena cava enters the right atrium (*Fig. 2A*). The right ventricle, right ventricular outflow tract, and pulmonary arteries are readily identified. On the levophase (*Fig. 2B*), normal pulmonary venous return fills the left atrium, and residual contrast material in the right ventricle is identified. With further filling (*Fig. 2C*), the left ventricle in systole and diastole

is visualized. *Figure 2D* demonstrates the use of cursors placed over various chambers of the heart, which generates intracardiac flow curves with the use of different regions of interest. Normal cardiac intracardiac flow curves are seen at the bottom of *Figure 2D*.

Eight of nine DSA studies of atrial septal defects fell within the category of moderate and maximum usefulness (*Ta-*





**Fig. 7A.** Preoperative DSA in a 9-year-old patient with coarctation of the aorta. Short, small arrow demonstrates coarctation in its usual position just distal to the left subclavian artery. Larger arrow indicates dilated internal mammary artery.

**B.** Digital subtraction angiogram in a 15-year-old patient two years after repair of coarctation of the aorta. The large arrow points to mild narrowing in the region of the previous coarctation. The two smaller arrows indicate normal-appearing internal mammary vessels.

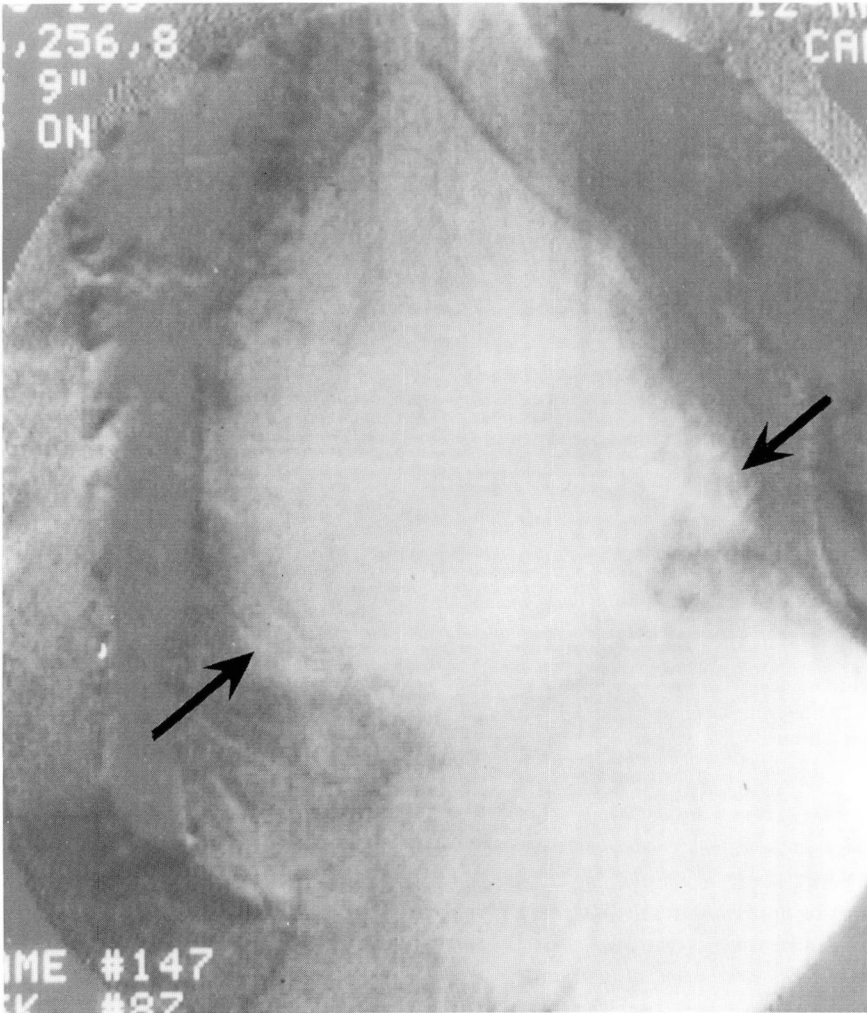
ble). The preoperative DSAs (*Fig. 3*) of a 13-year-old patient with an atrial septal defect show a dilated right atrium and right ventricular outflow tract (*Fig. 3A*). By placing cursors over the various regions of the heart, specifically the right atrium in this patient (*Fig. 3B*), flow curves were developed representing appearance and clearance of the contrast medium. The curve from the right atrium (*Fig. 3B, curve 2*) is a classic recirculation curve seen with left-to-right shunt. In the postoperative AP view (*Fig. 4A*), examination of the levophase indicates no evidence of recirculation into the right heart, and the pixel data flow curve is completely normal, indicating no residual left-to-right shunt (*Fig. 4B, curves 2 and 3*).

*Figure 5* is a DSA in a 9-year-old patient with tetralogy of Fallot. Severe narrowing of the pulmonary valve an-

nulus and outflow tract with lack of flow to the left pulmonary artery is visualized in the AP view (*Fig. 5A*). Surgery substantiated left pulmonary artery filling via bronchial collateral arteries and severe stenosis of the distal left pulmonary artery. The right ventricular outflow tract was reconstructed with reestablishment of continuity from the right ventricle to the distal left pulmonary artery with a pericardial patch. In the postoperative left anterior oblique view, the patch is seen to extend far out the distal left pulmonary artery (*Fig. 5B*).

*Figure 6* is an AP view in a 9-year-old patient two years after repair of tetralogy of Fallot. Aneurysmal dilatation of the pericardial outflow patch is associated with mild stenosis of the right pulmonary artery (arrow).

*Figure 7A* is the preoperative DSA in



**Fig. 8.** A 20-year-old man with Marfan's syndrome. Preoperative DSA reveals an ascending aortic aneurysm. Note marked dilatation in the region of the ascending aorta and aortic sinuses (arrows).

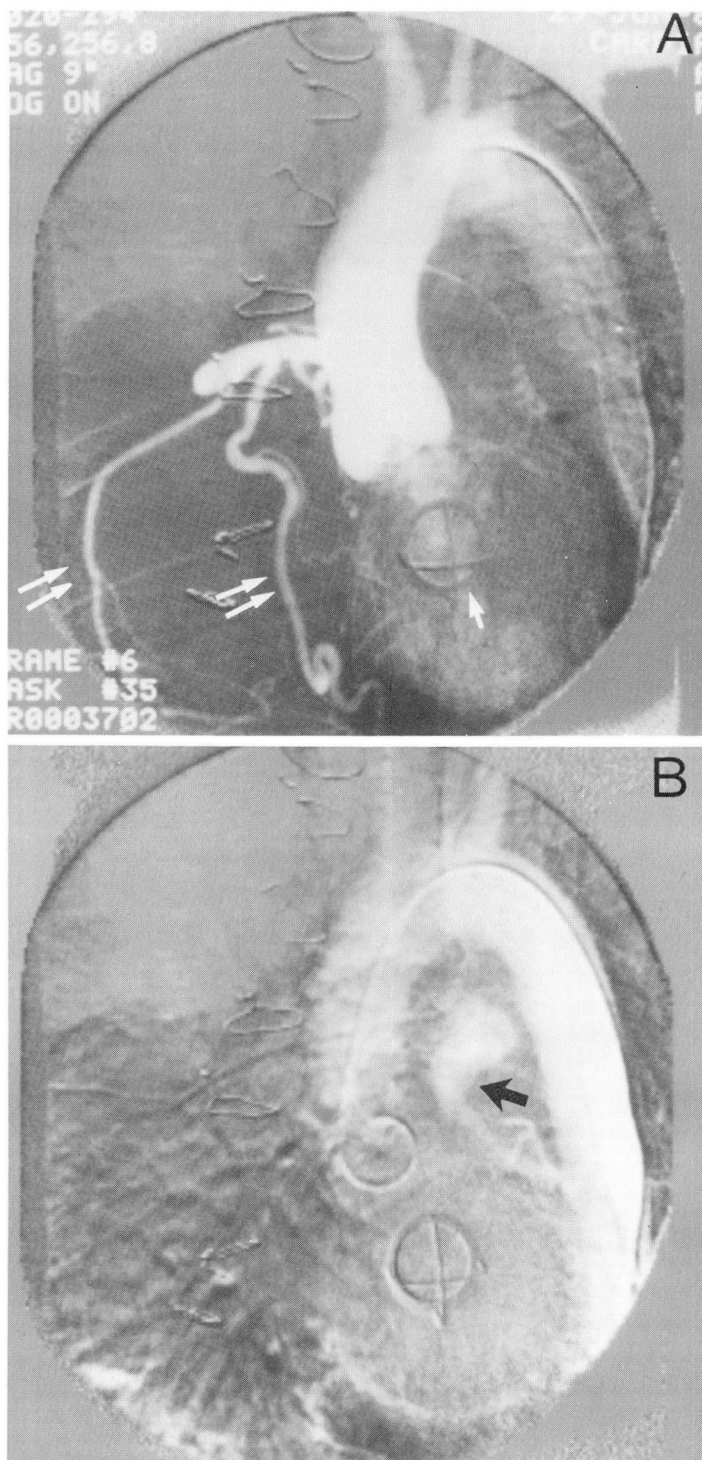
a 9-year-old patient with coarctation of the aorta. The coarctation is readily identified in the usual position just distal to a dilated left subclavian artery. Internal mammary arteries are markedly dilated (arrow). *Figure 7B* is the postoperative DSA in a 15-year-old patient two years after repair of coarctation of the aorta. A good surgical result is seen, with only mild narrowing in the region of the previous coarctation (*Fig.*

*7B, large arrow*). The internal mammary arteries are normal in size (*arrow*).

*Figure 8* is the preoperative DSA in a 19-year-old patient with Marfan's syndrome. A large ascending aortic aneurysm with a markedly dilated aortic root is visualized. Note the typical onion bulb appearance of the ascending aortic aneurysm.

*Figure 9* is a DSA in a 39-year-old woman 16 years after ligation of an





**Fig. 9A.** Arterial DSA in a 39-year-old woman 16 years after ligation of an anomalously draining left coronary artery to the pulmonary artery and mitral valve replacement. Note persistence of collaterals from the right coronary artery across the precordium (double arrows). Single arrow indicates prosthetic mitral valve.

**B.** Further filling of collateral vessels reveals persistence of a circumflex vessel (black arrow) draining to the pulmonary artery. This had not been ligated at the time of the initial repair.



anomalous left coronary artery draining to the pulmonary artery (Bland-Garland-White syndrome) with mitral valve replacement. Note the large, dominant right coronary artery system with collaterals across the precordium (*Fig. 9A*). *Figure 9B* demonstrates a persistent circumflex branch of the left coronary artery that continues to drain into the pulmonary artery. This had not been evident at surgery.

### Discussion

Several studies have demonstrated the potential use of digital processing of the output signal of image intensifier television systems for imaging the cardiovascular system.<sup>1-5</sup> Only a modest amount of intravenously administered contrast material is necessary for digital subtraction. Meaney et al<sup>6</sup> and Buonocore et al<sup>7</sup> have also validated the clinical usefulness of DSA in different areas of the human cardiovascular system.

The effectiveness of DSA is attributed to the efficient utilization of transmitted x-rays by low noise image intensifiers and television combinations. Electronic subtraction of unnecessary background results in enhanced contrast recognition at low contrast levels with standard doses of radiation.

The safety of DSA lends itself ideally to the pediatric patient with congenital heart disease. In no patient did complications warrant medical care. During external jugular vein injection in one patient, contrast medium extravasated into the soft tissues of the neck, but there were no untoward sequelae. All but 2 of our patients had the peripheral intravenous injection, usually through an antecubital vein.

Radiation exposure during DSA was usually only 2 to 3 R. In a comparison of conventional catheterization and DSA of the carotid arteries, the total dose received during DSA was found to

be significantly lower by a factor of 10.<sup>8</sup> This may be partially explained by the deletion of fluoroscopy time needed for catheter placement.

In summary, our preliminary evaluation of DSA in congenital heart disease suggests that it is safe and requires injections of standard amounts of contrast material (in most patients) via a *peripheral vein* and is consequently well suited to pediatric practice. Digital subtraction angiography provided information and diagnoses similar to that in conventional angiographic studies in 86% of the patients selected. Chamber size and configuration, anatomy of the great vessels, venous return, wall motion, and direction of flow were readily discerned. Digital subtraction angiography appears particularly useful in evaluating the right side of the heart, pulmonary arteries, aorta and aortic arch, as well as postoperative conditions in general. Our preliminary study suggests that DSA provides significant anatomic information that may modify the traditional diagnostic approaches to congenital heart disease.

### References

1. Mistretta CA, Kruger RA, Houk TL, et al: Computerized fluoroscopy techniques for non-invasive cardiovascular imaging. *Proc SPIE* 1978; **152**: 65-71.
2. Kruger RA, Mistretta CA, Lancaster J, et al: A digital video imaging processor for real time x-ray subtraction imaging. *Optic Engineer* 1978; **17**: 652-657.
3. Kruger RA, Mistretta CA, Houk TL, et al: Computerized fluoroscopy in real time for noninvasive visualization of the cardiovascular system. *Radiology* 1979; **130**: 49-57.
4. Ovitt TW, Nudelman SN, Fisher HD, Frost MM: Computer-assisted video subtraction for intravenous angiography. Presented at the Annual Meeting of the Radiological Society of North America. Chicago, November 1977.
5. Nudelman SN, Capp MP, Fisher HD, et al: Photoelectric imaging for diagnostic radiology and the digital computer. *Proc SPIE* 1979; **164**: 136-146.

6. Meaney TF, Weinstein MA, Buonocore E, et al: Digital subtraction angiography of the human cardiovascular system. *AJR* 1980; **135**: 1153-1160.
7. Buonocore E, Meaney TF, Borkowski GP, et al: Digital subtraction angiography of the abdominal aorta and renal arteries; comparison with conventional aortography. *Radiology* 1981; **139**: 281-286.
8. Pavlicek W, Weinstein M, Modic MT, et al: Patient doses during digital subtraction angiography (DSA) of the heart and neck: comparison with conventional angiography (abst). Annual Meeting of the RSNA, Nov. 1981.