

Serial assessment of doxorubicin cardiotoxicity in pediatric patients with quantitative radionuclide angiocardiology

Douglas S. Moodie, M.D.

Department of Cardiology

Paul G. Dymont, M.D.

*Section on Pediatric
Hematology and Oncology*

Carmen Napoli, R.T.

Sebastian A. Cook, M.D.

Department of Nuclear Medicine

Cardiac toxicity resulting from anthracycline therapy (doxorubicin and daunorubicin) is a major factor limiting the use of these drugs. Reliable, noninvasive methods to quantitate the severity of cardiac dysfunction resulting from the use of these agents are needed. Procedures have been proposed for assessing the cardiac status of patients receiving doxorubicin, including systolic time intervals,¹⁻⁵ electrocardiography,^{4, 6-9} and echocardiography.^{10, 11} None have proved to be of reliable predictive value.

The left ventricular ejection fraction has been shown to be a clinically useful index of cardiac performance that has both therapeutic and prognostic implications in patients with cardiopulmonary disease. This measurement can be determined noninvasively with the use of radionuclides. The use of radionuclide angiocardiology in adult patients who have received doxorubicin has been recently reported,¹² but its usefulness in pediatric patients has not been reported. We wish to report a case of doxorubicin-induced cardiotoxicity determined by radioisotope angiocardiology in a patient in whom the electrocardiogram and echocardiogram were not significantly abnormal. It was only by radioisotope determinations that evidence of cardiac impairment could be defined.

Case report

A 16-year-old boy had acute undifferentiated leukemia diagnosed in December 1978. At the time of the initial diagnosis the results of the cardiovascular examination were normal. The chest roentgenogram demonstrated a slightly enlarged heart (cardiothoracic ratio equal to .52) with a left ventricular contour. The electrocardiogram was normal except for low voltage T waves (*Fig. 1*). There was evidence on the M-mode echocardiogram of mild left ventricular hypertrophy with a small posterior pericardial effusion. The echocardiographic left ventricular pre-ejection time/left ventricular ejection time ratio (LVPEP/LVET) was normal at .21 and the echocardiographic left ventricular ejection fraction was 74%. Shortening as determined by echocardiography was greater than 30%.

A gated left ventricular ejection fraction was performed on our patient. An intravenous dose of approximately 20 mCi (200 μ Ci/kg) of 99m technetium human serum albumin was administered. After equilibrium, the camera was positioned at a 45-degree left anterior oblique angle to separate the right and left ventricular chambers. Electrodes, placed on the patient's chest were used to

synchronize the heart rate with the data acquisition in the computer memory. The data were accumulated on a portable Ohio-Nuclear gamma camera with an all-purpose, low-energy collimator. A 450-VIP Ohio Nuclear computer system was utilized in the acquisition and the analysis. The log edge program was utilized to find end-systole and end-diastole. The left ventricular ejection fraction determined by radionuclide angiocardiology was 77% (*Fig. 2*).

The patient received intensive chemotherapy induction regimens with vincristine, prednisone, daunorubicin, cyclophosphamide, and cytosine arabinoside without any response. Remission was finally achieved with a combination of doxorubicin and the investigational drug isofamide (NSC 109724). The cumulative doses of anthracyclines were doxorubicin, 216 mg (120 mg/m²) and daunorubicin, 200 mg (111 mg/m²). No mediastinal radiation was administered. Two weeks after receiving doxorubicin, the physical examination and chest roentgenogram remained unchanged. The electrocardiogram remained normal (*Fig. 3*) except for the low voltage T waves previously described. The left ventricular ejection fraction, determined by radioisotope, however, had decreased from 77% to 48% (*Fig. 4*). The

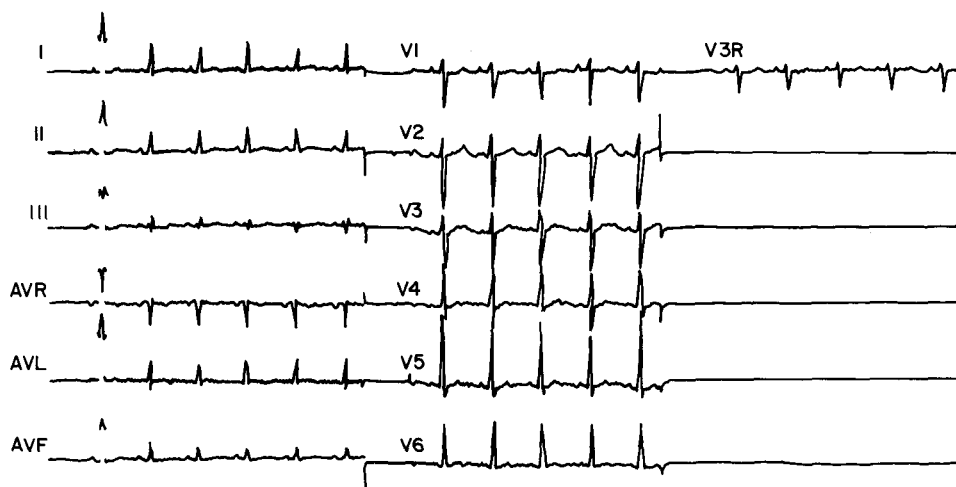


Fig. 1. Twelve-lead electrocardiogram from December 1978 demonstrating normal QRS voltages with flattening of the T waves in the lateral, precordial and inferior standard leads.

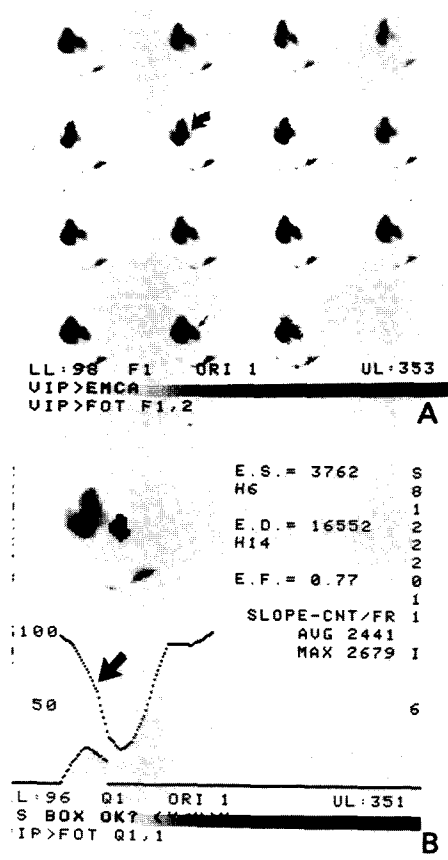


Fig. 2A. Preadriamycin gated left ventricular radionuclide study showing end-diastole (tiny straight black arrow) and end-systole (curved arrow). **2B.** Preadriamycin computer printout showing an ejection fraction of .77 and rapid left ventricular emptying (arrowhead).

M-mode echocardiogram also demonstrated a decreased left ventricular ejection fraction (59%) from the previous study, but the LVPEP/LVET was .20 and shortening remained greater than 30%.

Following this evaluation, the patient was monitored carefully in the intensive care unit during a fluid push for isofamide. No clinical evidence of congestive heart failure developed. Remission lasted only 2 months. During a subsequent relapse, he became septic, pneumonia developed, and he died. The autopsy was limited to biopsies of peripheral nerves.

Discussion

Our 16-year-old patient received a cumulative dose of 120 mg/m² of doxorubicin and 111 mg/m² of daunorubicin, dose ranges that in the past had been considered safe; yet he had a severe decrease in the radioisotope determined ejection fraction from 77% to 48%. This decrease would not have been detected if the scalar electrocardiogram or echocardiographic measurements had been used, since the electrocardiogram remained unchanged and the echocardiographically determined systolic time intervals and percent shortening remained normal. There was a decrease, however, in the echocardiographic left ventricular ejection fraction. Since the patient was to receive a large fluid push of normal saline while receiving isofamide therapy, it is conceivable that pulmonary edema and congestive heart failure could have developed if we had relied only on the electrocardiographic and echocardiographic findings.

Results of a recent study of adults has shown that systolic time intervals, electrocardiograms, chest roentgenograms, and physical examinations are not sensitive nor specific enough indices in detecting adriamycin-induced cardiomyopathy.¹² The authors demonstrated that all five adult patients in whom congestive heart failure developed had dramatic decreases in radioisotope determined left ventricular ejection fraction before clinical evidence of cardiac decompensation. In their study no patients in whom doxorubicin therapy was discontinued because of radionuclide evidence of moderate cardiotoxicity had clinical congestive heart failure.

In pediatric patients we have been similarly impressed by the lack of specificity and sensitivity of the M-mode echocardiogram and the complete un-

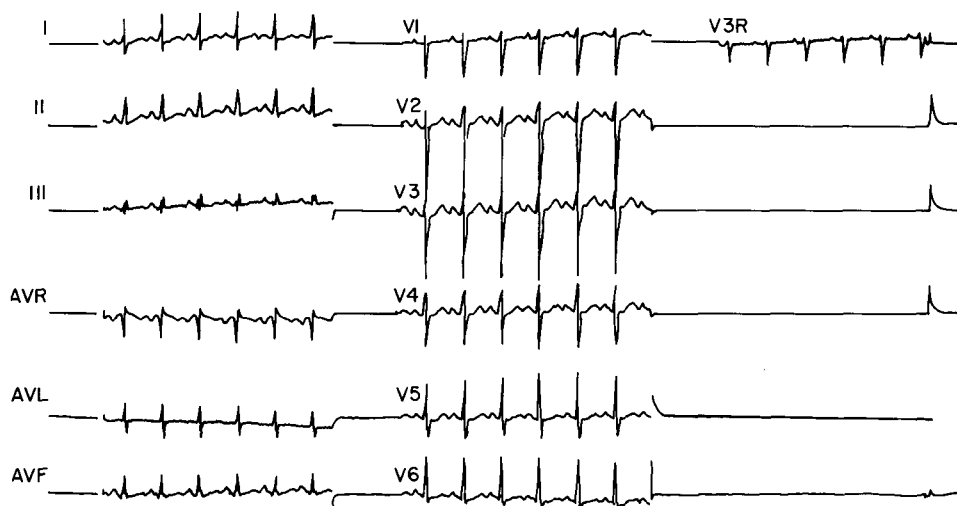


Fig. 3. Twelve-lead scalar electrocardiogram 4 months later demonstrating no significant difference from the electrocardiogram in December. There appears to be some S-T and T-wave abnormalities again with low voltage T waves in the lateral precordial leads as well as the standard inferior leads. The QRS voltages appear normal.

reliability of the scalar electrocardiogram for early signs of doxorubicin-induced cardiomyopathy.¹³ Hutchinson et al⁵ concluded that the value of echocardiographically determined LVPEP/LVET was limited in children, in that in their study prolongation of this ratio did not always precede congestive heart failure and prolongation was not followed by clinical failure in most patients. Our patient's echocardiographically determined systolic time intervals and percent shortening remained normal, as did the electrocardiogram, despite the significant decrease in left ventricular ejection fraction. The echocardiographic ejection fraction was decreased, but we do not believe that the M-mode echocardiogram is a reliable method for determining ejection fraction.¹³ To measure echocardiographic left ventricular ejection fraction, one determines the end-systolic and end-diastolic diameters and cubes them in an attempt to compensate for the fact that

the left ventricle is a sphere and the M-mode is a linear beam passing through this chamber. Small errors in echocardiographic measurements can result in large errors of overall ejection fraction since the single measurement is cubed. Isotope determinations do not depend on the configuration of the ventricle, but merely the counts (area) in the ventricle during diastole and systole.

It would appear that first pass radionuclide angiography is suited for serial prospective evaluations of ventricular performance in pediatric patients receiving cardiotoxic drugs. Sequential radionuclide angiography allows accurate, noninvasive identification of patients at risk for development of congestive heart failure, and it would appear to be a useful tool in predicting the appropriate time for drug withdrawal. Of equal importance is the ability of this procedure to select and monitor patients who might benefit safely from further high-dose chemotherapy.

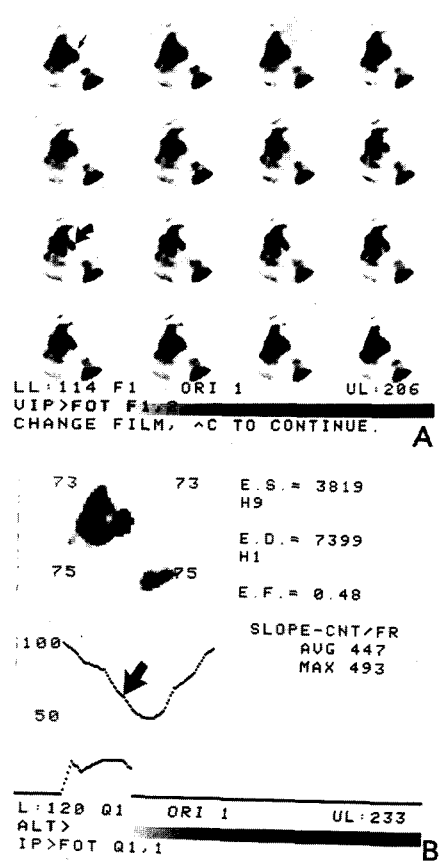


Fig. 4A. Postadriamycin gated left ventricular radionuclide study showing end-diastole (small black arrow) and end-systole (curved arrow). **4B.** Postadriamycin computer printout showing a decrease in the ejection fraction to .48 and a decrease in the rate of ventricular emptying.

References

1. Bristow MR, Mason JW, Billingham ME, et al: Doxorubicin cardiomyopathy: evaluation by phonocardiography, endomyocardial bi-

opsy, and cardiac catheterization. *Ann Intern Med* **88**: 168-175, 1978.

2. Burg JR, Moseley HS, Lindell TD, et al: Evaluation of cardiac function during adriamycin therapy. *J Surg Oncol* **6**: 519-529, 1974.

3. Rinehart JJ, Lewis RP, Balcerzak SP: Adriamycin cardiotoxicity in man. *Ann Intern Med* **81**: 475-478, 1974.

4. Ulmer HE: Assessment of cardiac toxicity to Adriamycin. *J Pediatr* **90**: 851, 1977.

5. Hutchinson RJ, Bailey C, Wood D, et al: Systolic time intervals in monitoring for anthracycline in pediatric patients. *Cancer Treat Rep* **62**: 907-910, 1978.

6. Minow RA, Benjamin RS, Gottlieb JA: Adriamycin (NSC-123127) cardiomyopathy: an overview with determination of risk factors. *Cancer Chemother Rep* **6**, (no. 2, pt. 3): 195-201, 1975.

7. Cortes EP, Lutman G, Wanka J, et al: Adriamycin (NSC-123127) cardiotoxicity: a clinical pathologic correlation. *Cancer Chemother Rep* **6** (no. 2, pt. 3): 215-225, 1975.

8. Lefrak EA, Pitha J, Rosenheim S, et al: A clinicopathologic analysis of adriamycin cardiotoxicity. *Cancer* **32**: 302-314, 1973.

9. Minow RA, Benjamin RS, Lee ET, et al: Adriamycin cardiomyopathy-risk factors. *Cancer* **39**: 1397-1402, 1977.

10. Bloom KR, Bini RM, Williams WM, et al: Echocardiography and Adriamycin cardiotoxicity. *Cancer* **41**: 1265-1269, 1978.

11. Ramos A, Myer RA, Korfhagen J, et al: Echocardiographic evaluation of Adriamycin cardiotoxicity in children. *Cancer Treat Rep* **60**: 1281-1284, 1976.

12. Alexander J, Dainiak N, Berger HJ, et al: Serial assessment of doxorubicin cardiotoxicity with quantitative radionuclide angiography. *N Engl J Med* **300**: 278-283, 1979.

13. Moodie DS, Van den Toren W, Seigel M, et al.: Left ventricular ejection fraction in children: comparison of M-mode and two dimensional echocardiography, radionuclide angiography, and contrast angiography. *J Nucl Med*. In press.