

Aortorenal vein graft stenosis causing recurrent hypertension

Repair with a temporary shunt

George E. Anton, M.D.

Department of General Surgery

Norman R. Hertzner, M.D.

Department of Vascular Surgery

Gordon N. Gephardt, M.D.

Department of Pathology

Although hypertension caused by fibrous or atherosclerotic lesions of the renal arteries may be successfully managed in selected patients by aorto-renal revascularization with the use of autogenous saphenous vein grafts, serial angiographic studies in some instances have demonstrated late degenerative changes such as graft dilatation, aneurysm formation, and segmental stenosis. Dilatation has been documented in 20% to 44% of saphenous vein grafts,^{1,2} but the functional significance of dilatation is presently unknown, since it has not been consistently associated with aneurysm formation or recurrent hypertension. In comparison, vein graft stenosis occurred in 17% of the series of 94 patients described by Dean et al¹ and required reoperation for renal salvage in 9% of the series of 91 cases reported by Stanley et al.²

Unless fibrous hyperplasia involves multiple renal arteries or extends into segmental branch vessels, intraoperative renal perfusion is rarely necessary during primary aortorenal revascularization since warm ischemia time during construction of the distal renal artery anastomosis usually does not exceed 15 to 20 minutes. Temporary renal perfusion during reoperative procedures may be considerably more important, however, since prolonged occlusion of the distal renal artery may be required.

We report a simple method of renal perfusion we have used during reconstruction of an aortorenal vein graft stenosis that had caused recurrent hypertension.

Case report

A 38-year-old woman first became hypertensive in September 1972 at the age of 31. The blood pressure at the time of diagnosis was 170/110 mm Hg and the sustained elevation of diastolic blood pressure at this level did not respond to medical management that included propranolol, guanethidine, and chlorothiazide. In March 1973, an abdominal aortogram demonstrated unilateral medial fibroplasia causing significant stenosis of the right renal artery. Selective renal vein renin values were 31.1 ng/ml on the right and 1.9 ng/ml on the left. The patient underwent antecaval aortorenal saphenous vein bypass grafting at another medical center and was normotensive without medication until 1977 when the blood pressure was again 170/110 mm Hg and a loud abdominal bruit was discovered. The elevated diastolic blood pressure could not be controlled with propranolol, and the patient was referred to the Cleveland Clinic Hospital in January 1979.

The results of physical examination were normal with the exception of a holosystolic abdominal bruit. The blood urea nitrogen (BUN) and serum creatinine values were normal. A transfemoral abdominal aortogram was obtained. The left renal artery was normal, and circulation to the upper pole of the right kidney was supplied by a small polar vessel. Severe focal stenosis and poststenotic dilatation were present within the aortorenal saphenous vein graft (*Fig. 1*). Both hypogastric arteries were normal. Before renal vein renin studies could be obtained, the patient experienced pain in the right flank associated with microscopic hematuria. Results of a cystoscopic examination were normal and, although an intravenous pyelogram demonstrated normal excretory function in the right kidney suggestive that the vein graft had not occluded, an

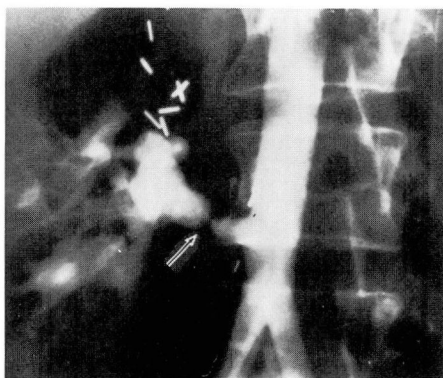

Fig. 1. Preoperative right transfemoral aortogram. Stenosis (arrow) and poststenotic dilatation are present with the aortorenal saphenous vein graft.

urgent operation for correction of vein graft stenosis was performed.

After exposure of the infrarenal abdominal aorta and the aortorenal vein graft, a segment of the right hypogastric artery was removed and preserved in a cold solution of heparinized blood. The stenotic aortorenal graft was isolated by the application of a vascular clamp partially occluding the aorta, and a silastic carotid endarterectomy shunt* was inserted between the stump of the right hypogastric artery and the distal right renal artery to perfuse the right kidney during the remainder of the arterial reconstruction (*Fig. 2*). The aortorenal saphenous vein graft was resected and replaced with the autologous hypogastric artery with interrupted 5-0 Dacron sutures (*Fig. 3*). Although 50 minutes were required for the entire reconstruction, total warm ischemia time for the right kidney was limited to 9 minutes with the use of the temporary indwelling vascular shunt. Postoperative BUN and creatinine values were normal, and an abdominal aortogram demonstrated a satisfactory anatomic result (*Fig. 4*). The patient had an uncomplicated recovery and has maintained consistent blood pressure levels in the range of 150/80

* Loop Endarterectomy Shunt, Heyer-Schulte Corporation, 600 Pine Avenue, Goleta, California.

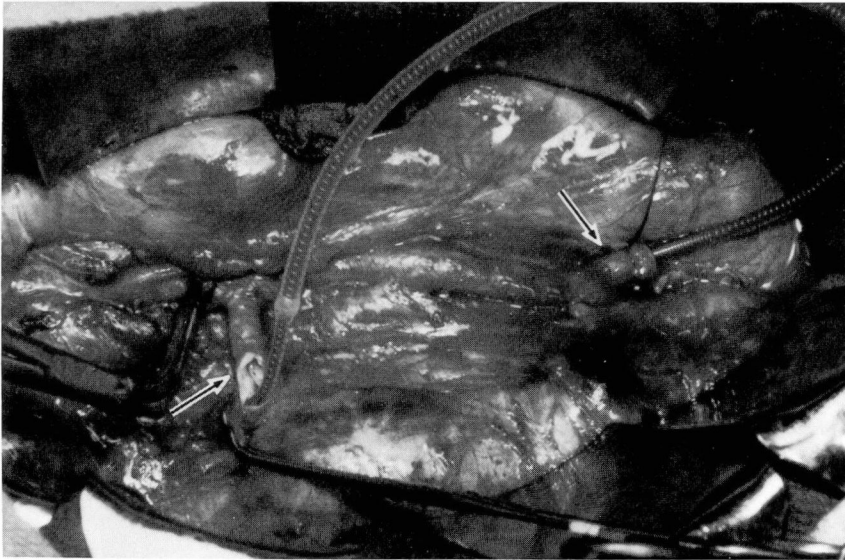

Fig. 2. Operative photograph. The aortorenal vein graft has been opened at the site of anastomosis (left arrow). A silastic carotid endarterectomy shunt has been inserted between the proximal stump of the right hypogastric artery (right arrow) and the distal renal artery.

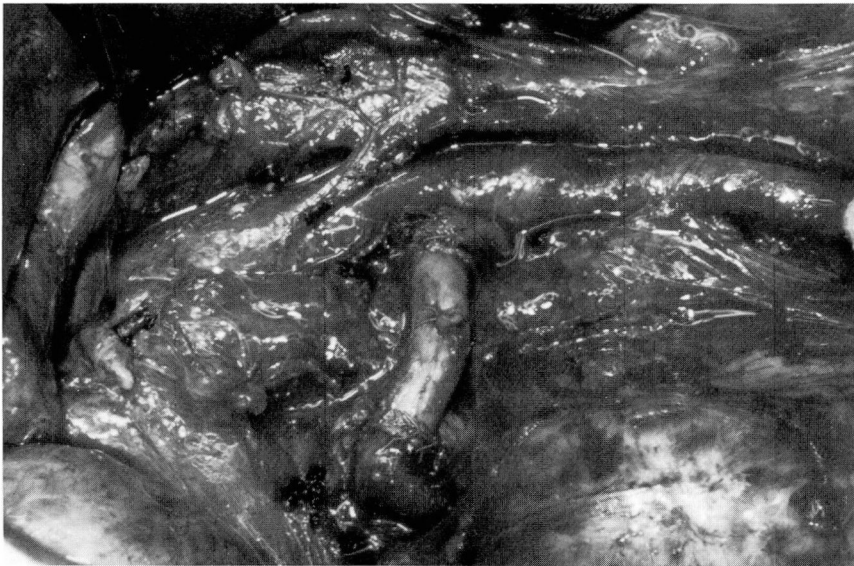

Fig. 3. Operative photograph. The completed reconstruction, with the autologous hypogastric artery used to replace the previous aortorenal saphenous vein graft.

mm Hg without medication during the 18 months since the reoperation.

Microscopic sections of the stenotic saphenous vein lesion demonstrated subintimal

fibrous proliferation and hypercellularity (*Fig. 5*). The smooth muscle layers contained no unusual hypertrophy, and there was no segmental adventitial fibrosis as has been

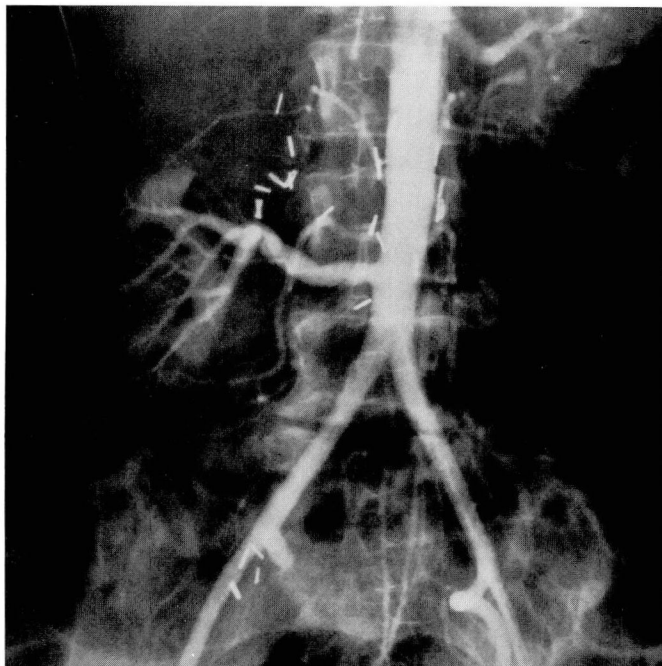


Fig. 4. Postoperative transfemoral aortogram. The angiographic appearance of the renal artery reconstruction is satisfactory.

described in aortorenal vein grafts placed in retrocaval positions. The angiographic and microscopic appearance of the stenotic lesion suggested that it may have been associated with focal subendothelial injury caused by application of a vascular clamp at the time of the initial renal revascularization in 1973.

Discussion

Although the late patency rates of autogenous saphenous vein grafts are acknowledged to be superior to those of prosthetic material for reconstruction of medium to small diameter arteries, practical considerations have restricted the use of serial angiographic studies for evaluation of late structural changes occurring in venous segments that have been implanted in the arterial circulation. When such studies have been done, the incidence of graft dilatation, aneurysm, fibrous stenosis, and venous atherosclerosis has been remarkably high

even in patients with successful functional results. Szilagyi et al³ described late angiographic abnormalities in 85 (33%) of 260 lower extremity saphenous vein arterial grafts of which 75 were stenotic lesions. Severe or progressive stenosis required reoperation for graft salvage in only 14 patients (5.4%).

Serial angiographic studies of aorto-renal venous bypass grafts indicate that the late dilatation is more prevalent than stenosis, possibly because renal blood flow is much higher than that measured in the femoropopliteal arterial segment. According to data reported by Dean et al¹ venous dilatation or aneurysm formation occurred in 25% and stenosis in 17% of patients after renal artery bypass, although graft thrombosis was the only indication for reoperation in this series. Stanley et al² reported graft dilatation or aneurysm formation in 52% and stenosis in 9% of 74 patients




Fig. 5. Photomicrograph of the stenotic saphenous vein lesion. Subintimal fibrous proliferation and hypercellularity are present (arrows), hematoxylin and eosin stain (×64).

who underwent late angiographic studies following aortorenal bypass. The development of stenotic lesions was attributed to trauma from vascular clamps as well as to periadventitial fibrosis, and six of the seven patients with stenotic grafts underwent reoperation for revascularization or nephrectomy.

Recurrent hypertension that is resistant to medical management following aortorenal bypass grafting is an unusual complication even among patients with graft stenosis documented by angiography.¹ Although recurrent hypertension provided an indication for angiographic evaluation and for reoperation in our patient, many patients in whom progressive graft stenosis develops do not experience symptoms until renal infar-

tion occurs at the time of graft occlusion. Since preservation of renal function is another criterion for reoperative correction of severe or progressive renal bypass graft stenosis, angiography should be considered in the presence of a new abdominal bruit or deterioration of renal function after previous renal artery revascularization, especially in patients who have solitary kidneys.

The results of aortorenal revascularization with autologous hypogastric artery grafts are similar to those reported for saphenous vein bypass in the management of renovascular hypertension, and autologous artery grafts may be more durable for use in children and young adults.^{4,5} Late stenosis of saphenous vein grafts is unusual and in most

cases probably is related to trauma during the initial surgical reconstruction rather than to intrinsic defects within the vein itself; however, autologous hypogastric artery appears to be a logical alternative for reoperative correction of stenotic vein graft lesions provided the artery is relatively free of atherosclerosis. Moreover, the proximal hypogastric artery stump provides a convenient source for intraoperative perfusion of the distal renal artery using a temporary indwelling vascular shunt. Although shunting probably is unnecessary when the contralateral kidney is normal or when warm ischemia time is restricted to less than 30 minutes, intraoperative renal perfusion may be a valuable adjunct during aortorenal reoperations when the contralateral kidney is absent or diseased or when warm ischemia time is either unpredictable or expected to be prolonged. We found that the use of a carotid endarterectomy shunt was technically uncomplicated in the patient described in this report, and we offer this method for consideration during difficult or reoperative renal artery procedures.

Summary

This report describes a patient who experienced recurrent hypertension

caused by stenosis of an aortorenal saphenous vein graft 6 years after renal revascularization. This unusual complication was successfully managed by replacing the stenotic vein segment with a graft of autologous hypogastric artery with normothermic intraoperative perfusion provided by a silastic vascular shunt. Although renal perfusion is usually unnecessary during routine arterial reconstruction, temporary shunting may be useful during reoperative or complicated renal artery procedures.

References

1. Dean RH, Wilson JP, Burko H, et al: Saphenous vein aortorenal bypass grafts: serial arteriographic study. *Ann Surg* **180**: 469-478, 1974.
2. Stanley JC, Ernst CB, Fry WJ: Fate of 100 aortorenal vein grafts: characteristics of late graft expansion, aneurysmal dilatation, and stenosis. *Surgery* **74**: 931-944, 1973.
3. Szilagyi DE, Elliott JP, Hageman JH, et al: Biologic fate of autogenous vein implants as arterial substitutes: clinical, angiographic, and histopathologic observations in femoropopliteal operations for atherosclerosis. *Ann Surg* **178**: 232-246, 1973.
4. Novick AC, Stewart BH, Straffon RA: Autogenous arterial grafts in the treatment of renal artery stenosis. *J Urol* **118**: 919-922, 1977.
5. Lye CR, String ST, Wylie EJ, et al: Aortorenal arterial autografts. Late observations. *Arch Surg* **110**: 1321-1326, 1975.