

Use of the Henley loop for postvagotomy diarrhea

Sharon Grundfest, M.D.
Caldwell B. Esselstyn, Jr.,
M.D.

Department of General Surgery

D. Roy Ferguson, M.D.

Department of Gastroenterology

Postvagotomy diarrhea is rarely a severe problem. Although two thirds of the patients undergoing truncal vagotomy may note a change in bowel habits, less than 1% will experience incapacitating symptoms.¹ Most patients with mild or moderate diarrhea after surgery improve with time or respond to low-carbohydrate, dry feedings. A small number of those with more severe diarrhea have nontropical sprue, lactase deficiency, decreased levels of IgA, or parasites. In the remainder, no cause is found.² Several investigators have found that the concentration of bile acids in the stool is increased in patients with severe postvagotomy diarrhea.³ Explanations have included increased dumping of bile salts into the intestine from a flabby, denervated gallbladder as proposed by Condon et al,⁴ although the syndrome has occurred in cholecystectomized patients. Additional explanations include malfunction of a denervated ileocecal valve as suggested by Scarpello and Sladen,⁵ malabsorption of bile salts with increased intestinal transit time, or an increased production of bile salts in the liver. Cholestyramine has been shown to be helpful in some cases.⁴⁻⁸ Some patients do not respond to any standard attempts to control diarrhea and require surgical intervention. We report two cases of disabling postvagotomy diarrhea corrected by the construction of a Henley isoperistaltic jejunal loop.

Case reports

Case 1. A 51-year-old man was first examined at the Cleveland Clinic in December 1974. He complained of having five to nine bowel movements per day with severe postprandial, midepigastic, and hypochondrial pain. He had lost 28.8 kg (64 pounds) over the preceding years. In 1964 he had had a vagotomy and pyloroplasty for an intractable duodenal ulcer. In 1970 recurrent symptoms of midepigastic pain caused him to seek surgical relief once again, and a subtotal gastrectomy with a gastrojejunostomy was performed. Upon recovery from this procedure he began to experience loose, watery stools about 30 minutes after eating, accompanied by symptoms of palpitations, diaphoresis, weakness, and occasional fainting. These symptoms were relieved by lying down.

The patient's physical examination was unremarkable except for a thin body habitus and surgical scars.

A complete blood count showed hemoglobin 13.9 g/dl, white blood cell count 6100 mm.³ Gastric acid analysis revealed no acid in the gastric remnant, even after stimulation with histalog. The fasting serum gastrin level was 80 pg/ml (normal, 78.7 ± 32 pg/ml). Esophagogastroduodenoscopy showed a normal esophagus, a small gastric pouch with moderately erythematous rugae, a normal stoma, and efferent and afferent limbs.

No ulcerations were seen. An upper gastrointestinal series showed greatly increased transit time; barium was seen in the rectum 15 minutes after administration of the test meal.

The patient was thought to have a combination of the dumping syndrome and post-vagotomy diarrhea. An operation was performed, converting the Billroth II to a Billroth I with the insertion of a 30-cm Henley isoperistaltic jejunal loop between the gastric remnant and the proximal duodenum (*Figure*). For 2 months postoperatively the patient did well, having only one formed stool per day. There was no pain, cramping, or fainting, and he had gained 6.8 kg (15 pounds). Unfortunately, the patient began to drink large amounts of alcohol. He was hospitalized 16 months postoperatively with alcoholic gastritis and died of an overdose of barbiturates 20 months after operation. According to his family physician there was no further difficulty with diarrhea before his death.

Case 2. A 53-year-old physician was referred to the Cleveland Clinic in 1978 for severe diarrhea. In 1972 he had had a coronary artery bypass operation for severe angina. In 1973 he complained of midepigastic and right upper quadrant pain. He was

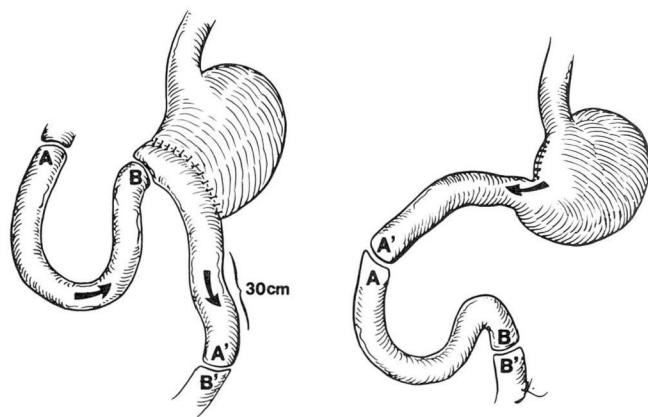


Figure. Conversion of Billroth II to Billroth I with insertion of 30-cm Henley isoperistaltic jejunal loop.

found to have chronic cholecystitis and a small duodenal ulcer. Cholecystectomy, truncal vagotomy, and pyloroplasty were performed. Postoperatively, severe, persistent diarrhea developed with 20 to 30 watery stools daily. There was no mucus or blood, and the patient lost 13.6 kg (30 pounds) over a 6-week period. He was treated with cholestyramine, which decreased the number of stools; however, severe midepigastric pain developed. The pain ceased when medication was discontinued, but the diarrhea recurred.

In September 1974 he came to the Cleveland Clinic complaining of severe epigastric and right upper quadrant pain shortly after eating. The pain was accompanied by a feeling of fullness and was relieved in 60 to 90 minutes with the onset of watery, foul-smelling diarrhea containing undigested food. The patient had 5 to 10 bowel movements per day. There was no flushing or hypertension. Physical examination and sigmoidoscopy were normal. Serum carotene was 50 $\mu\text{g}/\text{dl}$ (normal, 50 to 250 $\mu\text{g}/\text{dl}$), vitamin B₁₂ level was 370 pg/ml (normal, 160 to 900 pg/ml), and a folic acid level was 4.8 ng/ml (normal, 4 to 18 ng/ml). A 24-hour urine collection for 5 HIAA was negative. Stool was negative for neutral fat, and stool fatty acid concentrations were moderate. A serum gastrin level was 130 pg/ml (normal, 50 to 155 pg/ml). Upper gastrointestinal and small bowel films were normal. Despite periactin, belladonna, opium suppositories, and various oral antidiarrheal agents, his symptoms continued.

In October 1975 he went to another hospital where a subtotal gastrectomy and Roux-Y anastomosis were done for presumed alkaline reflux gastritis. The diarrhea was relieved for a time, but recurred 4 months later when he was given erythromycin for pneumonitis. He also noted that diarrhea increased after he ingested milk products.

In February 1978 the patient was admitted to the Cleveland Clinic Hospital complaining of diarrhea, with 6 to 10 watery stools a day. He had stopped working, not only because of the disabling diarrhea, but also because of his severe coronary disease,

which had been manifested by three myocardial infarctions and continuing Class IV angina. The abdomen was normal, and the stool was light brown and negative for occult blood.

An extensive work-up was performed. A complete blood count and serum electrolytes were normal. A chemical profile was normal except for a mild elevation of the alkaline phosphatase to 150 units (normal, 30 to 85 units). Results of stool examinations for blood, parasites, leukocytes, and pathogenic bacteria were negative. Serum carotene was again in the low normal range. Endoscopic examinations of the gastric remnant and the Roux-Y limb were normal. A biopsy specimen of the Roux-Y limb showed normal small bowel mucosa. The electrocardiogram gave evidence of a remote inferolateral infarction. A chest roentgenogram was normal. A barium enema examination of the colon and terminal ileum was interpreted as normal, but an upper gastrointestinal roentgenogram of the stomach and small intestine disclosed an area of narrowing in the upper jejunum with proximal dilation and irregularity of the mucosa suggestive of adenocarcinoma or lymphoma.

An exploratory celiotomy was performed. No tumor was found. Because of the patient's long-standing diarrhea, a 30-cm Henley isoperistaltic loop was constructed.

Postoperatively the patient did well and the diarrhea subsided. Three months after operation he had gained 4.9 kg (11 pounds) and was having one to three formed bowel movements a day. Apart from a continued intolerance of milk products, he was free of abdominal pain. Several months after operation he had gained 11.3 kg (25 pounds), had no diarrhea, and had formed stools. He travelled freely without fear of sudden diarrhea.

Discussion

The insertion of an isoperistaltic jejunal limb between the gastric remnant and the proximal duodenum devised by Henley was reported in 1951.⁹ In his series, Henley discussed two patients

with "post-gastrectomy syndrome." Both patients complained of postprandial vomiting, not diarrhea. Henley theorized that the conversion of a Billroth II to a modified Billroth I with the jejunal interposition would restore the flow of undigested food into the duodenum, allowing for a more physiologic release of duodenal secretions and bile with improved digestion and absorption. He performed barium studies and noted that the jejunal interposition increased gastric retention of the barium meal. The longer the jejunal segment, the slower was the gastric emptying time. The average emptying time in his series was 2 hours. Poth and Smith,¹⁰ referring to unpublished data, noted that action currents in bowel were greatly altered when the bowel was transected. One could conjecture that in this case when a hypertonic load was presented to the upper jejunum, a rapidly travelling propulsive wave was set in motion (Type III wave¹¹). When the jejunal segment was transected distally and anastomosed to the duodenum, the conduction of this peristaltic wave may have been interrupted, causing a delay in gastric emptying. It is also possible that these propulsive waves are hormonally mediated, or that these patients are abnormally sensitive to neurotransmitters following vagotomy (e.g., acetylcholine) or to kinins produced when the proximal jejunum is exposed to hypertonic solutions.

Woodward and Bushkin¹² have condemned the use of the Henley operation for the dumping syndrome. Certainly if the gastric pouch is very small, the isoperistaltic loop may not provide an adequate delay. Sawyers and Herrington¹³ and Poth¹⁴ have reported on the use of antiperistaltic segments in the treatment of dumping and postvagotomy diar-

rhea. Although they have had success with this method, there is a danger of necrosis of the reversed segment when the blood supply is twisted. The Henley operation has the potential disadvantages of alkaline reflux gastritis if the jejunal segment is not of adequate length.

Perhaps, as in infectious diseases, prevention is the best cure. It is now generally accepted that truncal selective vagotomies cause faster emptying of liquid (or liquid-solid mixtures) and slower emptying of solids from the stomach.¹⁵ The highly selective vagotomy (proximal gastric or parietal cell), preserving the innervation to the antrum and preserving the pylorus, avoids the sudden rush of high osmolarity foodstuffs into the small intestine. It is hoped that the rate of recurring peptic ulcers will be low enough to allow this operation to come into general use. For those few patients unfortunate enough to suffer from severe postvagotomy diarrhea, an adequate trial of medical management should always be given before surgery is contemplated.

References

1. Herrington JL Jr, Edwards WH, Carter JH, et al: Treatment of severe postvagotomy diarrhea by reversed jejunal segment. *Ann Surg* **168**: 522-539, 1968.
2. Storer EH: Postvagotomy diarrhea. *Surg Clin North Am* **56**: 1461-1468, 1976.
3. Allan JG, Gerskowitch VP, Russell RI: A study of the role of bile acids in the pathogenesis of postvagotomy diarrhoea. *Gut* **14**: 423-424, 1973.
4. Condon JR, Robinson V, Suleman MI, et al: The cause and treatment of postvagotomy diarrhoea. *Br J Surg* **62**: 309-312, 1975.
5. Duncombe VM, Bolin TD, Davis AG: Double blind trial of cholestyramine in postvagotomy diarrhea. *Gut* **18**: 531-535, 1977.
6. Scarpello JHB, Sladen GE: Post-vagotomy diarrhoea. *Lancet* **1**: 646-647, 1977.
7. Ayulo JA: Cholestyramine in postvagotomy

- syndrome; preliminary report. *Am J Gastroenterol* **57**: 207-225, 1972.
8. Allan JG, Russell RI: Cholestyramine in treatment of postvagotomy diarrhoea; double-blind controlled trial. *Br Med J* **1**: 674-676, 1977.
 9. Henley FA: Gastrectomy with replacement; a preliminary communication. *Br J Surg* **40**: 118-128, 1952.
 10. Poth EJ, Smith LB: Gastric pouches; their evaluation. *Am J Surg* **112**: 721-727, 1966.
 11. Sheehy TW, Floch MH: *Intestinal Motility in the Small Intestine*. Harper and Row, New York, 1967, p 147.
 12. Woodward ER, Bushkin FL: The early postprandial dumping syndrome; prevention and treatment, *in* *Postgastrectomy Syndromes*. Philadelphia, WB Saunders, 1976, pp 1-13.
 13. Sawyers JL, Herrington JL Jr: Antiperistaltic jejunal segments for control of the dumping syndrome and postvagotomy diarrhea. *Surgery* **69**: 263-267, 1971.
 14. Poth EJ: Use of gastrointestinal reversal in surgical procedures. *Am J Surg* **118**: 893-899, 1969.
 15. Bushkin FL, Woodward ER: Delayed gastric emptying, *in* *Postgastrectomy Syndromes*. Philadelphia, WB Saunders, 1976, pp 72-82.