

Obliteration of renal arteriovenous fistula by transcatheter clot embolization

Case report and experimental observations

Thomas F. Meaney, M.D.
Paul D. Chicatelli, M.D.*

Department of Radiology

The use of selective catheterization of the main arteries or their branches which supply various organs has become the accepted method for angiography. This technique provides high quality diagnostic information and may also be used for therapeutic purposes. Control of gastrointestinal hemorrhage by transcatheter infusion of vasopressors directly into bleeding arteries in the intestinal tract is a milestone in the application of selective catheterization.¹

The successful embolization of blood or particulate material at the time of surgery for obliteration of arteriovenous malformations of the brain² suggested that transcatheter embolization might obviate the necessity for a major surgical procedure. Successful control of bleeding by transcatheter embolization of clot into traumatically lacerated pelvic arteries has now been demonstrated.^{3, 4} Similar transcatheter clot embolization has been used to control gastric hemorrhage which did not respond to vasopressor infusion.⁵

This report illustrates the use of transcatheter embolization of clot to obliterate a renal arteriovenous fistula secondary to percutaneous renal biopsy. Included are the results of a simple *in vitro* experiment which was carried out in an attempt to explain the effectiveness of clot prepared by mixing the patient's blood with thrombin.

* Fellow, Department of Radiology.

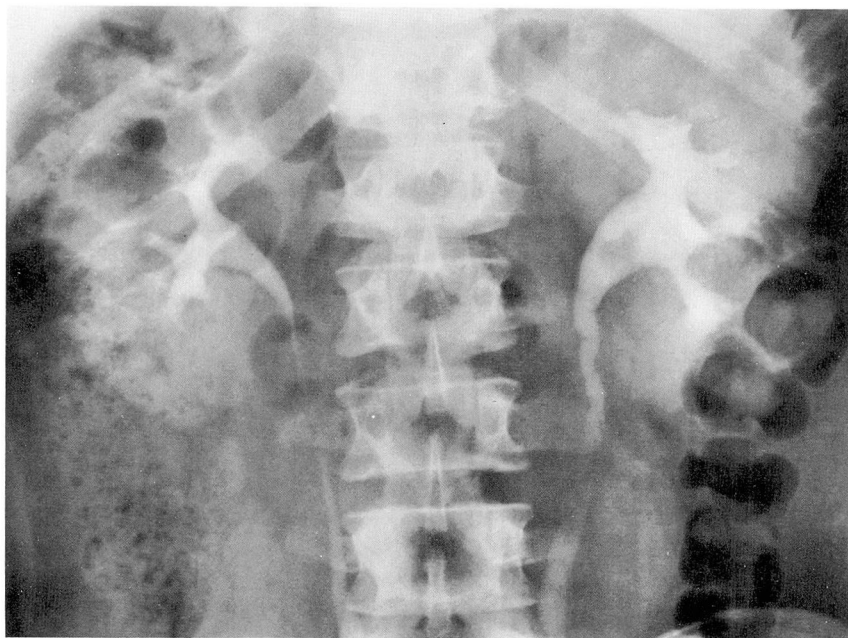


Fig. 1. Intravenous urogram made 6 days after biopsy shows filling defects in the left renal pelvis and dilatation of the left ureter, probably secondary to blood clots within them.

Case report

An 18-year-old white man was admitted to the Cleveland Clinic Hospital with gross hematuria. At routine physical examination 1 month prior to admission he was found to have albuminuria and microscopic hematuria. He had no facial swelling or any signs of edema, but had noted a rapid gain in weight over the past year. Because of obesity, a reducing diet was prescribed. One week later he noted arthralgia, malaise, fever, and sore throat. He was hospitalized elsewhere and treated with penicillin orally. Improvement was gradual, but albuminuria and microscopic hematuria persisted.

He was admitted to the Cleveland Clinic Hospital with probable glomerulonephritis. Following the initial studies, he underwent percutaneous renal biopsy. There were no immediate complications. Twelve hours following the biopsy left flank pain radiating to his groin and gross hematuria developed. An intravenous uro-

gram performed 6 days after the biopsy showed filling defects in the left renal pelvis and ureter which were considered to represent blood clots (*Fig. 1*).

Hematuria continued and 20 days after the biopsy a renal arteriogram was performed. A catheter was introduced using the percutaneous femoral technique and the left renal artery was catheterized. A selective left renal arteriogram revealed an arteriovenous fistula in the lower mid-portion of the left kidney (*Fig. 2*).

The branch of the left renal artery which supplied the fistula was then selectively catheterized and the location of the catheter in the feeding artery to the fistula was confirmed by an arteriogram (*Fig. 3*). An autologous blood clot was prepared by mixing 10 ml of the patient's blood with 1,000 units of thrombin.* This clot was fragmented into pieces measuring less than 0.1 cm in diameter and 0.3

* *Topical thrombin (bovine-origin) Parke, Davis & Company, Detroit, Michigan.*

cm in length; approximately six pieces were injected through the catheter. About 30 minutes later, another left renal ar-

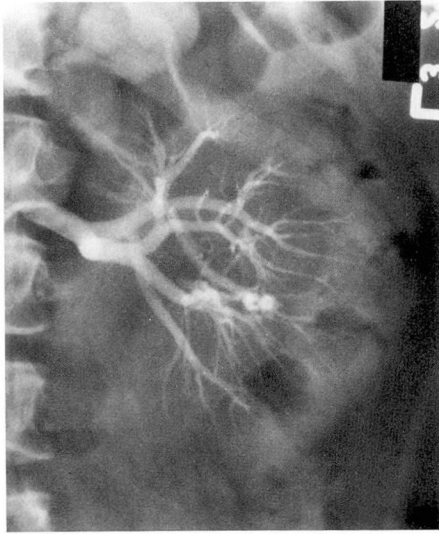


Fig. 2. Selective renal arteriogram showing the presence of aneurysmal-like formations within the fistula located in segmental branches of one of the lower interlobar arteries.

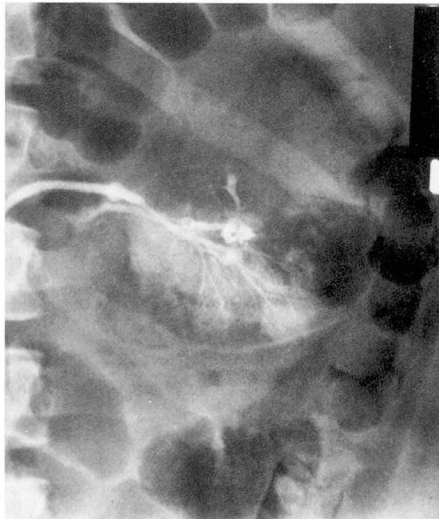


Fig. 3. Arteriogram after subselective catheterization of the segmental arterial branch supplying the arteriovenous fistula, prior to transcatheter injection of clot.

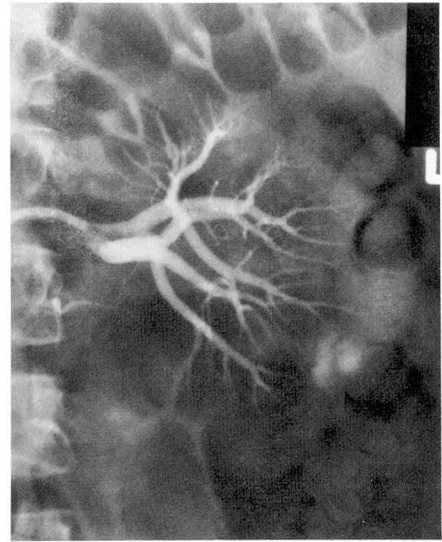


Fig. 4. Selective left renal arteriogram made 30 minutes after transcatheter injection of clot showing the fistula to be closed, and relatively normal appearance of the distal segmental branches of this renal lobe.

teriogram was performed which showed that the fistula had been occluded (*Fig. 4*).

The hematuria and flank pain promptly resolved, and 2 days following the arteriogram the patient was discharged without symptoms.

Experimental observations

The successful closure of the renal arteriovenous fistula by clot fragments of less than 0.1 cm in diameter, a size that could be injected through a polyethylene catheter with an internal diameter of 0.1 cm, and yet occlude the vessels of the fistula which appeared to be of larger size, raised questions as to the mechanism of thrombosis. The obvious mechanism would seem to relate to the growth of the clot fragments once arrested in the circulation. An alternative consideration was that the thrombin-prepared clot used in this patient may behave in the circulation in a manner dif-

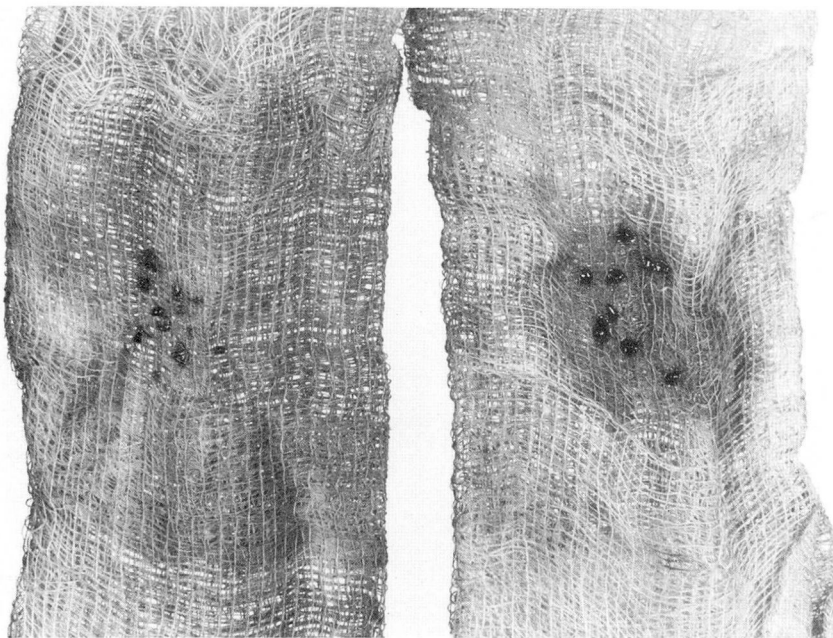


Fig. 5. (*left*) Appearance of clots, formed without added thrombin after washing with 10 ml of whole, fresh blood. (*right*) Increase in size of clots prepared with thrombin after washing with 10 ml of whole, fresh blood.

ferent from clot fragments prepared without the use of thrombin. The following simple *in vitro* experiment was performed. Two 10 ml samples of blood were removed from another patient. The first sample was allowed to clot without the addition of any extraneous material. The second 10 ml sample was mixed with 1,000 units of topical thrombin and allowed to clot. The two clots were fragmented into pieces measuring approximately 0.1 cm in diameter and placed upon separate pieces of gauze. Ten milliliters of fresh blood obtained from the same patient were flushed over each of the clot fragments through the gauze. The clots prepared without thrombin (*Fig. 5, left*) remained substantially unchanged in size. However, the clots prepared with thrombin increased ap-

proximately three times in size (*Fig. 5, right*).

Discussion

Renal arteriovenous fistulas following percutaneous biopsy are not uncommon but usually close spontaneously.⁶ Rarely, as in the case presented, persistent hematuria may be an important clinical problem following biopsy. The alternatives in treatment of persistent and prolonged hematuria include major operative procedures such as nephrectomy. Transcatheter clot embolization for obliteration of the fistula is an attractive alternative.

A similar instance of successful arterial embolization of postbiopsy renal arteriovenous fistula has been reported.⁷ In this case, an arteriogram

performed 5 days after embolization showed the fistula to be closed, and all peripheral branches in the renal arterial segment of the kidney in which clot had been introduced appeared patent. These authors speculated that clot fragments in normal circulation were promptly lysed, whereas those in the abnormal circulation of the fistula were not. A small area of infarction (2 by 3 cm) was subsequently identified.

A few possible sequelae of transcatheter clot embolization could be anticipated. The first would be renal infarction of the segment of the kidney in which the clot had been introduced. Although this is an undesirable consequence of embolization, it would not appear to be a significant consideration when one compares it to the loss of renal tissue which might occur with a surgical procedure such as segmental or total nephrectomy. In the case reported here there has been no opportunity to reexamine the patient to determine if an infarction has occurred.

A second possible complication of clot embolization in the kidney might be the development of hypertension secondary to compromise of the renal segmental circulation. In the case presented, this did not occur, nor was it a factor in the case reported by Bookstein and Goldstein.⁷

The simple *in vitro* experiment described in this report demonstrates that a thrombin-prepared clot is capable of augmented growth when washed with fresh blood as compared with a clot made without thrombin. It appears that in the *in vivo* circulation, the tiny clots which will pass through the limited internal diameter

of the catheter used for selective catheterization increase in size to occlude the larger vessels of the fistula. This increase in size might be expected to occur with autologous clot fragments prepared without thrombin. However, the *in vitro* study suggests that the thrombin-prepared clots have a greater potential for increasing in size because of the immediate availability of thrombin on the surface of the clot to interact with fibrinogen.

Summary

A case of a symptomatic renal arteriovenous fistula following percutaneous renal biopsy is reported. Transcatheter injection of thrombin-formed clot fragments following selective catheterization of the artery supplying the fistula resulted in successful closure of the fistula and alleviation of the patient's symptoms. This technique offers an alternative therapy to surgery.

A simple *in vitro* experiment suggests that clot fragments prepared with thrombin may increase in size in the *in vivo* circulation and thus aid in closing vessels larger than the clot fragments.

References

1. Baum S, Nusbaum M: The control of gastrointestinal hemorrhage by selective mesenteric arterial infusion of vasopressin. *Radiology* 98: 497-505, 1971.
2. Luessenhop AJ, Kachman R Jr, Shevlin W, et al: Clinical evaluation of artificial embolization in the management of large cerebral arteriovenous malformations. *J Neurosurg* 23: 400-417, 1965.
3. Margolies MN, Ring EJ, Waltman AC, et al: Arteriography in the management of hemorrhage from pelvic fractures. *N Engl J Med* 287: 317-321, 1972.
4. Ring EJ, Athanasoulis C, Waltman AC, et

- al: Arteriographic management of hemorrhage following pelvic fracture. *Radiology* **109**: 65-70, 1973.
5. Rösch J, Dotter CT, Brown MJ: Selective arterial embolization; a new method for control of acute gastrointestinal bleeding. *Radiology* **102**: 303-306, 1962.
6. Bennett AR, Wiener SN: Intrarenal arteriovenous fistula and aneurysm: a complication of percutaneous renal biopsy. *Am J Roentgenol Radium Ther Nucl Med* **95**: 372-382, 1965.
7. Bookstein JJ, Goldstein HM: Successful management of postbiopsy arteriovenous fistula with selective arterial embolization. *Radiology* **109**: 535-536, 1973.