

# Athletic injuries of the shoulder

Carl L. Nelson, M.D.

H. Royer Collins, M.D.

John W. Benton, M.D.\*

*Department of Orthopaedic Surgery*

The shoulder is the most mobile and least stable large joint in the body. With little built-in mechanical stability, the shoulder depends on muscles, tendons, and ligaments for stability.<sup>1</sup> These qualities predispose the shoulder to athletic injury.

Those who treat athletes are not surprised that 20% of athletes' injuries relate to the shoulder girdle. This incidence is greater in baseball, wrestling, and track and field events such as shot put, discus, and pole vault. Various injuries to athletes are reviewed.

## Soft tissue trauma

Contusion or bruising with hemorrhage is the injury most often associated with direct trauma. Localized pain, tenderness, and swelling are always present in the area of the blow. Initial treatment (within 24 to 36 hours) consists of an immobilization pressure bandage with or without foam rubber over the area, and an ice pack to prevent further local hemorrhage. After the first 48 hours heat may be applied. Range of motion and muscle strengthening exercises are soon added. The athlete may return to competition after pain and tenderness have subsided and muscle strength and shoulder motion are normal.

\* Fellow, Department of  
Orthopaedic Surgery.

Myositis ossificans or traumatic exostosis, known as "blocker shoulder," may develop as an unfortunate sequela of direct contusion. This diagnosis should be considered when pain and limitation of motion continue. A palpable mass is usually located in the area of the deltoid tuberosity of the humerus. Confirmation by roentgenography is essential. The area of the myositis or traumatic exostosis should be protected with padding to prevent further injury.<sup>2</sup> Surgery is contraindicated in early myositis ossificans.

### **Muscle strains**

The athlete who throws is often plagued by muscle strains around the shoulder girdle. These strains may follow sudden contraction of muscle fibers, but more commonly follow constant irritation. If pain is present on initiation of the pitch or throw, the strain usually has occurred anteriorly over the anterior deltoid, anterior trapezius, or pectoralis muscle. Most patients experience the pain during "follow through," and the tenderness is localized posteriorly in the area of the trapezius, the origin of the long head of the triceps, the posterior deltoid, or rhomboid muscles.<sup>3</sup> Treatment with ice followed by avoidance of irritation is adequate. Occasionally it is necessary to change the throwing technique, and in problem cases steroids should be injected into the affected region. Operative intervention is seldom indicated.

### **Rupture of the muscles or tendons**

Direct or indirect trauma may cause tears of the musculotendinous unit. These tears may occur at the tendon insertion, in the muscle belly, or at the musculotendinous junction, or they

may avulse the bony origin of the tendon (avulsion fracture).

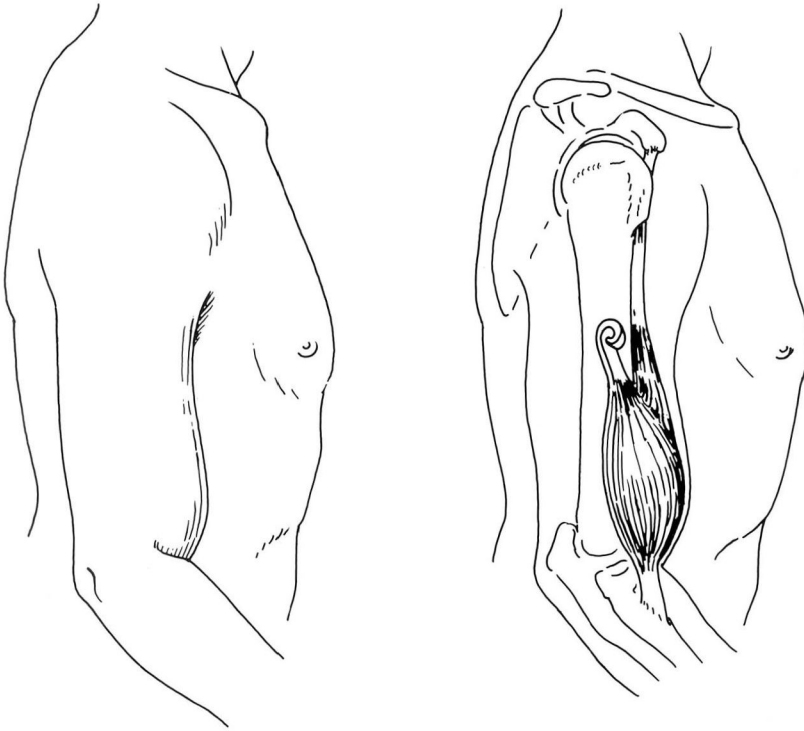
### **Tears of the long head tendon of the biceps**

In the athlete, tears at the long head tendon of the biceps muscle are associated with violent stresses, e.g., weight lifting and gymnastics. The individual experiences a sudden, severe snapping sensation in the upper arm and shoulder when he stresses the forearm. Immediate pain and obvious deformity of the upper arm develop (*Fig. 1*). Once hemorrhage has occurred with considerable ecchymosis and edema, the telltale bulge of the biceps may be obscured. In the younger patient surgical treatment is necessary. Deformity will persist in the older patient but muscular weakness is generally not disabling. Surgical treatment consists of reattaching the long head tendon to the humerus or to the coracoid process. End-to-end anastomosis is not advised if the rupture occurs at or proximal to the bicipital groove of the humerus.

Similar stress may rupture the biceps muscle belly causing a painful "double hump" deformity. Splinting of the elbow at 90 degrees with sling support for the duration of soft tissue healing, followed by gradual rehabilitation of muscular strength and shoulder motion, is usually adequate.

### **Tears of the rotator cuff**

The rotator cuff group of tendons may be torn when the athlete falls on the outstretched arm or on the tip of the elbow.<sup>4</sup> The patient has pain in the shoulder area and initially is unable to abduct his arm. This injury may be associated with anterior dislocation or subluxation of the humeral



**Fig. 1.** Demonstration of the external deformity and the internal rupture of the long head of the biceps.

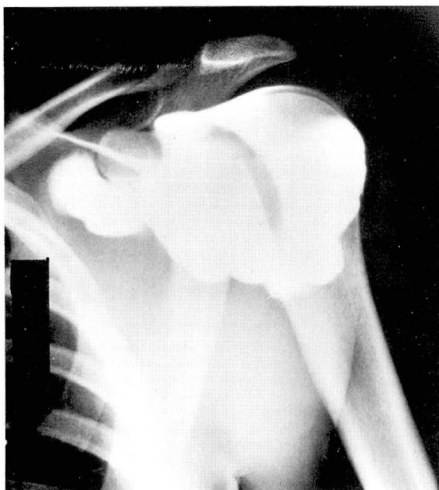head from the glenoid.<sup>5</sup> The musculo-tendinous units forming the rotator cuff hold the humerus against the scapula and stabilize the shoulder during abduction and forward flexion. If the rotator cuff tendons are torn significantly, movement of the arm away from the body is usually not possible. Because there are no stabilizing tendons to hold the humeral head against the glenoid, the humeral head slides up toward the acromion in a shrugging movement. However, athletes with well-developed deltoids may abduct with rotator cuff tears of significant magnitude. Key physical findings are weakness when the arm is abducted and a tendency to elevate the scapula as a substitute movement with abduction. Occasionally patients are unable

to hold the arm abducted because of pain caused by contusion. Differentiation from the rotator cuff tear may be difficult. When this occurs, a local anesthetic should be injected into the shoulder joint. If the patient is still unable to hold the arm abducted, a rotator cuff tear is likely.<sup>6</sup> In longstanding lesions, the only positive finding may be crepitus and pain when the rotator cuff is rubbed under the acromion process during abduction. Visible and palpable atrophy of the supraspinatus and infraspinatus may be present.<sup>7</sup>

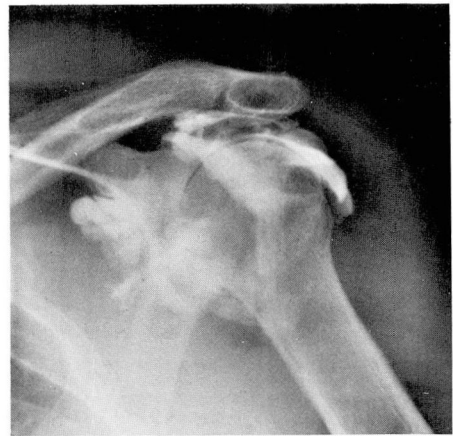When the diagnosis is in doubt, arthrography should be performed.<sup>1, 8, 9</sup> Contrast medium is injected into the shoulder either anteriorly or posteriorly. If there is no rotator cuff tear,

contrast medium is contained by the shoulder capsule (*Fig. 2*). Therefore, if there is communication between the shoulder capsule and the subacromial bursa, a tear of the rotator cuff exists<sup>8</sup> (*Fig. 3*). A clear subacromial area means there is no tear. Roentgenograms must be taken in proper rotation so that the beam parallels the undersurface of the acromion. If contrast medium crosses the humerus on the axillary view, a rotator cuff tear is likely. Occasionally communication will not be complete. A noticeable ulcer-type crater in the cuff area may indicate healing or an incomplete tear of the rotator cuff.

During surgical repair of significant rotator cuff tears the acromion should not be removed. When possible a small muscle splitting incision should be made. The coracoacromial ligament is excised for better exposure. If necessary, the acromioclavicular joint should be resected to achieve better exposure. After snug closure of the defect, the shoulder is immobilized for 6 weeks. A complete range of motion



**Fig. 2.** Normal arthrogram.



**Fig. 3.** Rotator cuff with opaque material in the subacromial bursa.

and normal muscular strength must be attained before the athlete is allowed to participate. We believe that rotator cuff tears should be repaired primarily if they are severe and should be operated on secondarily if the shoulder fails to respond to conservative management.

### Acromioclavicular separation

Another common shoulder injury is acromioclavicular separation, the so-called shoulder separation or football shoulder. Injury to the acromioclavicular joint occurs when a player is blocking or tackling and falls to the ground on the tip of the shoulder.<sup>4</sup> He experiences sudden pain in the region of the acromioclavicular joint and has difficulty moving the arm. The mechanical stability of the acromioclavicular joint must be determined.<sup>9</sup> The acromioclavicular ligaments provide minor support, but the primary stabilizers of the clavicle are the coracoclavicular ligaments (*Fig. 4*). In a first degree sprain, there is a partial tear of the acromioclavicular capsule



and ligaments, without a tear of the coracoclavicular ligament; there is also a loss of stability. The second degree sprain is a more serious injury with complete tearing of the acromioclavicular ligament. The coracoclavicular ligament remains intact and the joint is stable.

A third degree sprain is usually obvious on examination. Tears of both the acromioclavicular and coracoclavicular ligaments may occur<sup>10</sup> (Fig. 5). Roentgenograms of both acromioclavicular joints with the patient bearing 20 pounds of weight in his hands often help show the amount of separation, and the deformity can be compared with the patient's sound shoulder. The third degree sprain requires surgical repair. The joint should be

opened, the meniscus removed if torn, and the muscle and ligamentous structures repaired. The joint should be fixed temporarily with two transacromial, heavy, threaded Steinman pins. The Steinman pins must be removed before starting shoulder rehabilitation. Conservative treatment consists of strapping to hold the clavicle in place.<sup>10</sup> Strapping of the third degree acromioclavicular separation is difficult and requires daily supervision. Some athletes have refused treatment so that they may continue to participate in the sport. Most remain pain free. Nearly all, however, have an obvious deformity, and reconstructive procedures may be indicated if pain persists.

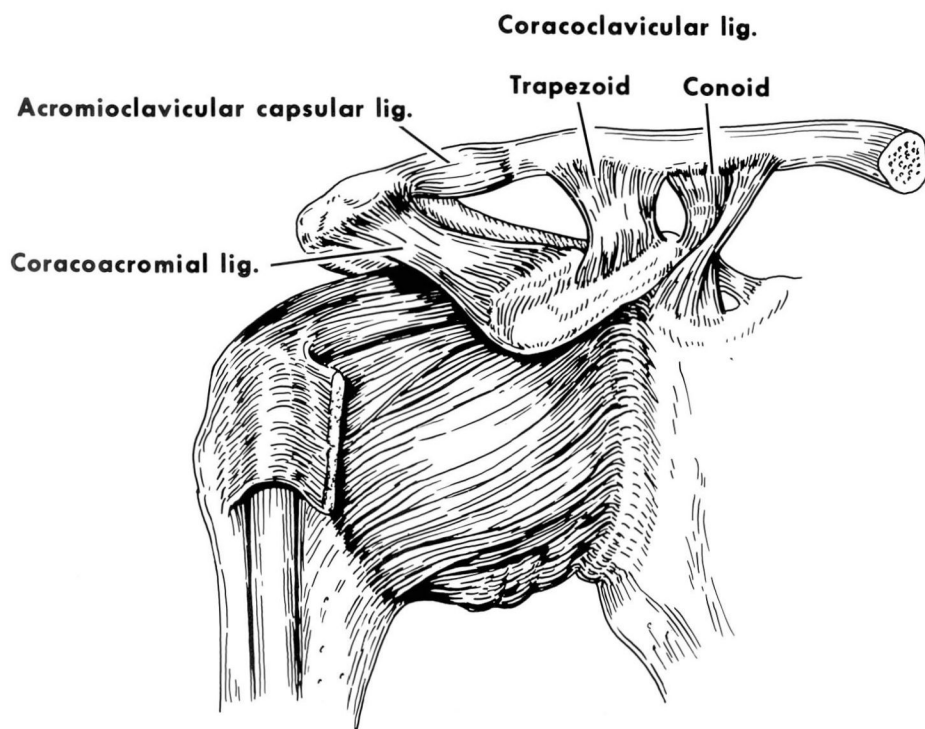


Fig. 4. Ligaments of the shoulder.

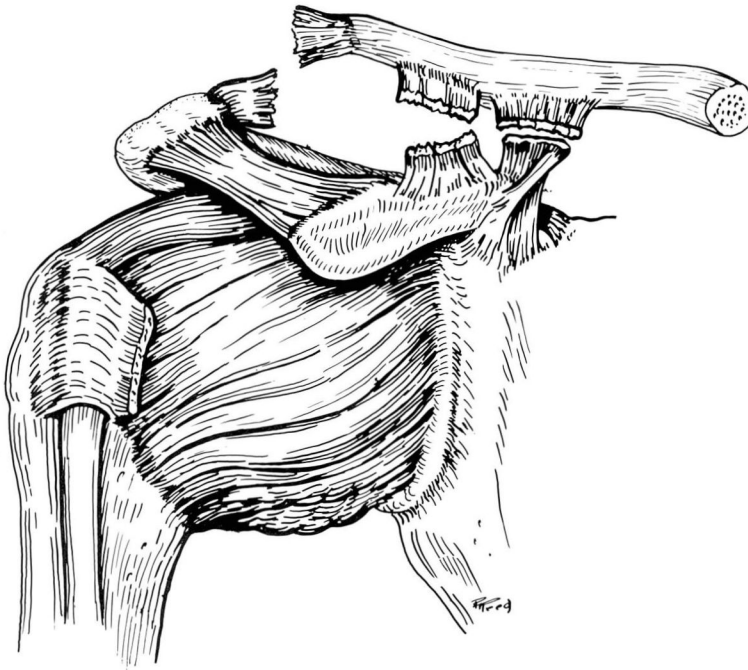


Fig. 5. Third degree sprain of the shoulder.

### Anterior dislocation

Dislocation of the shoulder is one of the common injuries in the athlete. Anterior dislocation may occur when an athlete falls on his outstretched arm, or misses a block or tackle and strikes the opposing player with his arm abducted and externally rotated.<sup>4</sup> Immediate reduction and adequate immobilization are necessary. The difficult problems are those of recurrent dislocation. Three factors must be considered: (1) age of the patient, (2) method of treatment, and (3) degree of trauma. Patients 1 to 10 years of age have 100% recurrence of dislocation. Patients 11 to 20 years of age have 94% recurrence. Those 21 to 30 have a recurrence rate of 79%; after age 50 only 14% have recurrence of dislocation. If the patient receives no treatment, the recurrence rate is 70%. If a simple

sling is used for 3 weeks, there is a 46% chance of recurrence. If a sling and swath are used for up to 3 weeks, the recurrence rate diminishes to 26%.

In most instances, recurrent dislocation requires surgical treatment to provide stability. To eliminate recurrent dislocation, it is necessary either to produce a buttress of the anterior aspect of the shoulder or to limit the external rotation of the shoulder. Consequently, baseball players and quarterbacks usually have restricted motion and less effective delivery after these procedures. The Bristow procedure is preferred for the throwing athlete. The coracoid process and the conjoined tendon of the coracobrachialis and the short head of the biceps are transferred to the anterior rim of the glenoid after splitting the subscapularis tendon. This method produces

a bone and tendon block to anterior dislocation and prevents the subscapularis from riding superiorly when the arm is externally rotated and abducted.<sup>11</sup> The tendon helps prevent dislocation without limiting external rotation. Early results have been encouraging.

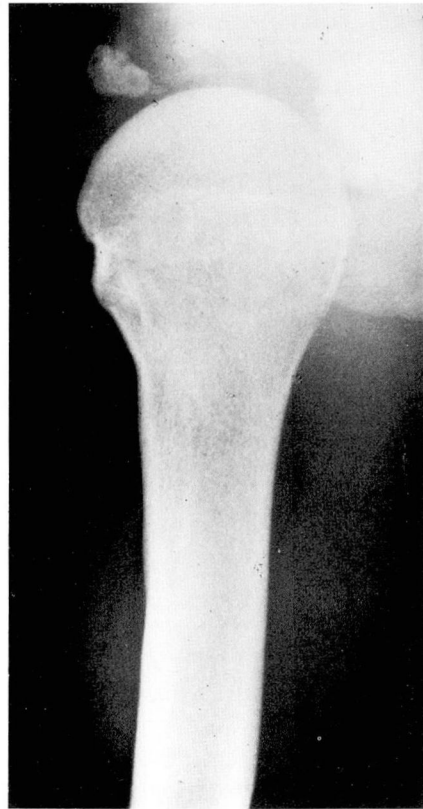### Fracture

Fractures of the shoulder are rare in athletes. Most shoulder fractures occur in the epiphyseal area in adolescent athletes. Comparison films help to evaluate the epiphysis for widening. Occasionally there is gross displacement, and reduction may be difficult. The humerus has a tremendous capacity for remodeling, and this, aided by its great range of motion, tends to compensate for minor angulation deformities. Vigorous manipulation is not indicated if anatomic reduction is not possible.

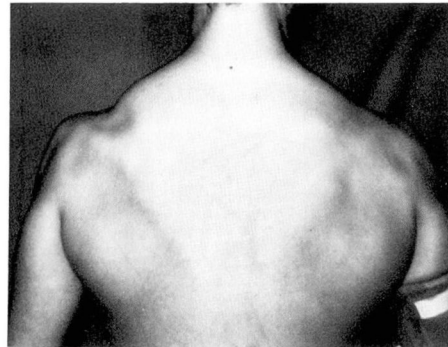
One patient, a tennis player who had pain in the anterior aspect of his arm when serving, had an avulsion fracture. There was tenderness over the biceps tendon and pain when the hand was supinated under stress. Treatment with injections of corticoids into the bicipital groove, heat, massage, and analgesics produced no improvement. An x-ray film of the axilla revealed an old avulsion fracture of the coracoid process (*Fig. 6*). Excision of this fragment and reattachment of the conjoined tendon allowed this patient to resume playing tennis.<sup>12</sup>

### Nerve injury

Pain and limitation of shoulder motion do not always mean injury to the shoulder itself, but may reflect injury to the neck, brachial plexus, or peripheral nerves. A typical "pinched



**Fig. 6.** Avulsion fracture of the coracoid process.



**Fig. 7.** Atrophy of the supraspinatus.

nerve" is really a brachial plexus injury in which the head has been forced toward the opposite side, resulting in electric-like shocks into the shoulder and down the arm. The pain is radicular and bypasses the shoulder joint.

Occasionally pain from the cervical spine may radiate to the shoulder area. A helpful differentiating feature is that most pain radiating to the shoulder from the neck is felt on the dorsum of the shoulder, whereas pain coming from the shoulder itself is usually reflected anteriorly or over the lateral and distal margins of the deltoid. Sensory defects in the forearm and hand are never present with shoulder injury alone.<sup>3</sup> Brachial plexus injury producing inability to abduct the arm may mimic rotator cuff injury.

Atrophy of the deltoid, supraspinatus, and infraspinatus muscles may be found with isolated injury to peripheral nerves of the shoulder, e.g., the suprascapular nerve and the axillary nerve (*Fig. 7*). At the Cleveland Clinic these injuries have been seen more often in wrestlers. A normal arthrogram tends to rule out a rotator cuff tear, and electromyography (EMG) is helpful in diagnosing these cases.

### Summary

Most athletic injuries of the shoulder are amenable to conservative management. The injuries occur in all gradations and should be treated according to severity. Concomitant lesions are not uncommon. Careful evaluation of history and physical and roentgenographic findings aid the clinician in making the diagnosis. Special tests such as arthrography and electromyography cause little mor-

bidity and when necessary should be used for complete investigation. When surgical intervention is indicated, it should not be delayed.

### References

1. Nelson CL: Special diagnostic procedures. *Am Acad Orthop Surg Instructional Course Lectures* 21: 1-6, 1972.
2. O'Donoghue DH: Treatment of Injuries to Athletes. Second edition. Philadelphia, WB Saunders Company, 1970.
3. Bateman JE: Nerve injuries about the shoulder in sports. Symposium on the treatment of injuries to the shoulder girdle. *J Bone Joint Surg* 49A: 785-792, 1967.
4. Hoyt WA Jr: Etiology of shoulder injuries in athletes. *J Bone Joint Surg* 49A: 755-766, 1967.
5. Reeves B: Arthrography of the shoulder. *J Bone Joint Surg* 48B: 424-435, 1966.
6. Brown JT: Early assessment of supraspinatus tears: procaine infiltration as guide to treatment. *J Bone Joint Surg* 31B: 423-425, 1949.
7. McLaughlin L: Rupture of the rotator cuff. Symposium: Surgical lesions of the shoulder. *J Bone Joint Surg* 44A: 979-983, 1962.
8. Nelson CL, Razzano CD: Arthrography of the shoulder. *J Trauma*. In press.
9. Nelson CL: The painful shoulder. *Postgrad Med* 47: 71-78, 1970.
10. Allman FL Jr: Fractures and ligamentous injuries of the clavicle and its articulation. *J Bone Joint Surg* 49A: 774-784, 1967.
11. Helfet AJ: Coracoid transplantation for recurring dislocation of the shoulder. *J Bone Joint Surg* 40B: 198-202, 1958.
12. Benton JW, Nelson CL: Avulsion of the coracoid process in an athlete. Report of a case. *J Bone Joint Surg* 53A: 356-358, 1971.