

Mediastinoscopy

A valuable aid in the diagnosis of intrathoracic disease

FLOYD D. LOOP, M.D.

LAURENCE K. GROVES, M.D.

Department of Thoracic and Cardiovascular Surgery

A CONSISTENT feature of malignant pulmonary neoplasms is their ultimate dissemination into the mediastinal lymphatics. Chest roentgenography may suggest mediastinal spread, but attempts to confirm this and thereby predict the probability of a curative resection have proved difficult short of thoracotomy. Scalene node biopsy, once thought to provide a basis for estimating operability, has turned out to be inefficient and unrewarding unless supraclavicular nodes are already palpable.

Mediastinoscopy, introduced in 1959,¹ offers substantial aid to this dilemma in that pathologic lesions on both sides of the carina can be exposed for biopsy without resorting to thoracotomy. Although the procedure was initially intended for the detection of advanced bronchial carcinoma, our experience with 100 consecutive mediastinoscopies shows that it is a valuable method for diagnosing a wide variety of diseases that infiltrate the mediastinum.

Indications and description of procedure

Various thoracic lesions, inflammatory and neoplastic, can be investigated by means of mediastinoscopy. However, the following radiographic features offer the most favorable indications for this examination: (1) any lung mass other than the peripherally located solitary pulmonary nodule (a central or hilar lesion with roentgenographic or bronchoscopic evidence of mediastinal involvement should be evaluated by mediastinoscopy); (2) bronchial carcinoma in patients who manifest advanced signs (such as atelectasis, diaphragmatic or vocal cord paralysis, pleural effusions, or demonstrate bronchoscopic evidence of extrinsic tracheobronchial compression); (3) enlargement of the mediastinal shadow of unknown cause; and (4) suspected sarcoidosis.

When certain precautions are observed, mediastinoscopy is a remarkably straightforward and safe diagnostic approach and may be used on an outpatient basis. When this method is employed to detect the spread of lung cancer, bronchoscopy should first be performed to locate and biopsy the primary tumor and to assess the bronchoscopic criteria of operability. When

palpable, supraclavicular nodes should be biopsied in preference to mediastinal nodes.

Surgical technic

Mediastinoscopy can be performed with the patient under local anesthesia, but we prefer to use light endotracheal anesthesia, not only for the comfort and safety of the patient but also for the surgeon's technical convenience.

A transverse tracheostomy type of incision exposes the trachea, and the thin pretracheal fascia is incised (*Fig. 1*). This key maneuver allows the index finger to slide along a completely avascular pretracheal plane. Using his index finger as a blunt dissector, the surgeon develops the sulcus on either side of the trachea to gain the widest area of exploration. In this manner,

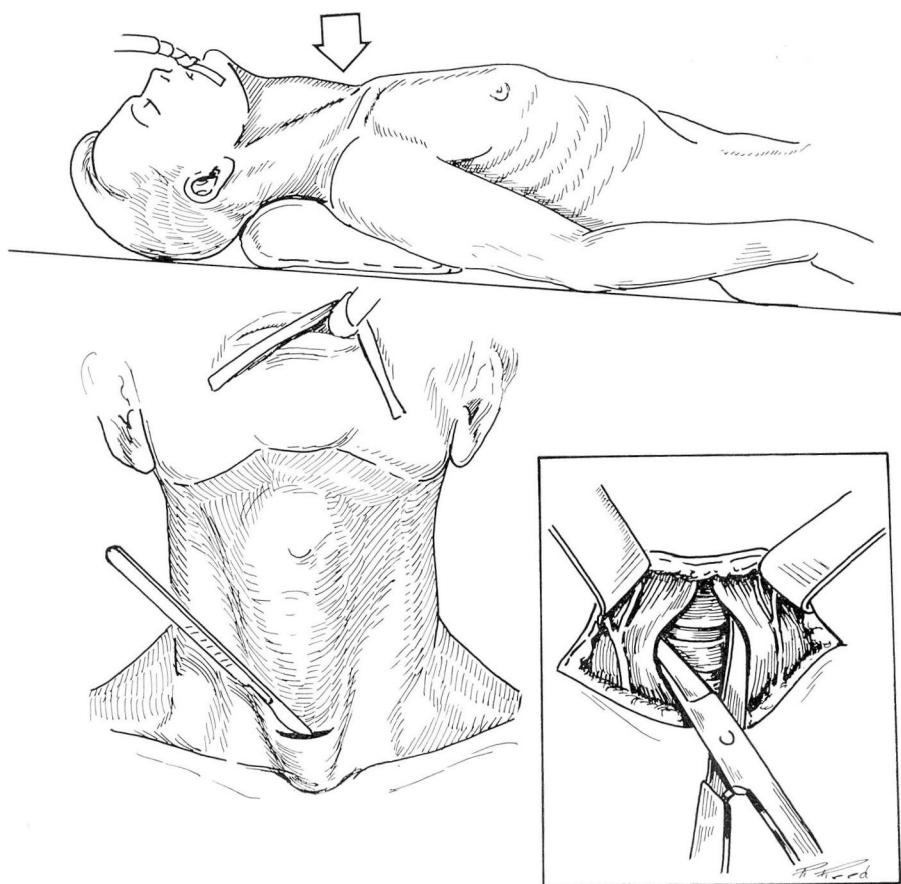


Fig. 1. Drawing shows that with the neck slightly extended, a transverse incision was made to expose the trachea. The avascular pretracheal plane is entered by incising the thin pretracheal fascia.

digital exploration can be carried out posteriorly as far as the spine. Pulsations in the innominate artery and aorta are easily discernible anteriorly, and the average index finger will almost reach the tracheal bifurcation below. The secret in performing safe "buttonhole" surgery of this type is to rely on blunt dissection and to avoid the use of cutting instruments except for the actual biopsy.

Palpation of adenopathy will direct the examiner to the appropriate site for the biopsy when the mediastinoscope is introduced into the digitally prepared plane (*Fig. 2*). When no unusual mass or lymph node enlargement is palpated, further dissection with the suction tip can be carried out, under direct vision, to reach a surprising depth in the anterior mediastinum. In practice, however, when no abnormalities are digitally located, the procedure usually will not be diagnostic.

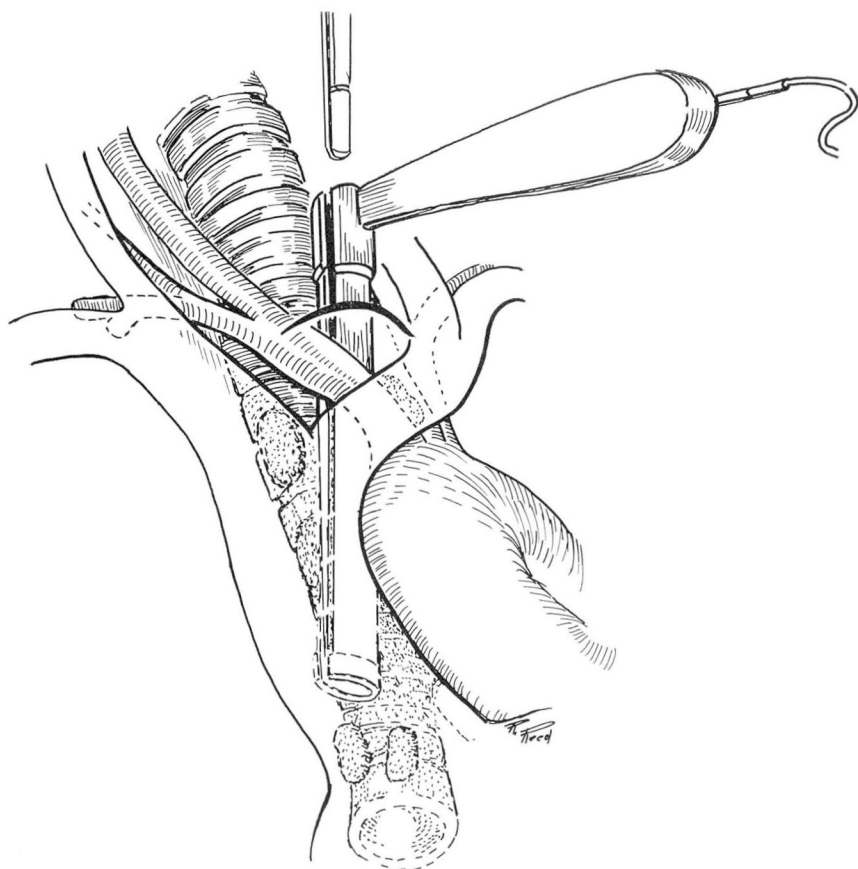


Fig. 2. Palpation of firm adenopathy orients the examiner to the site of biopsy. Drawing shows that after the mediastinoscope has been inserted into the prepared plane, further dissection can be accomplished with the suction tip.

After isolating the biopsy specimen as much as possible, it is our practice to aspirate the tissue with a long 20-gauge needle before inserting the biopsy forceps. This aspiration minimizes the risk of opening one of the larger vessels, especially the azygos vein or pulmonary artery. Persistent oozing after biopsy may require electrocoagulation through the insulated metal suction tip. For hemostasis, on several occasions, gauze packing has been required for a few minutes and, in one instance, a pack was left in place for 24 hours.

Clinical experience

During the two-year period from May 1968 through May 1970, mediastinoscopy was performed in 100 patients at the Cleveland Clinic. A positive biopsy was obtained in each of 55 patients (55 percent) (*Table 1*). One early death occurred in an elderly debilitated woman with diffuse pulmonary infiltrates; autopsy revealed extensive pulmonary emboli. Other complications, such as massive bleeding, infection, or pneumothorax, did not occur.

Among the 100 patients, there were 61 with documented bronchial carcinoma. Mediastinoscopy confirmed lymph node metastasis in 35 of those patients (57 percent of the carcinoma group) (*Table 2*). Of the 26 lung cancer patients whose mediastinal examinations were not diagnostic, 16 underwent

Table 1.—Findings in 100 consecutive mediastinoscopies performed during a two-year period

Results	Mediastinoscopies, number	
Positive		55
Neoplasm	47	
Bronchogenic carcinoma	35	
Other malignant neoplasm	12	
Nonneoplastic disease	8	
Negative		45
Total		100

Table 2.—Types of bronchial carcinoma detected by mediastinoscopy

Carcinoma, type	Number
Undifferentiated or anaplastic	17
Small cell	9
Squamous cell	7
Adenocarcinoma	2
Total	35

Table 3.—Diseases other than lung cancer diagnosed in 100 consecutive mediastinoscopies

Disease	Mediastinoscopies, number	
Benign	8	
Sarcoid	5	
Goiter	2	
Histoplasmosis	1	
Malignant	12	
Reticulum cell sarcoma	4	
Hodgkin's disease	3	
Lymphocytic lymphoma	1	
Thymoma	1	
Metastatic renal carcinoma	1	
Metastatic prostate carcinoma	1	
Metastatic esophageal carcinoma	1	
Total	20	

exploratory thoracotomy, and in 12 (15 percent) resections were performed. In the other 10 patients with cancer, who had negative mediastinoscopies, the disease was obviously too advanced for curative operation, and mediastinoscopy was employed in an effort to obtain a tissue diagnosis.

Since this procedure is relatively new, our criteria for selecting cases were somewhat liberal early in the series. These instances included abdominal carcinoma producing pleural effusion, a questionably widened mediastinum, and cavitary lung disease. No final diagnosis was reached in eight of those cases (8 percent).

A group of benign and malignant conditions unrelated to bronchial cancer were diagnosed solely from the mediastinal examination (*Table 3*). Suspected sarcoidosis was confirmed in all five patients in whom biopsy was performed. In the group with malignant neoplasms, lymphoma and reticulum cell sarcoma were frequent findings after chest roentgenograms revealed mediastinal enlargement.

Discussion

Mediastinoscopy has been widely employed for many years in the Scandinavian countries but utilized little in the United States until 1965. Fear of manipulating a rigid instrument close to the great vessels probably explains its slow acceptance. In the last 10 years, though, the surgical literature has attested to the success of this biopsy technic, and its safety is now unquestioned.

There are two logical reasons for the higher diagnostic yield from mediastinoscopy in comparison to that of scalene node biopsy. First, samples from lymph nodes on both sides of the carina are available through the

mediastinoscope and, therefore, metastases crossing to the opposite side can be removed through one approach. Secondly, nodes at the carinal level are more central in location and represent an earlier stage of lymph node metastasis than the later spread to scalene or supraclavicular nodes.

Although the positive yield from mediastinal node biopsy diminishes as the lesion moves peripherally,² Pearson³ routinely performed mediastinoscopy on all presumably resectable cases of bronchial carcinoma. He found that one third of the patients already had positive mediastinal nodes. Of the other patients who underwent explorative surgery after a negative examination, resection was possible in 94 percent.

Ashbaugh⁴ surveyed the experience of 30 authors with mediastinoscopy, and found an average of 38 percent positive biopsies in patients with bronchial carcinoma. Among our series of 61 lung cancer cases, extension into the superior mediastinal nodes was demonstrated in 57 percent. This percentage results from differences in selecting the patients for examination. We did not use mediastinoscopy in all cases of bronchial carcinoma but only for those in whom we suspected mediastinal involvement.

Traditionally, metastasis to the paratracheal nodes signifies that the carcinoma has extended beyond the limits of a curative resection. No argument exists when the metastatic process is extensive or has crossed to the opposite side. But how does one interpret a positive ipsilateral node associated with an otherwise favorable operative outlook? In a recent editorial, Bell⁵ examined this question and pointed out that as high as 22 percent of surgically treated patients with cancer of the lung survived five years with proved mediastinal metastasis. Except in the case of small cell carcinoma, the surgeon may be hesitant categorically to reject all patients with positive mediastinal nodes unless the roentgenographic picture suggests considerable spread into this area. The entire clinical picture—radiographic, mediastinoscopic, and bronchoscopic findings—must be correlated in each individual case.

Apart from the findings of advanced lung carcinoma, this technic has become valuable in detecting other diseases located throughout the mediastinum. In our series, 10 separate pathologic entities were diagnosed entirely from mediastinoscopy. Of the benign conditions, sarcoidosis has received the most attention and justifiably so. Here the accuracy rate of almost 98 percent is far superior to any other means of diagnosis.⁶

A more recent application of mediastinoscopy has been the prediction of operability in esophageal carcinoma. Akovbiantz and associates⁷ reported positive mediastinal lymph nodes in 50 percent of middle third lesions, and 25 percent for carcinoma in the lower third of the esophagus.

As technical modifications are described, even posterior mediastinal areas can now be examined,⁸ and the list of diseases within reach of the mediastinoscope continues to grow. In selected cases of lung cancer, the basic virtues of the procedure remain well founded. Mediastinoscopy has raised

the frequency of obtaining a preoperative tissue diagnosis, and has increased the rate of resectability to between 80 and 90 percent after a negative examination.⁹ The wasted time, expense, and pain related to a needless thoracotomy can be largely avoided, a benefit provided by mediastinoscopy, which may be its most important contribution.

Summary

Indications, technic, and results in a two-year experience with 100 mediastinoscopic examinations are presented. Ten different pathologic entities other than bronchogenic carcinoma were detected and confirmed through mediastinal biopsy. Frequent findings include lymphomas and sarcoidosis. Mediastinal lymph node metastasis was found in 57 percent of the 61 patients with bronchogenic carcinoma. After a nondiagnostic mediastinoscopy, 75 percent of those patients underwent curative resection. The high diagnostic yield associated with mediastinoscopy avoids many needless thoracotomies, and conversely leads to a higher resectability rate when the examination is negative.

References

1. Carlens, E.: Mediastinoscopy: a method for inspection and tissue biopsy in the superior mediastinum. *Dis. Chest* 36: 343-352, 1959.
2. Reynders, H.: Mediastinoscopy in bronchogenic carcinoma. *Dis. Chest* 45: 606-611, 1964.
3. Pearson, F. G.: An evaluation of mediastinoscopy in the management of presumably operable bronchial carcinoma. *J. Thorac. Cardiovasc. Surg.* 55: 617-625, 1968.
4. Ashbaugh, D. G.: Mediastinoscopy. *Arch. Surg.* 100: 568-573, 1970.
5. Bell, J. W.: On the significance of mediastinoscopy. *Amer. J. Surg.* 118: 1-2, 1969.
6. Jepsen, O.: Mediastinoscopy. Copenhagen: Munksgaard, 1966, 163 p.; p. 115.
7. Akovbiantz, A., and others: Die Bedeutung der Mediastinoskopie für die Beurteilung der Operabilität des Oesophaguscarcinoms. *Langenbeck Arch. Klin. Chir.* 313: 360-363, 1965.
8. Specht, G.: Erweiterte Mediastinoscopie. *Thoraxchirurgie* 13: 401-407, 1965.
9. Bergh, N. P.; Rydberg, B., and Scherstén, T.: Mediastinal exploration by the technique of Carlens. *Dis. Chest* 46: 399-410, 1964.