

Percutaneous cervical cordotomy for relief of intractable pain

PHILIP L. GILDENBERG, M.D.

Department of Neurologic Surgery

THE treatment of intractable pain that is caused by metastatic disease or by a benign condition is frequently a frustrating endeavor. Surgical section of the anterolateral portion of the spinal cord has been used for many years to interrupt the pain pathways and render the patient insensitive to pain that could not be more specifically treated. However, many patients, especially those with metastatic disease, are unable to tolerate such surgery.

Percutaneous cervical cordotomy recently has been developed to spare the patient the necessity of undergoing surgical interruption of the pain pathways. In this procedure, a needle electrode, guided by means of roentgenography, is inserted into the anterolateral quadrant of the spinal cord in the cervical region, and an electric current forms a lesion that interrupts the pain pathways. The pathways transmitting sensation for other sensory modalities, such as touch and proprioception, are not affected, nor are the pathways involved with motor function.

Technic

As originally devised by Mullan and associates,¹ and reported in 1963, a needle was introduced from the lateral direction between the posterior arch of the first and the lamina of the second cervical vertebrae. Originally, the needle was introduced somewhat obliquely and the lesion was made by the application of radioactive material. However, the technic was later modified by Rosomoff and associates² so that the needle electrode is introduced in the coronal plane and the lesion is made by the application of a radiofrequency current.

The procedure is performed under local anesthesia. The patient is placed in the supine position with the head resting on the X-ray table and X-ray tubes placed so that anteroposterior and lateral roentgenograms can be made with identical magnification. The neck is prepared and local anesthesia is infiltrated just below the lobe of the ear contralateral to the pain. An 18-gauge lumbar puncture needle is directed horizontally between the posterior arch of the first and the lamina of the second cervical vertebrae until the tip lies in the subarachnoid space. Then a small amount of air is introduced through the needle in order to outline the anterior surface of the spinal cord, and the electrode is advanced to the target (*Fig. 1*).

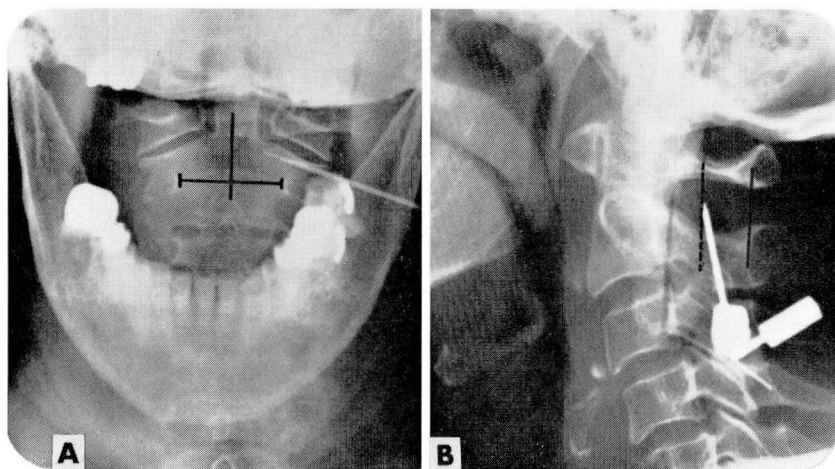


Fig. 1. Roentgenograms of the upper cervical level show the needle electrode inserted between the posterior arch of the first cervical vertebra and the lamina of the second cervical vertebra into the anterolateral quadrant of the spinal cord.

The target point depends on the area to be rendered analgesic. The midline is determined by bisecting the distance between the pedicles demonstrated in the anteroposterior roentgenogram. If cervical or thoracic analgesia is desired the target lies 4 mm lateral, and if lumbosacral analgesia is desired the target point is 8 mm lateral, which corresponds to the somatotopic distribution of these fibers in the lateral spinothalamic tract. The target lies 3 mm behind the anterior surface of the spinal cord, which is 2 mm anterior to the dentate ligament.

This technic is still frequently employed when it is necessary to produce a lesion in the upper cervical spinal cord, as when pain affects the shoulder or upper extremity. However, with bilateral lesions in upper cervical levels, embarrassment of respiratory function can occur. Consequently, some surgeons restrict the use of upper cervical percutaneous (as well as surgical) cordotomy to unilateral lesions. Rosomoff, as reported with Tenicela and associates,³ is the only neurosurgeon who still advocates creating bilateral lesions in the upper cervical area. They³ make a detailed evaluation of pulmonary function after making the first lesion, and will only produce a second lesion if the respiration has not been affected by a single lesion.

The pattern of respiratory difficulty produced by bilateral upper cervical lesions is unique. The patient appears to breathe quite normally while he is awake. Only tests can disclose minor changes in respiratory function; when the patient falls asleep, reflex respiration is not sufficient to maintain the patient's oxygen requirements and he asphyxiates. Commonly, the patient is found dead in bed within an hour after he falls

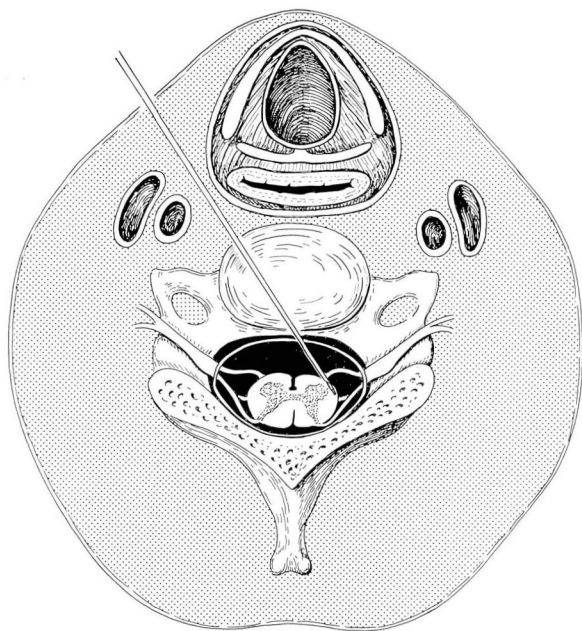


Fig. 2. Drawing shows that the needle electrode is directed diagonally through the disk to the contralateral spinothalamic tract.

asleep. Fortunately, this complication ordinarily occurs only after bilateral lesions are made.

Because of the threat of respiratory complications, Lin, Gildenberg, and Polakoff⁴ in 1965 devised a percutaneous cervical cordotomy procedure at the lower cervical levels, below emergence of the respiratory fibers. The needle electrode is inserted under roentgenographic guidance diagonally through the intervertebral disk to a target point in the anterolateral quadrant of the spinal cord in the lower cervical region (*Fig. 2*). Because the somatotopic orientation of the pain fibers in this region is dispersed over a wider area than at the upper cervical region, it frequently is possible to produce analgesia only in the affected extremity or to render the trunk insensitive to pain but to spare the extremities.

The target point at the lower cervical region also is selected to correspond to the desired level of analgesia.⁴ When the lower extremity or pelvic region is affected, the target point is 8 mm lateral and from 5 to 6 mm anterior to the posterior surface of the spinal cord. When thoracic pain is the problem, the target point lies 4 mm lateral and is near the anterior surface of the cord, i.e., 8 mm anterior to the posterior surface (*Fig. 3*). Since the spinal cord lies in the midline against the posterior wall of the spinal canal with the patient in the supine position, these target

points can be located from the anteroposterior and the lateral projections of the roentgenograms of the cervical spine.

In lower percutaneous cervical cordotomy as well, the patient is placed in the supine position with the head resting on the X-ray unit. Under local anesthesia an 18-gauge lumbar puncture needle is passed just lateral to the trachea until the tip of the needle lies just within one of the lower cervical intervertebral disks. Roentgenograms in the anteroposterior and lateral projections are made and the angle of insertion is calculated.⁵ The needle, under the guidance of additional roentgenograms, is further advanced through the intervertebral disk into the subarachnoid space. The obturator of the needle is removed and the stylet of the electrode inserted. The electrical impedance of the cerebrospinal fluid is measured and the needle electrode is advanced until the tip lies at the

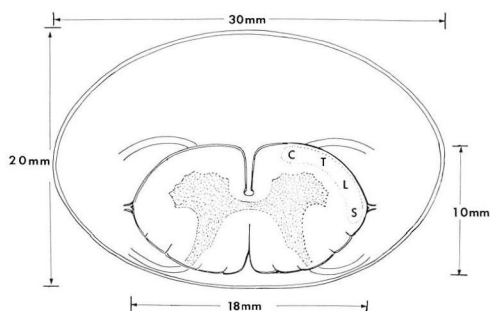


Fig. 3. Drawing shows spinal cord lying against the posterior wall of the canal. The target point at the appropriate location within the lateral spinothalamic tract can be determined by measuring laterally from the midline of the canal or anteriorly from the posterior wall of the canal.

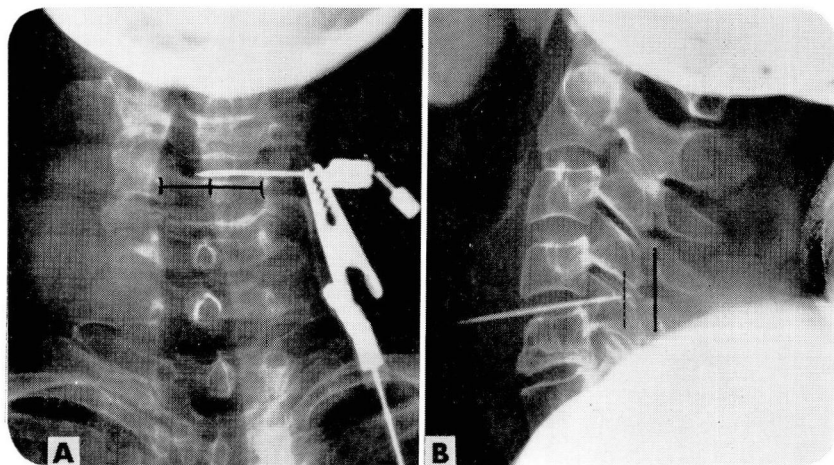


Fig. 4. Roentgenograms of the lower cervical spine demonstrate the needle electrode inserted diagonally through the intervertebral disk to the target point within the spinal cord.

target point within the spinal cord (*Fig. 4*). A change in the electrical impedance verifies that the electrode has penetrated the pia surrounding the cord.⁶ The production of the lesion is the same whether it is produced at the second cervical level or at the lower region of the cervical spinal cord. Frequently, electrical stimulation is applied before production of the lesion. The patient may perceive a sensation of heat or cold or paresthesias on the opposite side of the body. This sensation verifies that the tip of the electrode lies within the fibers of the lateral spinothalamic tract.

The lesion is then made with brief bursts of radiofrequency current. Between each burst, the level of analgesia is tested with pinprick, and the lesion is gradually enlarged until a satisfactory level of analgesia is obtained. Because the patient's cooperation is necessary to determine the appropriate extent of the lesion, it is necessary to perform percutaneous cervical cordotomy under local anesthesia.

Results

The author has participated in the performance of more than 200 percutaneous cervical cordotomies.* The most recent statistics represent 188 consecutive cordotomies, 28 at the second cervical vertebral level by the lateral approach, and 160 at the lower cervical level by the anterior approach. These procedures were performed in 119 patients, including 33 who had bilateral lesions in the lower cervical level. Four patients each had a lesion at the second cervical vertebral level on one side and a lesion at the lower cervical level on the other side. Satisfactory relief of pain was obtained in 131 patients (82 percent) with lesions at the lower cervical level, and in 24 patients (85 percent) with lesions at the upper cervical level.

It is sometimes necessary to repeat the procedure when relief is not initially obtained or when pain recurs. One of the major advantages of the percutaneous technic is that the procedure can easily be repeated, and there is just as much chance for successful relief of pain after repeating the procedure as there had been on performing it initially.

No respiratory complications have occurred since the use of the lower cervical cordotomy. Previously, in four patients fatal respiratory complications developed after lesions at the second cervical level. Three patients each had bilateral lesions and one patient had undergone pneumonectomy before percutaneous cervical cordotomy.

After lesions were produced at the lower cervical level, 27 patients (17 percent) exhibited transient weakness in the ipsilateral arm or leg, compared to nine patients (32 percent) after production of lesions at the second cervical vertebral level. In all but one patient the weakness disap-

* This study was begun jointly with Dr. Paul M. Lin and Dr. Pedro P. Polakoff, II, Jenkintown, Pennsylvania. The author herewith thanks them for graciously permitting the data of their patients to be included in the statistical analysis, and also Dr. Marc A. Flitter for his invaluable assistance. The project is currently being continued at the Cleveland Clinic.

peared within three weeks. Four other patients (2.5 percent) each noted a clumsy feeling of the ipsilateral hand for from 8 to 10 weeks. Transient urinary retention lasting less than three days occurred in 10 patients (6 percent) who had not had previous urinary tract involvement from metastatic disease or surgery.

Summary

The percutaneous method of performing cordotomy results in relief of intractable pain comparable to that obtained after surgical cordotomy with little morbidity and low incidence of permanent complications. In addition, the percutaneous procedure can easily be repeated when satisfactory relief of pain is not obtained or when pain recurs after several months or years.

References

1. Mullan, S., and others: Percutaneous interruption of spinal-pain tracts by means of a strontium⁹⁰ needle. *J. Neurosurg.* **20**: 931-939, 1963.
2. Rosomoff, H. L., and others: Percutaneous radiofrequency cervical cordotomy: technique. *J. Neurosurg.* **23**: 639-644, 1965.
3. Tencella, R., and others: Pulmonary function following percutaneous cervical cordotomy. *Anesthesiology* **29**: 7-16, 1968.
4. Lin, P. M.; Gildenberg, P. L., and Polakoff, P. P.: An anterior approach to percutaneous lower cervical cordotomy. *J. Neurosurg.* **25**: 553-560, 1966.
5. Gildenberg, P. L., and others: Anterior percutaneous cervical cordotomy: determination of target point and calculation of angle of insertion; technical note. *J. Neurosurg.* **28**: 173-177, 1968.
6. Gildenberg, P. L., and others: Impedance measuring device for detection of penetration of the spinal cord in anterior percutaneous cervical cordotomy; technical note. *J. Neurosurg.* **30**: 87-92, 1969.