

# THE DIAGNOSIS AND TREATMENT OF GLOMUS TUMOR

GEORGE S. PHALEN, M.D., AND DEMETRIOS I. MOUROULIS, M.D.\*

*Department of Orthopedic Surgery*

**I**N the *Edinburgh Medical Journal* of 1812, Wood<sup>1</sup> described a small, bluish, benign, subcutaneous nodule associated with severe paroxysmal pain and tenderness. He called this lesion a "painful subcutaneous tubercle." In 1878, Kolaczek<sup>2</sup> described the subungual location of a painful tubercle, which he believed to be a variant of angiosarcoma. We are indebted to Barré<sup>3</sup> and to Masson<sup>4</sup> for the correct interpretation of the pathologic anatomy of this painful tubercle. They called it a glomus tumor because of its relationship to the normal neuromyoarterial glomus.

The diagnosis of glomus tumor is frequently overlooked or missed because of the physician's lack of familiarity with the lesion. Glomus tumor should be considered in the differential diagnosis of any acutely painful subcutaneous or subungual lesion.

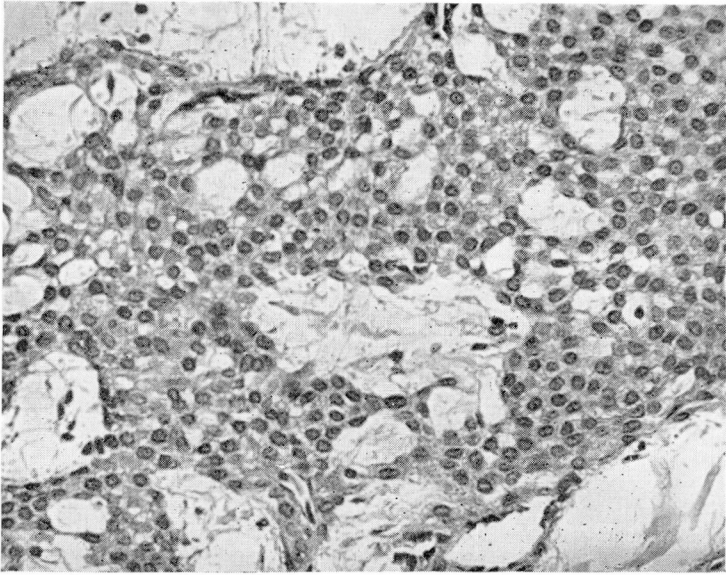
The glomus is a normal structure in the stratum reticulare corii and seldom is more than 1 mm. in diameter. The glomus is a specialized anastomotic mechanism connecting a terminal arteriole with a primary venule. The efferent arteriole branches into a tortuous anastomotic vessel that has an endothelial lining and two ill-defined muscular layers. Situated among the muscle cells are clear epithelioid cells having oval or globular nuclei—the so-called glomal cells (*Fig. 1*); these cells are thought to be closely related to the pericytes, which normally are scattered at intervals over the outer surface of capillaries. The glomus is surrounded by a fibrous capsule and is richly supplied with sympathetic nerve fibrils.

The function of the normal glomus is most likely that of temperature regulation of the peripheral tissues, through control of peripheral blood flow and peripheral blood pressure.

A glomus tumor probably is not a true neoplasm but merely a hypertrophic normal glomus. The tiny glomera are found only in warm-blooded animals and in the exposed parts of the skin. In man, glomera have been found only in the hands and feet. Glomus tumors, however, have been reported to occur in many other locations in the body.<sup>5</sup> This wide distribution is explained on the basis that the glomus tumor arises from pericytes, which are found wherever there are capillaries.<sup>6</sup>

Although an occasional report is published of an infiltrative or metastasiz-

\* Formerly Fellow in the Department of Orthopedic Surgery; present address: Solonos 125, Athens T. 142, Greece.



**Fig. 1.** Microscopic appearance of a group of glomus cells. These clear epithelioid cells have oval or globular nuclei and are thought to be closely related to pericytes. Hematoxylin-eosin stain; magnification  $\times 280$ .

ing glomus tumor,<sup>7</sup> this tumor should not be thought of as being potentially malignant. Glomus tumors are rarely multiple; only 23 cases of multiple glomus tumors have been reported.<sup>8</sup>

Glomus tumors are slightly more common in males than in females. No special age group is commonly affected, although most patients with glomus tumor are between 20 and 40 years of age. Kohout and Stout<sup>9</sup> searched the literature for cases of glomus tumor beginning in childhood. Of 731 well-documented cases of glomus tumor, only 46 occurred in children before the age of 16 years.

A history of trauma is seldom obtained in cases of glomus tumor. When there has been trauma, the immediate effects of the injury will have subsided before the symptoms of the tumor appear.

#### SIGNS AND SYMPTOMS

One should suspect the presence of a glomus tumor whenever confronted by an extremely painful, small, discrete area or nodule that causes stabbing, burning, lancinating pain, often with only the slightest pressure. The pain often radiates up the arm, or leg, and may be mistaken for a true radicular type of pain. This acute, agonizing pain is usually initiated by contact with

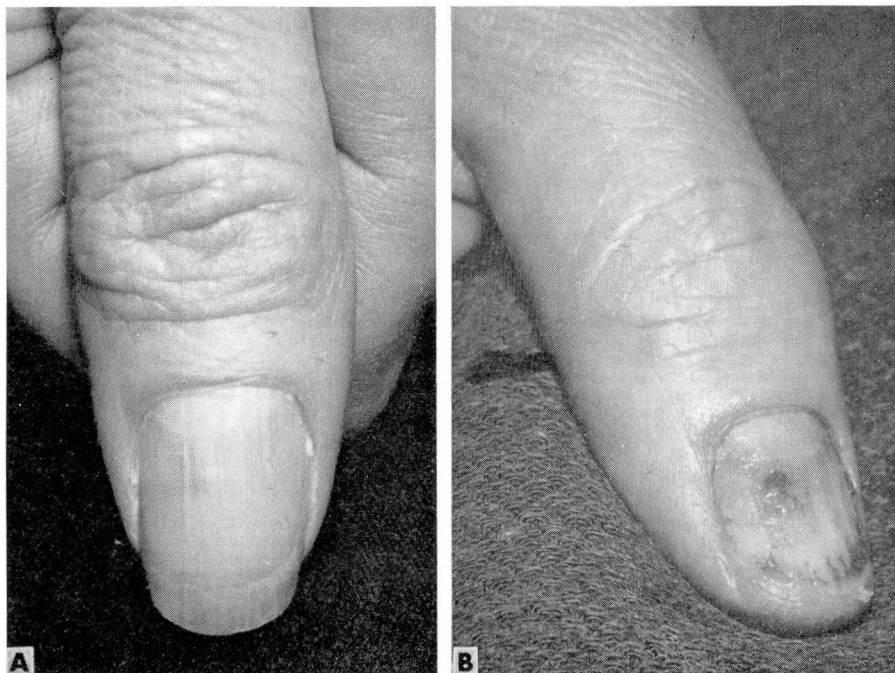

Fig. 2. A, the small, round area of discoloration beneath the woman's thumbnail presents the typical appearance of a glomus tumor. B, after careful complete avulsion of the nail, the extent of the lesion is obvious and total excision of the tumor is readily accomplished.

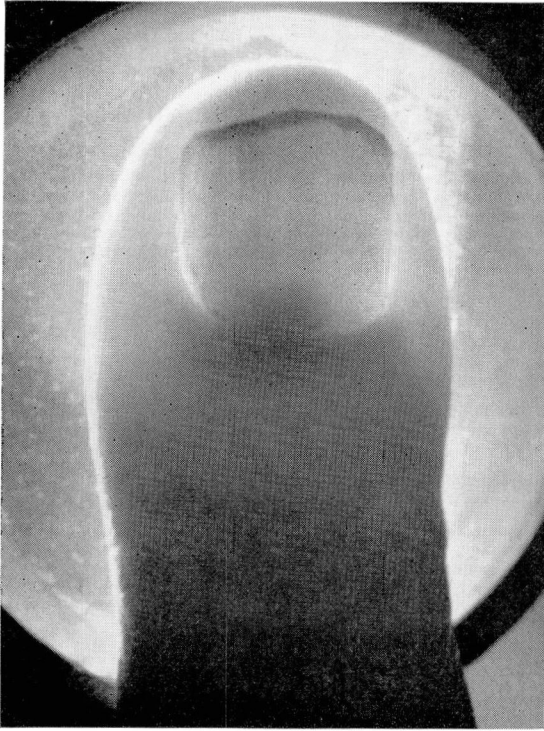
the tumor area, or with changes in temperature. Rarely the attacks of pain arise spontaneously.

When the tumor is visible, as in the subungual region, it appears as a bluish or reddish-purple nodule (*Fig. 2A*). The tumor may resemble a small thrombosed varix. Frequently the tumor cannot be seen or palpated because it is too small or too deeply embedded in the subcutaneous tissue. Transillumination may help to delineate the subungual lesion (*Fig. 3*). Roentgenograms of the digit may show pressure atrophy of the distal phalanx (*Fig. 4*), like that caused by other subungual lesions.

#### DIFFERENTIAL DIAGNOSIS

The diagnosis of glomus tumor is not difficult if the clinician has the possibility in mind at the time of the examination. Other types of subungual lesions must be considered, but these seldom present the painful crises or the exquisite tenderness of glomus tumors. The *subungual hematoma* has an acute onset after trauma. The pain diminishes with time and the dis-





**Fig. 3.** The glomus tumor at the base of the thumbnail was readily visible only by transillumination.

coloration beneath the nail migrates distally with the growth of the nail. This does not occur with a glomus tumor. Other tumors, such as *neurofibroma*, are usually larger than glomus tumors and do not produce paroxysms of pain. The *subungual melanoma* often is ulcerative and does not cause the crises of pain so typical of glomus tumor. The *subungual exostosis* is often exceedingly painful, but a roentgenogram makes differentiation of this lesion readily possible. The *subungual clavus* or *papilloma* is neither bluish nor exquisitely painful.

In locations other than the subungual region, one must consider an *amputation neuroma*. A history of trauma and the location of the tumor along the path of a sensory nerve make this diagnosis simple. *Angiomas* are indistinguishable from glomus tumors on inspection, but palpation of an angioma usually causes little pain. *Osteoid-osteoma* might be confused with a glomus tumor; osteoid-osteoma causes a strictly localized pain, though not the paroxysmal type of pain typical of the glomus tumor. The relief of pain with aspirin and the characteristic appearance of the roentgenogram confirm the diagnosis of osteoid osteoma.

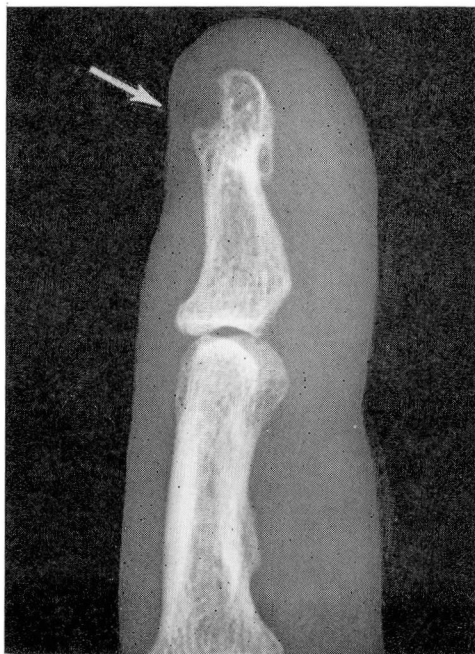

Fig. 4. A roentgenogram of the lateral view of the distal phalanx, index finger. The arrow points to a region of bone erosion, in the tuft of the distal phalanx, produced by pressure of a subungual glomus tumor.

### TREATMENT

Complete surgical excision is the only satisfactory treatment of a glomus tumor. Roentgentherapy has not proved effective in eradicating this tumor. The tumor must be totally excised to prevent local recurrence.

Local anesthesia usually suffices for the removal of a glomus tumor, especially in the subungual area. The surgeon, however, must allow plenty of time for the anesthesia to take effect before touching the tumor. The operation is greatly facilitated and complete removal of the mass is ensured if the surgeon has a bloodless field. This is best obtained by use of a pneumatic tourniquet about the upper arm for from 10 to 15 minutes. Avulsing the nail completely (*Fig. 2B*) will provide much better exposure than removing only the portion of the nail directly overlying the tumor.

When general anesthesia is to be employed, the lesion must be localized as accurately as possible before the patient is anesthetized.

### DISCUSSION

We have reviewed the case records of a series of 12 patients having glomus tumors treated at the Cleveland Clinic during the last thirty years. There were 5 males and 7 females in this series, having an average age of 40 years.

Eight of the tumors each lay beneath a fingernail or a thumbnail; one was along the medial aspect of the proximal interphalangeal joint of the index finger; one was in the palm; one over the tip of the olecranon process of the ulna; and one over the base of the fifth metatarsal. All of these patients were completely relieved of pain by excision of the tumors and there have been no recurrences of the tumors. Local anesthesia was used in all but one patient. The tumors ranged in diameter from 0.9 mm. to 4 mm. The duration of symptoms ranged from 4 weeks to 20 years, and there was a history of possible trauma for only two patients.

Two patients in this series were especially interesting from a clinical standpoint. One patient was a 39-year-old woman examined in 1930 because of pain and "numbness" radiating from the right index finger up to the shoulder. No tumor was visible in the right hand. She was first given an empirical course of roentgentherapy, without obtaining relief. Because roentgenograms of the cervical spine showed a short cervical rib, the anterior scalene muscle was sectioned, without giving relief. Three years later the patient insisted upon having an amputation to relieve the pain, and removal of the distal phalanx of the index finger produced a complete cure. The tiny glomus tumor, 0.9 mm. in diameter, was demonstrated only after meticulous pathologic study.

The second patient was a 48-year-old man, a dentist, who had been having pain in his right foot for 24 years. This pain was always localized over the base of the fifth metatarsal. There was a vague history of stepping on a stone some time before the onset of symptoms. There was no visible tumor, no palpable mass, and no changes evident on the roentgenogram of the foot. Over the years the patient had received many modalities of treatment to his foot, including arch supports, physical therapy, and special shoes. He finally had to discontinue his practice of dentistry because of the agonizing pain always occurring when he so often struck his right foot with the pedal of his dental drill. Before a general anesthetic was administered to him, the area of excruciating tenderness was carefully marked on the lateral aspect of the right foot. An incision directly over this area exposed a 4-mm., purplish-red, soft, neoplastic mass lying over the base of the fifth metatarsal. Removal of this glomus tumor gave immediate and lasting relief.

#### CONCLUSION

Once a physician has seen a patient who has a glomus tumor, he is not apt to miss this diagnosis in other patients, as no other lesion is so likely to produce the severe lancinating paroxysms of pain. A mistaken diagnosis may lead to too radical surgery or, as is more often the case, to a diagnosis of psychoneurosis. The glomus tumor is tiny, but the relief obtained by its

excision is great. The surgeon will have no patient more grateful than the one from whom he has removed a glomus tumor.

#### REFERENCES

1. Wood, W.: On painful subcutaneous tubercle. *Edinburgh M. J.* **8**: 283, 1812.
2. Kolaczek, J.: Ueber das Angio-Sarkom. *Deut. Zschr. Chir.* **9**: 165-227, 1878.
3. Barré, J. A.: Troubles Sympathiques Étendus et Violents du Membre supérieur par Tumeur du Doigt. Guérison. (Abs.) 24<sup>e</sup> Congrès des Aliénistes et Neurologistes de France et des Pays de Langue Française, Session de Strasbourg, 2-7 août 1920. *Rev. Neurol.* **36**: 942-943, 1920.
4. Masson, P.: Le Glomus Neuromyo-artériel des Régions Tactiles et ses Tumeurs. (The glomus of tactile regions.) *Lyon chir.* **21**: 257-280, 1924.
5. Shugart, R. R.; Soule, E. H., and Johnson, E. W., Jr.: Glomus tumor. *Surg. Gynec. & Obst.* **117**: 334-340, 1963.
6. Murray, M. R., and Stout, A. P.: Glomus tumor; investigation of its distribution and behavior, and identity of its "epithelioid" cell. *Am. J. Path.* **18**: 183-203, 1942.
7. Randerath, E., and Candreviotis, N.: Über einen malignen metastasierenden Glomustumor des rechten Daumens. *Zentralbl. allg. Path.* **93**: 454-459, 1955.
8. Sluiter, J. T., and Postma, C.: Multiple glomus tumours of the skin. *Acta dermat.-venereol.* **39**: 98-107, 1959.
9. Kohout, E., and Stout, A. P.: The glomus tumor in children. *Cancer* **14**: 555-566, 1961.