

THE VARIABLE ROENTGENOGRAPHIC APPEARANCE OF INVAGINATION OF THE ESOPHAGUS

BASED ON THIRTEEN CASES

BARRY Q. WALKER, M.D.*

Division of Radiology

INVAGINATION of the esophagus is a physiologic process in which the distal portion of the esophagus moves downward into the gastric cardia. Invagination is usually associated with a small hiatus hernia that on roentgenograms creates a filling defect that has been likened to a "jack-in-the-pulpit" or "Saturn ring." Occasionally the esophagus invaginates into the gastric cardia below the diaphragm, thus creating a large cup-shaped filling defect. Esophageal invagination is commonly associated with dysphagia¹ and this is of some clinical significance. Complications such as esophagitis and obstruction have seldom been reported as related to this disorder.^{1, 2} The transient nature of the phenomenon probably accounts for its infrequent recognition and reporting in the literature.

The exact mechanism of invagination of the esophagus into the stomach is still not resolved. Sliding of the esophageal mucosa into a hiatus hernia is a current and logical explanation for the radiographic appearance in most cases. Invagination may be minimal or extend deeply into the cardia. Minimal invagination will often be demonstrated only when the patient is prone, with compression or straining maneuvers. Extensive invagination is quite readily demonstrable, and may be seen when the patient is supine or prone, without special maneuvers to increase intraabdominal pressure.

The 13 cases that are the basis of this report were identified from 270 consecutive cases of sliding and 11 fixed hiatus hernias seen at the Cleveland Clinic during the last two years. All patients underwent fluoroscopic examination by the author; views were taken in upright, prone, and supine positions. Patients were instructed in the Valsalva maneuver, as well, and selective films were exposed during this procedure. Of the 13 patients, 11 had small sliding hiatus hernias and 2 had large fixed hiatus hernias. No patient had invagination with a paraesophageal hiatus hernia, nor radiographic evidence of esophagitis or obstruction. Only three patients had substernal distress and none had dysphagia. Eight patients were entirely asymptomatic, and two of these patients had the large fixed hiatus hernias. Ten of the 13 patients in the series were women, similar to the sex distribution

* Formerly Member of the Staff, Cleveland Clinic; present address: Department of Radiology, Lutheran Hospital, 2609 Franklin Boulevard, Cleveland, Ohio 44113.

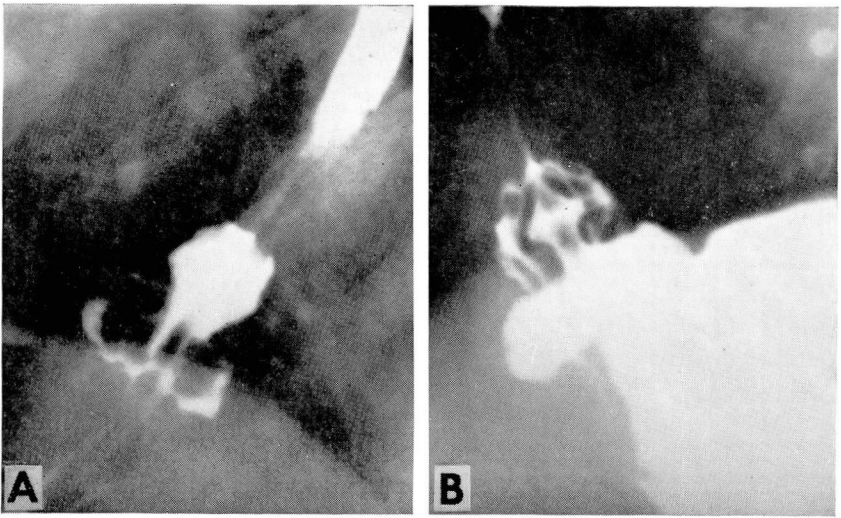


Fig. 1. Roentgenogram showing: A, gastric mucosa of the esophageal hiatus hernia formed a "Saturn ring" around the esophageal mucosa; B, separation of esophageal folds in the central invaginated portion, indicating invagination is not merely an elongation of esophageal mucosa.

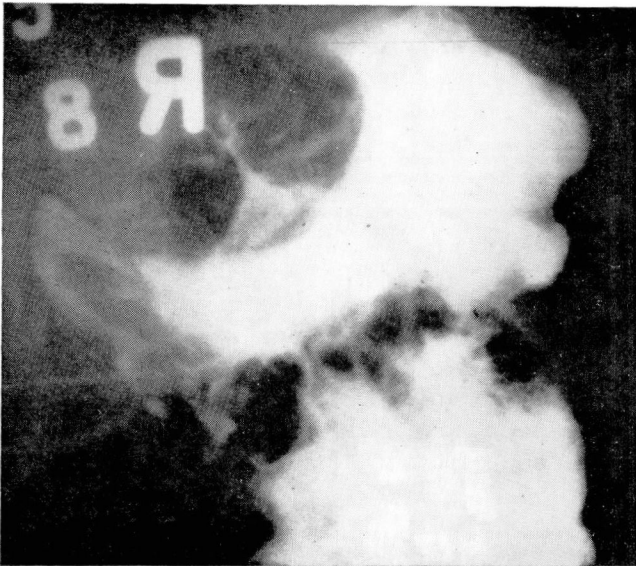


Fig. 2. Roentgenogram showing deep infolding of the stomach and narrowed distal portion of the esophagus, suggesting neoplastic invasion.

that was noted by Ödegaard.² All patients were adults, within an age range of 47 to 71 years. Eleven patients had the most common type of esophageal invagination in which the esophageal mucosa slides into a small hernia giving a typical jack-in-the-pulpit appearance (*Fig. 1A*). *Figure 1B* shows a diamond-shaped appearance of the esophageal mucosa in the invaginated portion. This appearance would not be expected if only esophageal mucosa invaginated, and suggests that at the same time that the esophageal mucosa moved caudally, the herniated portion of the stomach moved cephalad, causing some localized buckling or pleating of the esophageal mucosa.

A second and rare type of invagination is shown in *Figure 2*. The esophageal mucosa traversed the hiatus and invaginated into the cardia of the stomach below the diaphragm for a considerable distance. This appearance may closely resemble a stricture or neoplasm involving the esophagus and the cardia of the stomach. However, the deep infolding of the proximal portion of the stomach is not a constant finding, and the mucosal pattern is intact both in the esophagus and the stomach. Clinically, the two patients showing this radiographic finding were asymptomatic.

SUMMARY

The variable roentgenographic appearance of invagination of the esophagus into the herniated or subdiaphragmatic portion of the stomach in 13 patients is discussed. A possible explanation for the roentgenographic appearance is offered. In this series, most of the patients were women in their fifth decade of life, with small asymptomatic hiatus hernias, and invagination could be demonstrated only when they were in the prone position.

REFERENCES

1. Klinefelter, E. W.: Invagination of the esophagus in hiatus hernia. *Radiology* **67**: 562-568, 1956.
2. Ödegaard, H.: Invagination of the esophagus in hiatus hernia; a report of 8 cases. *Acta radiol.* **51**: 443-448, 1959.