

CONDYLAR FRACTURES OF THE HUMERUS

JAMES A. DICKSON, M. D.

AND

CLIFFORD L. GRAVES, M. D.

Most fractures of the lower humerus can be classified into three main groups: the supracondylar, the condylar, and the epicondylar (Fig. 1); other varieties such as the diacondylar and the T or Y fractures are much less common. Only condylar fractures* will be discussed here because their treatment involves several peculiar problems which are not always handled to the best advantage of the patient. To understand these problems one must have a clear conception of the

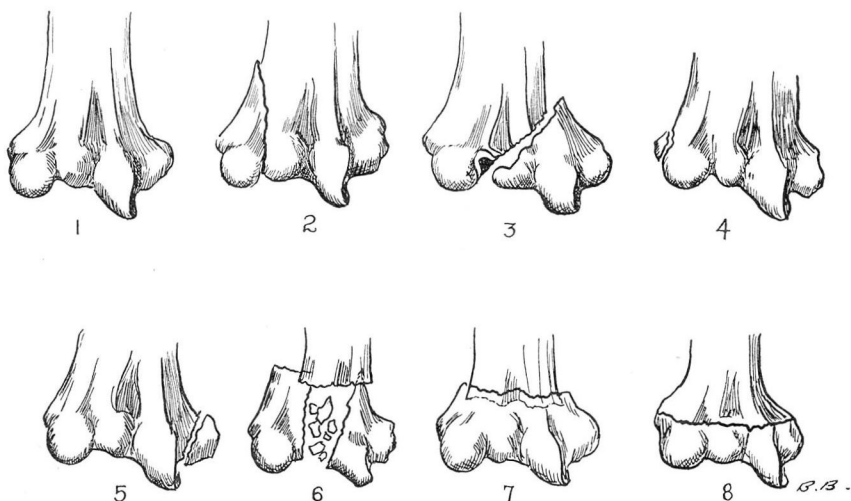


FIGURE 1: Schematic representation of various fractures of the lower humerus. 1. Normal contour. 2. Fracture of the external condyle. 3. Fracture of the internal condyle. 4. Fracture of the external epicondyle. 5. Fracture of the internal epicondyle. 6. Intercondyloid or T fracture. 7. Supracondylar fracture. 8. Diacondylar fracture. (After Wilson and Cochran, *Fractures and Dislocations*).

difference between a supracondylar and a condylar fracture and the anatomy and epiphyseal development of the lower humerus.

In the usual supracondylar fracture, the lower fragment is pulled up and back by the triceps muscle, but it is not tilted significantly because the attached muscles (the flexors to the internal condyle and the extensors to the external condyle) pull evenly and symmetrically. Consequently, by manipulating the forearm one can gain satisfactory control over the fragment, disengage it, and accomplish reduction by a fairly simple, well-standardized maneuver.

*In this paper epicondylar fractures are included in the term condylar fractures.

An entirely different situation exists when a single condyle is broken. Such a condyle forms a small triangular fragment to which is attached a single set of powerful muscles which produce a displacement that is in many cases characteristic. The condyle is not only pulled down but also twisted on itself so that its fractured surface faces outward instead of inward. This is not always apparent on casual inspection of the roentgenogram, but careful "three-dimensional" reconstruction will reveal it with great regularity (Figs. 4,C and 5,C). From a study of figures 4,A and 5,A, it is obvious that any manipulation of the forearm under such circumstances only increases the malposition, and even if one could push the fragment back toward the humerus it would still be impossible to correct the rotation that has occurred. When the fragment has been displaced in this manner, *proper reduction can be accomplished only by open operation.*

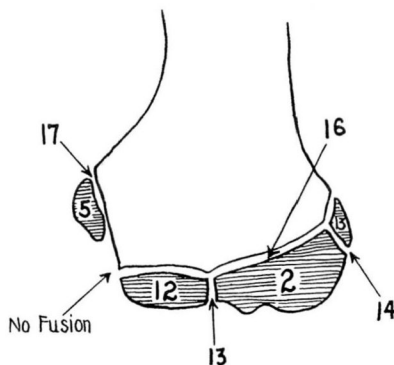


FIGURE 2: Diagram of epiphyses of lower humerus at the end of the growth period. Front view, left humerus. The figures in the shaded epiphyses indicate the average time of appearance; the figures attached to arrows indicate the average time of fusion. "No fusion" indicates that the epiphyses here do not fuse with each other, but join the shaft independently. (After Baumann, Beitr. z. klin. Chir., 146:1, 1929).

This difference between supracondylar and condylar fractures becomes still more important when the development of the elbow is considered. Since these fractures occur much more commonly in children, they affect growing epiphyses that are very sensitive to injury.

In the supracondylar fracture, all the epiphyses are detached *en masse* and do not suffer any relative change in position. If a subsequent retardation of growth should occur (which would be unusual) all the epiphyses would share equally in the process. If the forearm is properly aligned at the time of reduction, there is no reason to fear subsequent deformity, and the clinical results bear out this statement.

On the other hand, if the displaced single condyle is not accurately reduced, a most unfortunate chain of events ensues. The condyle in its vicious position cannot unite; it therefore deprives one-half the articular surface of the humerus of normal growth, with the result that the uninjured, expanding epiphysis gradually pushes the elbow into a varus or valgus position. Anyone who has followed a patient with such an elbow and seen the deformity progress from bad to worse will agree that nothing but an immediate, open reduction suffices. The operation should be done through a generous incision giving free access to the

CONDYLAR FRACTURES OF THE HUMERUS

fractured condyle. Even with thorough exposure one may have difficulty in maneuvering the fragment into place. The procedure may be compared to the fitting together of a jigsaw puzzle or to an intricate bit of cabinetmaking. The point we wish to make is that condylar fractures with gross displacement are major surgical problems whose solution should not be undertaken without due respect for the difficulties involved.

Anatomy: The lower third of the humeral shaft is considerably broadened and flattened and curved slightly forward. The supracondylar ridges, which are the thin lateral borders, flare out sharply below to form the condyles. Each ridge terminates in a small projecting knob, the epicondyle. The internal one which is much the more prominent of the two gives attachment to the pronator teres and to a common tendon of origin of some of the flexor muscles of the forearm. The external condyle gives attachment to the supinator and to a common tendon of origin of some of the extensor muscles of the forearm. The articular surface consists of two parts of unequal size, separated by a median ridge. The larger and internal one is the trochlea and articulates with the sigmoid cavity of the ulna. The smaller and external one, nearly spherical, is the capitellum and articulates with the head of the radius. Above the trochlea on the posterior surface is the large olecranon fossa which receives the tip of the olecranon process when the elbow is completely extended. The humero-ulnar articulation is a pure hinge joint which permits only flexion and extension; the humeroradial articulation is a gliding joint which allows the radius to accompany the ulna in flexion and extension; the superior radio-ulnar articulation is a swivel joint which is responsible for the rotary motions of the head of the radius. These three articulations have a single capsule and together form the elbow joint.

At birth, the lower end of the humerus is cartilaginous. Ossification takes place from four separate centers: the capitellum, the internal epicondyle, the trochlea, and, occasionally, the external epicondyle. There is considerable variation in the ages at which these centers first become visible roentgenographically; therefore, the following figures are only approximate: At the end of the second year, ossification begins in the capitellum and extends medially to form the chief part of the articular end of the bone; the center for the medial part (trochlea) appears about the age of twelve. Ossification begins in the internal epicondyle about the fifth year and in the external epicondyle about the thirteenth year. The capitellar and trochlear centers unite at about the thirteenth year, and the external epicondyle joins them soon afterward. These three epiphyses, in one mass, then fuse with the shaft at about sixteen years, but the medial epicondyle usually remains separate for at least another year. (Fig. 2.)

Roentgen Examination: Since the lower humerus has four separate epiphyses, every one with its own wide range of normal variations, the appearance of the roentgenogram may be very misleading. Epiphyses may easily be mistaken for fragments and epiphyseal lines for fracture lines. Moreover, if the roentgenograms are not taken in *exactly* anteroposterior and lateral directions, much distortion occurs in the films. This causes still more confusion of the shadows. *We therefore always make control observations on the sound side.* With roentgenograms made in this manner, certain constant relationships between the epiphyseal centers and the humeral shaft can be observed, and any gross alterations determined with the aid of the following lines and measurements:

1. In the lateral view, with the elbow flexed to a right angle, a line passed along the long axis of the shaft midway between its anterior and posterior borders passes behind the posterior border of the capitellum in children up to the age of about nine, and the line of the anterior limit of the shaft has at least one-half the capitellum in front of it (Fig. 3, A). After the age of nine, the capitellum gradually recedes and the line bisecting the shaft has approximately two-thirds of the capitellum anterior to it (Fig. 3, B).

2. A line at right angles to the base of the capitellum and bisecting it, forms an angle of about 130 degrees with the line of the long axis of the shaft (Fig. 3, C).

3. When the forearm is extended and fully supinated, the long axis of the humerus forms an angle of about 170 degrees with the long axis of the ulna (carrying angle) (Fig. 3, D).

4. The epiphysis of the internal condyle is in close proximity to the internal oblique line of the shaft (Fig. 3, E).

5. In the anteroposterior view, a line connecting the two epicondylar epiphyses (epicondylar line) is at right angles to the longitudinal axis of the shaft and is approximately bisected by it (Fig. 3, F). Since the external epicondyle does not show before the thirteenth year, a condylar line may be used instead of the epicondylar line, the condylar line connecting the points where condyles and epicondyles merge.

Incidence: Figure 1 indicates the nomenclature used with fractures of the lower end of the humerus and is self-explanatory. As has been said, most of the fractures of the lower humerus occur during the growth period, that is, in the first and second decades, especially the first. The reason is that the humerus is a much weaker structure in the child than in the adult in whom dislocation of the elbow is more likely to occur. The left elbow is fractured more commonly than the right, probably because the left arm is used for protection while the right hand holds

CONDYLAR FRACTURES OF THE HUMERUS

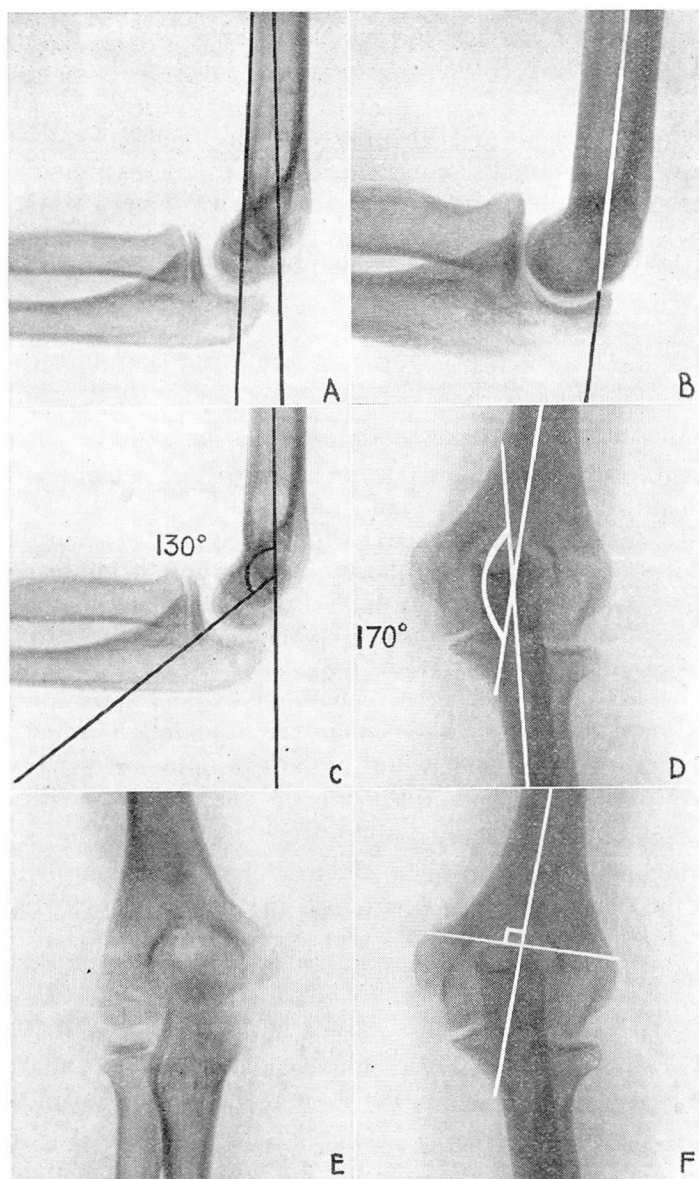


FIGURE 3: Lines and angles of normal elbow. See text.

on to objects. As would be expected, boys outnumber girls in most of the reported series.

The proportion of supracondylar to condylar fractures varies somewhat, but generally the former are the more common. Of the condyles, the external one is fractured more frequently than the internal. In the

epicondyles, this relationship is reversed, fracture of the external epicondyle being quite rare.

Signs: Invariably a great deal of swelling occurs about the joint which makes it difficult to distinguish the bony landmarks. Normally, the two epicondyles and the tip of the olecranon process are on a straight line when the elbow is extended, and form an isosceles triangle when the elbow is flexed. This relationship is disturbed in condylar fractures. There will also be abnormal lateral mobility of the forearm and crepitus. Movements of pronation and supination are painful, depending on which condyle is fractured. For an exact diagnosis, roentgenograms are indispensable so that it is not necessary to subject the patient to an exhaustive and painful clinical examination.

Treatment: The importance of accurate reduction has already been emphasized. Not all condylar fractures require an open operation, however. To outline the operative indications and evaluate the end results, it is helpful to divide these fractures into three classes according to the displacement that occurs: (1) those in which there is no displacement, (2) those in which there is only lateral displacement without rotation, and (3) those in which there is severe displacement with rotation. These three types occur with about equal frequency. It is the last group which is responsible for unsightly, disabled elbows and has provided the incentive for the writing of this article. We include here not only the condylar fractures proper, but also those epiphyseal separations in which any part of the humerus itself, no matter how small, remains attached to the fractured capitellum or trochlea.

When a condylar fracture is of the first class, the humerus is merely fissured, the periosteum remains intact, the blood supply of the fragment is not disturbed, and the articular surface suffers no change in contour. Accordingly, these patients need no more than simple immobilization of the arm in a sling for a few weeks. After that, motion may gradually be resumed. Subsequent disability is short and the end results are perfect. The only roentgenographic evidence that remains indefinitely is a small notch on the shaft at the top of the fracture line.

When the fracture is of the second class, the fragment is displaced laterally, i.e., away from the joint but the periosteum is not completely stripped and rotation is therefore prevented. It is usually unnecessary to attempt reposition of the fragment and, in fact, it would be difficult to do so by manipulation alone. The fragment still has its blood supply, the contour of the articular surface is only slightly altered and union invariably takes place provided the arm is immobilized in flexion for a few weeks. The results are usually good although occasionally some limitation of motion persists for a long time. Subsequent changes in the roentgenogram are characteristic and can always be found if looked for.

CONDYLAR FRACTURES OF THE HUMERUS

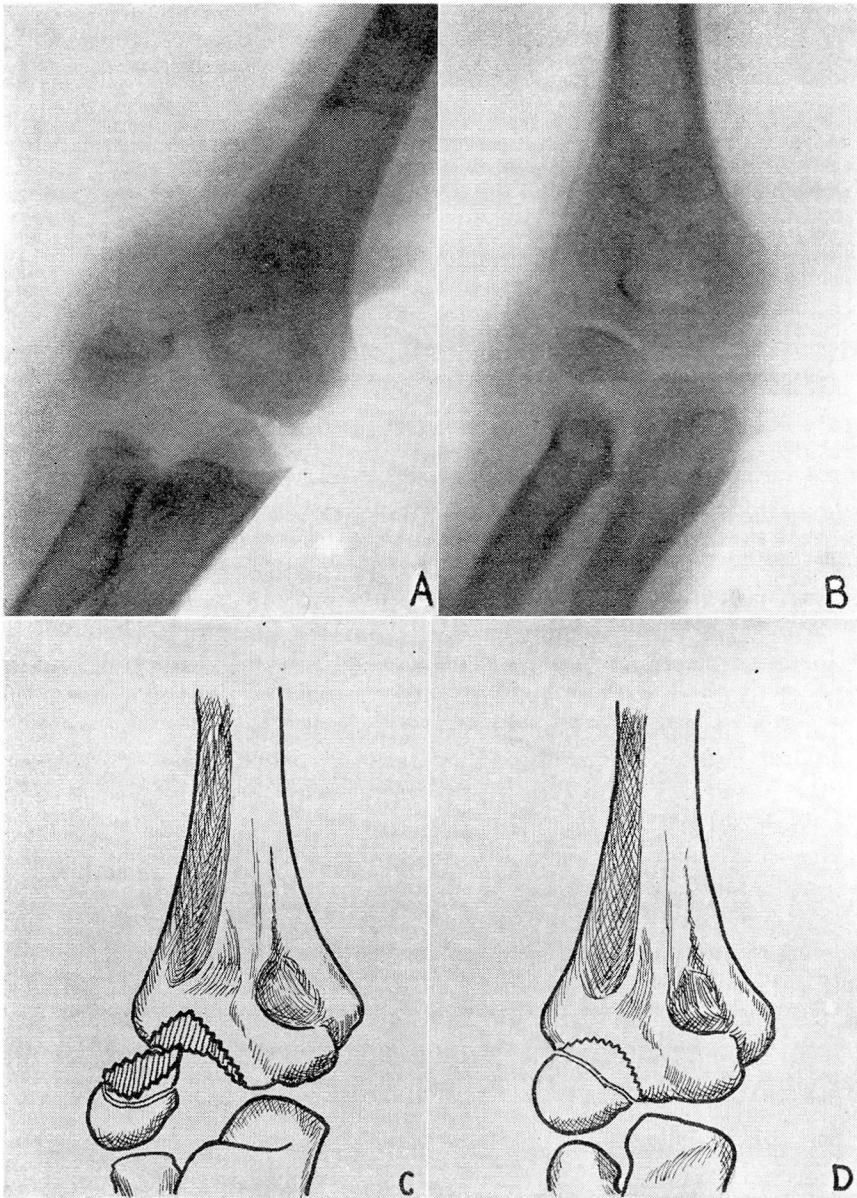


FIGURE 4: A. Fracture of the external condyle in a boy of six. B. Fracture reduced by open method. C. "Three-dimensional" reconstruction from a tracing of the roentgenogram. D. After reduction.

The displaced condyle carries its periosteum with it. This periosteum fills with bone the gap that separates the condyle from the humerus, and as a result the condyle becomes more prominent. This prominence can be felt clinically and is one of the unmistakable signs of a previous

fracture. Another interesting roentgen finding is that no regeneration of bone occurs in the joint where the fracture line separates the capitellum from the trochlea. A little notch develops at this point and this notch becomes larger as the patient grows older. It gives the lower humerus a quasi bifid appearance but does not produce any disability.

When the fracture is of the third class, the very serious displacements occur that jeopardize the integrity of the joint. All periosteal attachments are severed and the fragment is deprived of its blood supply. The exact position varies. Usually the fractured surface is turned around 180 degrees and faces outward, the joint surface looks backward, and the apex points forward. In such a position union can never occur. If allowed to remain, the fragment gradually undergoes certain degenerative changes. The diaphyseal segment atrophies, loses its normal density, and finally disappears altogether. The epiphyseal segment at first expands somewhat, its cartilage is absorbed, it assumes an irregular outline, and eventually becomes a useless and often painful foreign body with or without pseudarthrosis.

More damaging than this is the loss of the growing epiphysis. The articular surface of the humerus is reduced to approximately one-half its former size, but this half continues its normal expansion. With the loss of the external condyle, the radius, no longer having the capitellum to rest against, ascends towards the humerus, the trochlea in a compensatory overdevelopment becomes more and more oblique, and the forearm is gradually forced into a valgus deformity, sometimes as severe as 130 degrees. This prepares the soil for the development of late ulnar neuritis, not a rare complication. With the loss of the internal condyle, the same thing happens but in the opposite direction, and the end result is a cubitus varus. In all cases the elbow shows limitation of motion, particularly extension and in many it becomes painful after vigorous or prolonged use. Always it is an esthetic liability to the patient, frequently an economic one. *It can and should be prevented by suitable early treatment.* Two typical cases are presented here (Figs. 4 and 5). Careful study and consideration of figures 4,A, and 5,A show the futility of manipulation alone. Operative reduction is imperative.

In performing the operation, one should aim at adequate exposure. A longitudinal incision is made directly over the fractured condyle. If this is the internal condyle, the first task is to identify and protect the ulnar nerve which may have been damaged by the original injury. A neurological examination should therefore always be done first. Nerve damage is less apt to occur in fracture of the external condyle. When the fracture line extends quite high on the humeral shaft, however, it is well to isolate the radial nerve before proceeding with the reduction.

CONDYLAR FRACTURES OF THE HUMERUS

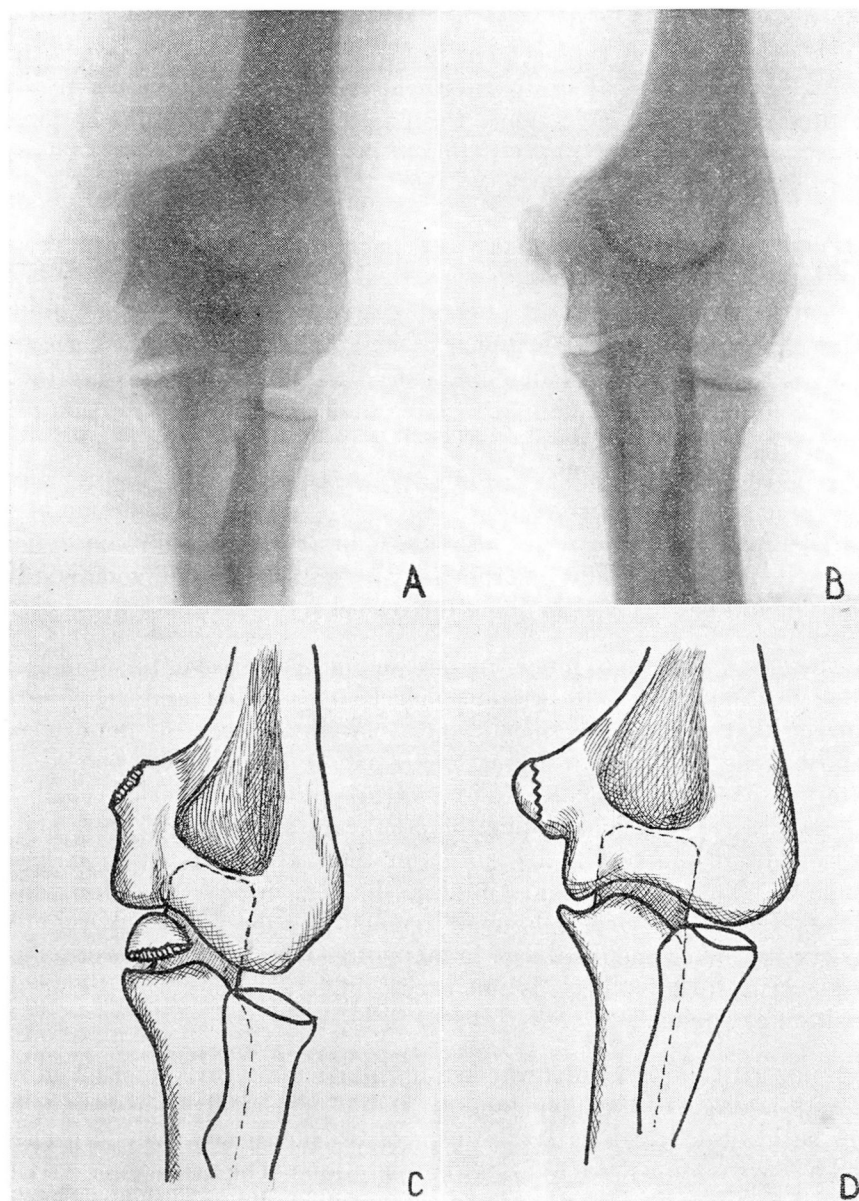


FIGURE 5: A. Fracture of the internal epicondyle in a girl of ten. Note that the epicondylar fragment has been caught in the joint space. There was evidence of slight ulnar palsy which was completely relieved following operation. B. Fracture reduced by open method. C. "Three-dimensional" reconstruction from a tracing of the roentgenogram. D. After reduction.

The fragment is then exposed in front of the joint. It is always larger than the roentgenogram would lead one to believe because it consists for a large part of cartilage. The actual reposition may be a difficult task.

The operative field is necessarily limited and the fragment often so much displaced that replacement is far from easy. Anyone who has struggled with a recalcitrant fragment will realize the utter futility of attempts at closed reduction. Even under direct vision, the obstacles are manifold and the slightest motion of the forearm will cause a change in the position of the fragment.

The type of fixation material will depend on the surgeon's preference. Autogeneous bone pegs, rustless wire, steel bands, and flanged nails have been used, every one with its advantages and disadvantages. Without entering the controversy whether it is the epiphyseal malposition *per se* or a subsequent trophic change that causes the interference with growth, we are emphatic in stating that we are opposed to the introduction of a foreign body across an epiphyseal disk if it can be prevented. For that reason, wherever possible, we now use in children only heavy catgut sutures to maintain our reduction. These are quite sufficient to maintain the position in the majority of instances. In adults the objection to pegs and nails is less strenuous and they may be resorted to with good results. They should be removed in about three weeks.

The elbow is put into moderate flexion and the forearm in supination. This position utilizes the triceps muscle as a splint and relaxes the muscles that produce the displacement. With fractures of the external condyle, the position of supination relaxes the supinator, one of the external condyle muscles. With fractures of the internal condyle, theoretically, one should put the forearm in pronation, but this is awkward and the results are no better than when supination is used. Some German authors suggest putting the arm in near-extension which makes it easier to correct the malalignment but the fractured fragment is very apt to become displaced in this position and if the reposition has been accurate, this check is not necessary. We therefore prefer the position of flexion.

Since all condylar fractures are intra-articular, early motion is important and one of the advantages of stable internal fixation is that this can be instituted with safety. In uncomplicated cases, we start active and passive motion three weeks after operation. The arm can be carried in a sling after this time. Massage is contraindicated because of the great tendency of the bones about the elbow joint to form excessive callus. This complication as well as signs of traumatic neuritis should be carefully watched for. Quite a long time is required before a complete range of motion is restored and this is true even of children in whom joint motion is ordinarily very quick to return. Some limitation of extension is apt to persist for many months, but eventually, with the coöperation of the patient, an excellent result can be obtained.

CONDYLAR FRACTURES OF THE HUMERUS

The problem of what to do with an old condylar fracture that has progressed to nonunion is not an easy one. If the deformity is only mild and joint function fairly adequate though not perfect, it is better not to interfere because delayed reductions do not have the good prognosis of immediate reductions. When the deformity is great, the pain severe, and the motion much limited, a secondary open reduction may be done but the result will be only fair. Sometimes a cuneiform osteotomy of the humerus suffices to improve the appearance. Removal of the loose condyle should be avoided because it leaves the joint more unstable and increases the existing deformity. For this reason, if the removal seems absolutely indicated, it should always be combined with anterior transplantation of the ulnar nerve. Late ulnar neuritis, the result of gradual stretching of the nerve, also calls for anterior transplantation.

SUMMARY

The anatomical and clinical features of fractures of the humeral condyles are briefly discussed. Attention is called to the undesirable sequelae of imperfect reduction. Early recognition and open operative reduction are urged in condylar fractures with significant displacement.