

## PANTOPAQUE "ARACHNOIDITIS"

Treatment With Subarachnoid Injections of Corticosteroids\*

ARJUN D. SEHGAL, M.D.,† W. JAMES GARDNER, M.D.,

and

DONALD F. DOHN, M.D.

*Department of Neurological Surgery*

**P**ERSISTENCE or recurrence of sciatica following disc surgery is not uncommon and is due to a number of factors. Among these are the fact that removal of the protruded portion of the disc may not restore the joint to normal. Secondly, relief of pressure on the nerve root does not restore the nerve root to normal. Thirdly, surgical exposure of any spinal nerve root, normal or abnormal, causes it to become immobilized in the healing scar. A nerve root so immobilized is still pulled upon by certain movements whether or not the involved joint is fused. Fourthly, the diagnosis and surgical treatment of these lesions affecting the central nervous system are fraught with pitfalls even in the hands of experienced neurosurgeons.

Faced with the problem of trying to help such patients, and realizing that reoperation is seldom successful, we began to employ intraspinal injections of procaine hydrochloride‡ and corticosteroids.<sup>1</sup> The injections were followed by straight-leg raising exercises designed to stretch the adhesions about the nerve roots. In many patients the procaine was necessary because mobilization of the nerve root by these exercises was painful. In the beginning, these injections were given extradurally through the sacral hiatus.<sup>2</sup> Later, in some of the patients who failed to respond, injections were given intradurally by spinal puncture, and relief was afforded. Gradually it was realized that when the patients had had a previous Pantopaque myelogram, the intradural treatment was apt to be more effective than the extradural.

The introduction of Pantopaque§ in 1940 facilitated the performance of myelography because the low viscosity of the contrast medium made its gross aspiration from the subarachnoid space relatively easy.<sup>3</sup> In this country and in England it was considered rather innocuous. In Scandinavia it was not so eagerly accepted, and the more complicated Abrodill|| technic has been preferred because the water-soluble salt quickly disappears from the subarachnoid space. Although most of the Pantopaque is easily removed from the lumbar theca, droplets always remain, though they may be too small to be shown radiographically. The fact that there is residual contrast medium has disturbed several investigators, inasmuch as sub-

\*From a paper by Doctor Sehgal, which was awarded second place in the Surgical Residents Essay Contest, May, 1962, by the Cleveland Surgical Association.

†Fellow in the Department of Neurological Surgery.

‡Novocain, Winthrop Laboratories.

§Mixture of ethyl esters of isomeric iodophenylundecylicacids distributed by Picker X-Ray Corporation.

||Kontrast 'U', Aktiebolaget Leo Hälsingborg.

sequent meningeal irritation has been reported,<sup>4-9</sup> including severe adhesive arachnoiditis that obliterated the spinal subarachnoid space.<sup>6</sup> These severe reactions were recognized upon investigation of pain syndromes following myelography, whether operations were or were not performed upon intervertebral discs. Less severe and less lasting pain syndromes have followed myelography and have aroused little comment. Chronic arachnoiditis, however, has been described.<sup>4-6</sup> Cases illustrating various reactions to Pantopaque follow.

**Case 1. Chronic arachnoiditis.** A 66-year-old man was examined in March, 1961, because of low back and bilateral sciatic pain. In 1944 he had undergone Pantopaque myelography for investigation of pain in the neck and left arm. The result of this study is not known, but operation was not performed. Subsequently, intermittent pain low in the back and in both legs developed and became worse a few months before our examination. A Pantopaque myelogram disclosed almost complete obstruction of the spinal subarachnoid space opposite the fourth lumbar intervertebral disc (Fig. 1). A wide lumbar laminectomy disclosed no extradural lesion.

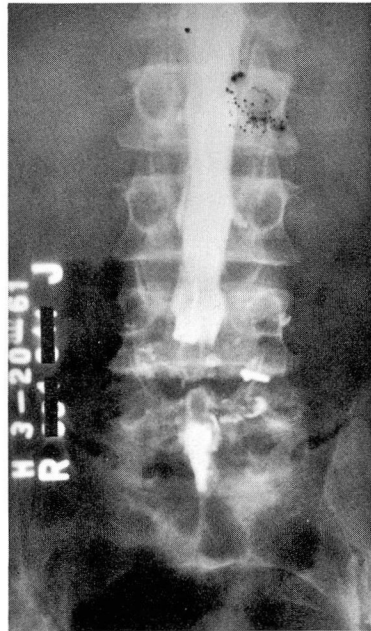

Fig. 1. Case 1. Myelogram showing lumbosacral defect produced by Pantopaque arachnoiditis.

The dura was opened, disclosing a thick, opaque, adherent arachnoid; a histologic preparation is shown in Figure 2.

**Comment.** Several writers have described arachnoiditis caused by Pantopaque and other iodized oils. This reaction increases in intensity with the wide dispersion of minute droplets, especially when blood is present in the cerebrospinal fluid.

**Case 2. Acute meningeal reaction.** A 26-year-old man was examined in May, 1960, because of numbness on the anterior surface of the left thigh. A myelogram was done on May 18, 1960, using 8 ml. of Pantopaque. The findings were normal; 7 ml. of the material was removed. The

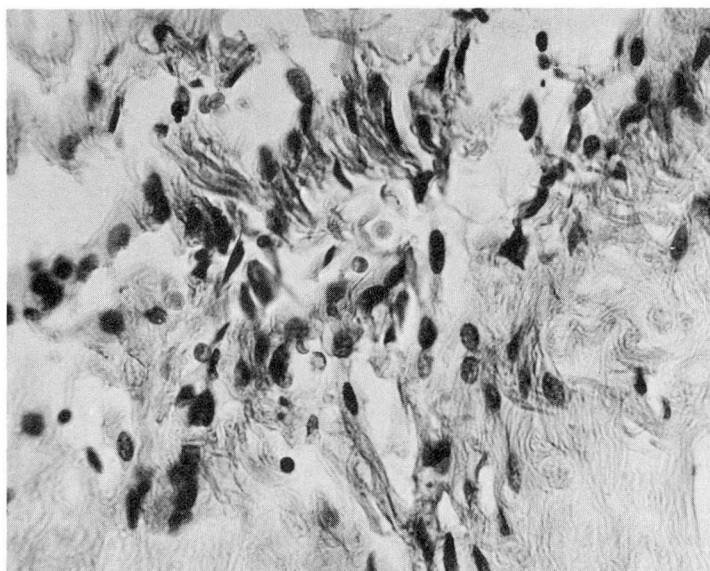


Fig. 2. Case 1. Photomicrograph of arachnoid tissue obtained at operation, showing fibroplasia and lymphocytic reaction. Hematoxylin-eosin-methylene blue stain; magnification X 450.

spinal fluid contained one leukocyte and 42 mg. of protein per 100 ml., and Pandy's reaction was negative. During the night pain developed in the lower back and both hips, sites that had never before been uncomfortable. In the morning the pain was severe and radiated to both hips and the backs of the thighs. An acute meningeal reaction was suspected, and a lumbar puncture was repeated. The spinal fluid contained 309 leukocytes, of which 87 per cent were polymorphonuclear, 6 per cent monocytes, and 7 per cent lymphocytes. Spinal fluid protein content was 48 mg. per 100 ml.

**Case 3. Acute lumbar meningeal reaction following cisternal injection.** A 48-year-old woman was examined in August, 1961, because of painless symptoms suggesting a spinal cord lesion. A specimen of spinal fluid contained two leukocytes and 33 mg. of protein per 100 ml. A few days later a myelogram was made. The Pantopaque was injected into the cisterna magna, to avoid misplacement of the contrast material because of the recent lumbar puncture. The myelogram was normal; Pantopaque was removed by lumbar puncture. Within 12 hours a stiff neck and severe pain in the lower back and legs developed. Spinal fluid study disclosed 116 leukocytes, 90 per cent polymorphonuclear, 10 per cent lymphocytes, and 33 mg. of protein per 100 ml.

**Case 4. Acute reaction subsiding to a chronic stage.** In December, 1959, a 43-year-old woman, with pain in the neck and the right shoulder, underwent Pantopaque myelography at another hospital. Immediately, sharp pain developed in the lower back and both legs so severely that the contrast material could not be removed; the cervical symptoms were completely overshadowed and both legs became "partially paralyzed."

Six months later we examined her because of persistent low back and leg pain. Lumbar puncture revealed normal dynamics. The fluid contained five leukocytes and 43 mg. of protein per 100 ml.

## Corticosteroid Therapy

In 1950, Dougherty and Schneebeil<sup>10</sup> presented evidence suggesting that cortisone reduced tissue reaction to inflammation. Humphrey<sup>11</sup> found that cortisone minimized experimental hypersensitivity reactions. In 1953, Oppenheimer and Reister<sup>12</sup> showed that cortisone diminished the leptomeningeal reaction to foreign bodies, such as talc. The development of foreign-body granuloma was inhibited by this steroid in a number of experimental animals<sup>13-19</sup> and, in tissue culture, the development of fibroblasts was inhibited.

Encouraged by these properties of the steroids, we employed epidural injections of corticosteroids and procaine hydrochloride to relieve sciatica presumed to be caused by epidural nerve root adhesions.<sup>2</sup> Spinal fluid analyses, after epidural injections of corticosteroids, have shown that none of the drug gains access to the subarachnoid space.

Animal experiments have suggested that adrenal corticosteroids can be introduced safely into the subarachnoid space.<sup>12-14,18,19</sup> Pieper and Fields,<sup>20</sup> and Choremis, Papadatos, Gargoulas, and Drosos<sup>21</sup> showed that intrathecal administration produced no harmful local or systemic effects. In 1960, Sehgal and Gardner<sup>1</sup> reported that the subarachnoid injection of adrenal corticosteroids was followed by the relief of sciatica of suspected intrathecal origin.

## Material and Technic

*Material.* This report concerns 100 patients having persistent sciatica, who had undergone Pantopaque myelography, all of whom were treated by subarachnoid injection of corticosteroid suspensions. In most instances myelography and surgery had been performed before the patients were examined by us, and the specific details of these procedures are not known.

Sixty-three of the patients were men and 37 were women, ranging in age from 24 to 74 years. Exacerbation of pain occurred after the first myelogram in each of 35 patients, and after a second myelogram in each of 15, suggesting acute irritative reactions to Pantopaque. In 17 patients the sciatica developed *after* myelography performed for suspected lesions at the cervical or thoracic levels. In three of these, arachnoid adhesions were disclosed at primary lumbar laminectomy performed some weeks after the cervical myelography. Adhesive arachnoiditis was disclosed also at a second lumbar laminectomy in 14 of the remaining 83 patients in whom a preoperative myelogram could have caused or could have contributed to this operative finding.

By coincidence, in these 100 patients, a total of 143 Pantopaque myelograms and 143 laminectomies were performed before the treatment by subarachnoid injection of corticosteroid suspensions. We carried out an additional 27 lumbar discograms and 14 Abrodil myelograms to establish the presence or absence of other causes. In 50 of the 100 patients a total of 191 caudal epidural injections of procaine



hydrochloride and hydrocortisone were administered, with temporary or no relief. Twelve patients received corticosteroids orally, without relief.

Several preparations of corticosteroids were used intrathecally early in the series, and methylprednisolone acetate\* suspension was found to be the least irritating, the most beneficial, and the longest acting. Immediate reactions followed administration of other corticosteroid preparations in 11 patients. These reactions, consisting of severe painful spasm of lower back and leg muscles, lasted for from two to four hours and seemed to be due to corticosteroid solvents; they have not occurred since the use of methylprednisolone acetate in suspension. We consider the intrathecal injection of soluble corticosteroids inadvisable because of their irritative effects.<sup>1</sup>

*Technic.* A lumbar puncture was performed with the patient on his side, and a sample of spinal fluid was taken for analysis. Two milliliters of a suspension of methylprednisolone acetate (40 mg. per milliliter) was injected. In those patients in whom straight-leg leverage was found to be painful, a solution of 50 mg. of procaine hydrochloride crystals in from 3 to 4 ml. of cerebrospinal fluid was injected also. The patient then was turned on his back. Passive straight-leg raising exercises were carried out for 15 minutes in an effort to stretch or to loosen possible nerve root adhesions (*Fig. 3A and B*).

In some patients, when relief of pain was only partial or temporary, the injection was repeated after one or two weeks. The 100 patients received 172 subarachnoid injections, 23 of which were combined with spinal anesthesia. When spinal anesthesia was used, the patient rested for four hours and then was allowed to go home. He was advised to be physically active and to discontinue the use of back supports and medication.

In some patients in this series subsequent spinal fluid samples were withdrawn for analysis and for determination of the rate of absorption of the corticosteroid from the subarachnoid space. These data comprise a separate study.

### Therapeutic Response in Seven Illustrative Cases


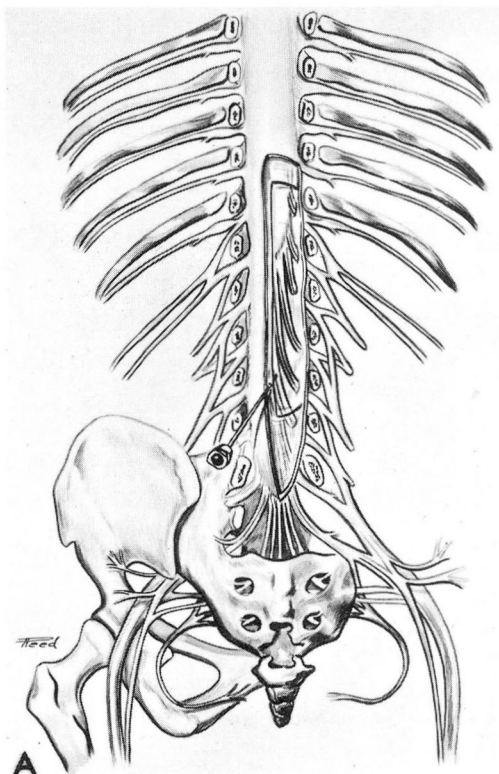
**Case 1.** (See prior note.) Following the explorative procedure and the arachnoid biopsy, the dura was left open and the nerve roots were covered with Gelfoam soaked in a suspension of methylprednisolone acetate. The patient's pain diminished but remained. On the third postoperative day, 2 ml. of methylprednisolone acetate was injected intrathecally. By the seventh postoperative day the patient was asymptomatic; the pain had not recurred when he was examined four months later.

*Comment.* In this patient sciatica developed after Pantopaque myelography performed because of pain in the neck and the left arm. Arachnoiditis in the lumbosacral area was found at operation 15 years later, and the sciatica was relieved by the local application and subsequent subarachnoid injection of methylprednisolone acetate.

**Case 2.** (See prior note.) At the time of the lumbar puncture, 2 ml. of methylprednisolone

\*Depo-Medrol, supplied through the courtesy of The Upjohn Company, 301 Henrietta Street, Kalamazoo 99, Michigan.

Fig. 3. A, Sketch showing placement of the needle in the subarachnoid space so that the therapeutic agent may follow the naked nerve roots into their dural sleeves. (Reproduced from Reference 2.) B, Straight-leg raising combined with jugular compression to stretch subarachnoid adhesions and to encourage further dissemination of the therapeutic agent. Blood pressure cuff about the neck was inflated to 40 mm. of Hg in order to distend the nerve root sleeves. (Reproduced from Reference 2.)



acetate was injected intrathecally. The pain was entirely relieved within a few hours and has not recurred within a year of observation.

**Case 3.** (See prior note.) At the time of lumbar puncture, 1 ml. of methylprednisolone acetate was injected intrathecally. Pain subsided completely within 24 hours and the patient was asymptomatic; she was pain-free at the time of examination two months later.

*Comment.* Cases 2 and 3 demonstrate the beneficial result of the intrathecal administration of methylprednisolone acetate in the treatment of acute Pantopaque meningeal reaction. Our experience suggests that untreated this acute reaction is liable to be followed by the development of chronic arachnoiditis. Thus the early use of intrathecal methylprednisolone acetate in such cases may be prophylactic. Of the 100 cases, 10 were in this prophylactic category.

**Case 4.** (See prior note.) At the time of the lumbar puncture, 2.5 ml. of methylprednisolone acetate suspension was injected intrathecally, with 50 mg. of dissolved procaine hydrochloride crystals to facilitate passive straight-leg raising. That night the pain was worse; the next day it was about 50 per cent improved, and within three days it was gone. Eleven months later the patient still had her original complaint of neck and arm pain but the postmyelographic pain in the lower back and legs had not recurred.

**Case 5.** A 34-year-old woman was examined in March, 1961, because of pain, in the neck and the right arm, of 12 years' duration. A cervical disc protrusion was suspected. Pantopaque myelography was performed. A surgical lesion was not demonstrated, and physiotherapy was advised. Within a week pain developed in the low back and left sciatic nerve distribution; this became progressively more severe. During examination on June 20, 1961, jugular compression reproduced the pain. A diagnosis of lumbosacral Pantopaque arachnoiditis was made, and 2 ml. of methylprednisolone acetate was injected by lumbar puncture. Within 36 hours of the injection the back and leg pains were relieved completely, and jugular compression no longer caused pain. When examined in July, 1961, the patient still had pain in the neck but none in the back or the leg.

*Comment.* In these two patients, cases 4 and 5, low back and sciatic pain started after cervical myelography and persisted for many months. Pain was relieved after intrathecal injection of methylprednisolone acetate.

**Case 6.** A 39-year-old woman was examined in January, 1960, because of pain in the neck and the left arm. Cervical myelography performed on February 29, 1960, showed a defect between the left sixth and seventh vertebrae (*Fig. 4 and 5*). Most of the Pantopaque was removed from the spinal canal. On the following day cervical laminectomy was performed and a disc protrusion was removed. The patient was discharged from the hospital free of symptoms. On April 14, 1960, she was examined because of stiffness and pain in the low back and the left leg, for which conservative treatment was advised; the symptoms worsened. Three caudal epidural injections of procaine hydrochloride and hydrocortisone were given without relief. Pantopaque arachnoiditis was suspected, and on May 16, 1960, 2 ml. of methylprednisolone acetate was given by lumbar puncture. The patient improved definitely, and three days later the subarachnoid injection was repeated. The patient was discharged from the hospital free of symptoms. On January 6, 1961, she was reexamined because of pain that recurred three weeks earlier, in the left leg. Subarachnoid injection of methylprednisolone acetate was administered again. Relief was not complete, and because the sciatica was unilateral, a lumbar disc protrusion was suspected. A discogram (*Fig. 6A and B*) was normal. A fourth intrathecal injection of methylprednisolone acetate was given on January 18, 1961; three days later the patient became pain-free and remained so. In June, 1962, she was asymptomatic and was working full time.

*Comment.* The onset of sciatica occurred after cervical myelography, at which time the routine lumbar roentgenogram demonstrated a normal lumbar sac. The possibility of a protruded lumbar disc was further excluded by a subsequent discogram. Pain was not relieved by epidural injection of hydrocortisone, but later was relieved after the intrathecal injection of methyl-

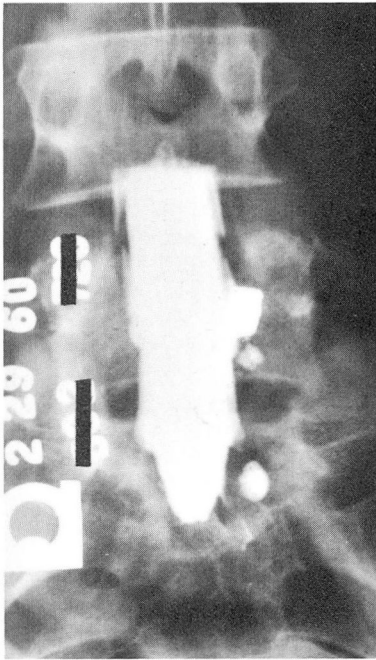


Fig. 4. Case 6. Myelogram of normal lumbosacral spine.

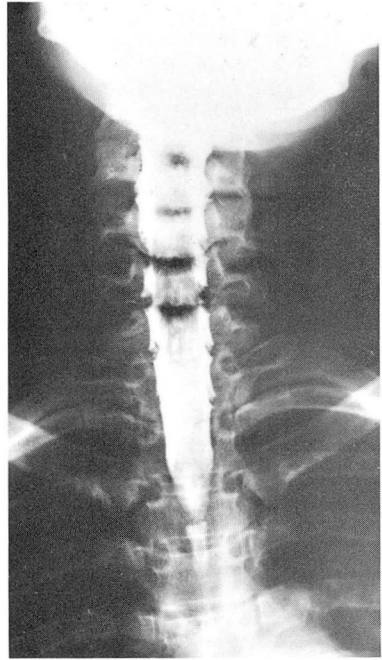


Fig. 5. Case 6. Cervical myelogram showing defects between the left sixth and seventh cervical vertebrae.

prednisolone acetate. The response in this case supports the diagnosis of Pantopaque arachnoiditis, and demonstrates the value of repeated subarachnoid injection of steroids.

**Case 7.** A 44-year-old man had back pain radiating to the left leg after an automobile accident in December, 1952. In May, 1953, Pantopaque myelography was performed in another hospital, and a protrusion of the fifth lumbar intervertebral disc was removed. Pain in the left leg was relieved. In June, 1957, after another accident in which the neck was injured, low back pain recurred. In August, 1958, Pantopaque myelography again was performed and immediately the patient had a severe exacerbation of low back pain with projection to both legs. When first seen in April, 1959, the pain was sharp, shooting, severe, and constant. He was given three caudal epidural injections of hydrocortisone and procaine hydrochloride, physical therapy, and a mid-lumbar epidural injection of hydrocortisone and procaine hydrochloride, with no relief. Hydrocortisone taken orally for two weeks afforded no significant relief. On September 8, 1959, the original 1953 myelogram was reviewed, and evidence of an intradural lesion at the level of the third lumbar vertebra was found. The next day a lumbar laminectomy disclosed greatly thickened arachnoid, and a small neurofibroma attached to the third lumbar nerve root. The tumor was removed, as was some of the thickened arachnoid. Hydrocortisone was applied locally. Recovery was uneventful, but after a few days low back and leg pain recurred. The patient was given another course of caudal epidural injections of hydrocortisone without relief. On September 17, 1959, an intrathecal injection of hydrocortisone was given. The relief of pain was dramatic and 22 months later the patient was still pain-free.

*Comment.* This patient had two concurrent lesions, the neurofibroma and the arachnoiditis.



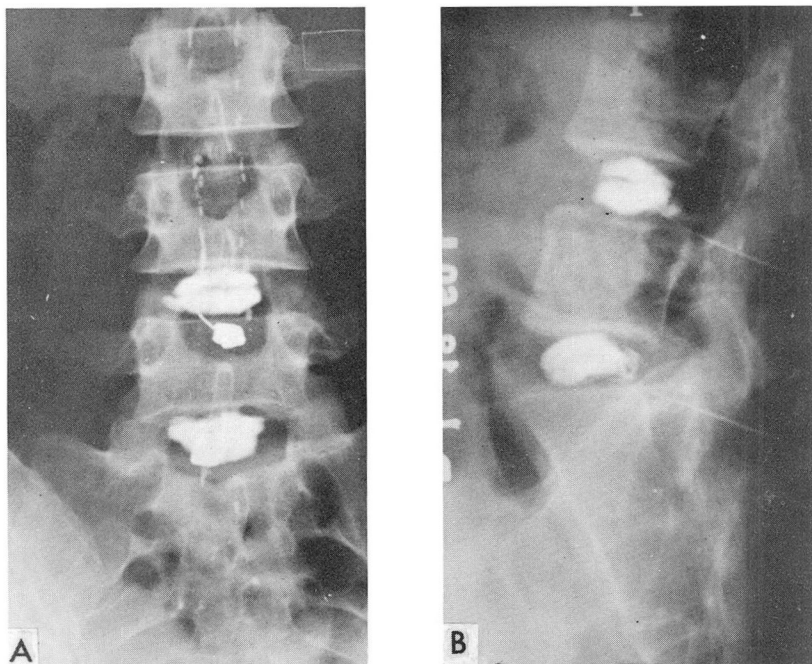


Fig. 6. Case 6. Discograms of: A, anteroposterior view, and B, lateral view of a normal lumbosacral spine.

Pain was aggravated by a second myelogram, and persisted despite the removal of the neurofibroma, but ended abruptly after the intrathecal injection of hydrocortisone.

### Results

In 60 of 100 patients in whom back and leg pain developed or persisted after Pantopaque myelography the syndrome was significantly relieved for periods up to 24 months by the intrathecal injections of corticosteroids. Good results were obtained in 15 of 16 patients whose pain followed myelography for suspected cervical lesions, in 11 of 17 patients having surgically confirmed lumbosacral adhesive arachnoiditis, and in 34 of 67 patients in whom this condition was suspected from clinical data. Relief followed intrathecal injection of methylprednisolone acetate in 11 of 12 patients who had not been relieved by oral administration of hydrocortisone, and in 26 of 50 patients unrelieved by previous epidural administration of corticosteroids. This surely indicates that relief is a local and not a systemic effect of the medication.

### Complications

In our three-year experience with more than 1,000 lumbar intrathecal injections of 1 to 2 ml. or 40 to 80 mg. of methylprednisolone acetate suspension, undesirable

effects have consisted only of transient (up to 48 hours), mild aggravation of leg and back pain. Mild spinal fluid pleocytosis has been found. Large single doses (up to 5 ml. or 200 mg.) of methylprednisolone acetate suspension produce severe symptoms of meningeal irritation and are not advised. Some patients have received from 320 to 800 mg. of the drug in divided doses over periods of several weeks with no demonstrably ill effects.

Cisternal injections of methylprednisolone acetate invariably caused nausea and headache, followed by emesis persisting for from three to four hours. This avenue of introduction is not advised. Intrathecal injection of soluble corticosteroids produced signs of meningeal irritation, and should be avoided.

Systemic effects of cortisone administration were minimal in this series of patients, because of the slow rate of absorption from the subarachnoid space. In four patients, however, a water-retention syndrome developed, but disappeared within from 15 to 20 days.

In advanced stages of pialarachnoid adhesions the introduction of the needle for the lumbar puncture may be exquisitely painful. In some patients it was impossible to obtain fluid, suggesting the presence of a complete subarachnoid block such as that shown by myelography in case 1. Injection of methylprednisolone acetate in these patients was painful, pain relief usually incomplete, and recurrence frequent.

### Discussion

A review of our experience and a study of the literature<sup>4-9</sup> suggest that Pantopaque injected into the subarachnoid space may in some instances produce immediate symptoms of local meningeal inflammation and nerve root pain. This effect is aggravated by the simultaneous presence of blood in the cerebrospinal fluid. The cerebrospinal fluid in acute cases contains an increased number of leukocytes, without an increase in the protein content. In some patients, either with or without the acute reaction, chronic adhesive arachnoiditis develops, which may cause the onset of back and leg pain long after the performance of myelography.

Confronted by an increasing number of patients with disabling back and leg pain who had undergone Pantopaque myelography, we have been constrained to apply to them the previously authenticated antiinflammatory effects of local injections of adrenocorticosteroids.<sup>10,11,13,14</sup> It was found that administration of the steroids by mouth and by epidural injection was disappointing in its effect. The intrathecal injection of a suspension of methylprednisolone acetate in 1-ml. (40-mg.) or 2-ml. (80-mg.) amounts was followed by gratifying improvement in 60 per cent of the patients. No complications have followed this technic. In cases of incomplete or temporary improvement, the injections are profitably repeated at weekly intervals.

In some earlier cases, steroids in solution were used, and resulted in considerable temporary discomfort apparently because of the contained solvents.<sup>1</sup> The intrathecal use of such preparations is not advised. In this series the usual dose of methylprednisolone acetate was 80 mg. We now seldom use more than 40 mg. in a single dose.

## Conclusions

1. The intrathecal injection of Pantopaque in some cases is followed by early or late meningeal reactions, of mild to severe degree, in some instances progressing to chronic adhesive arachnoiditis.
2. Intrathecal injections of small amounts of a suspension of methylprednisolone acetate reduced the radicular pain accompanying such meningeal reactions in 60 of 100 patients.
3. No adverse effects of this therapy have been noted in the treatment of chronic low back and sciatic pain that sometimes follows Pantopaque myelography.

## Acknowledgment

The authors herewith express appreciation to their colleague, Wallace B. Hamby, M.D., for valuable assistance and guidance in the preparation of this manuscript.

## References

1. Sehgal, A. D., and Gardner, W. J.: Corticosteroids administered intradurally for relief of sciatica. *Cleveland Clin. Quart.* 27: 198-201, 1960.
2. Goebert, H. W., Jr.; Jallo, S. J.; Gardner, W. J.; Wasmuth, C. E., and Bitte, E. M.: Sciatica: treatment with epidural injections of procaine and hydrocortisone. *Cleveland Clin. Quart.* 27: 191-197, 1960.
3. Strain, W. N. L.; Plati, J. T., and Warren, S. L.: Iodinated organic compounds as contrast media for radiographic diagnoses. I. Iodinated aracyl esters. *J. Am. Chem. Soc.* 64: 1436-1440, 1942.
4. Erickson, T. C., and van Baaren, H. J.: Late meningeal reaction to Pantopaque used in myelography (report of case which terminated fatally). *Tr. Am. Neurol. A.* 77: 134-137, 1952.
5. Erickson, T. C., and van Baaren, H. J.: Late meningeal reaction to ethyl iodophenylundecylate used in myelography; report of case that terminated fatally. *J.A.M.A.* 153: 636-639, 1953.
6. Hurteau, E. F.; Baird, W. C., and Sinclair E.: Arachnoiditis following use of iodized oil. *J. Bone & Joint Surg.* 36-A: 393-400, 1954.
7. Luce, J. C.; Leith, W., and Burrage, W. S.: Pantopaque meningitis due to hypersensitivity. *Radiology* 57: 878-881, 1951.
8. Tarlov, I. M.: Pantopaque meningitis disclosed at operation. *J.A.M.A.* 129: 1014-1016, 1945.
9. Davies, F. L.: Effect of unabsorbed radiographic contrast media on central nervous system. *Lancet* 2: 747-748, 1956.
10. Dougherty, T. F., and Schneebeli, G. L.: Role of cortisone in regulation of inflammation. *Proc. Soc. Exper. Biol. & Med.* 75: 854-859, 1950.
11. Humphrey, J. H.: Effect of cortisone upon some experimental hypersensitivity reactions. *Brit. J. Exper. Path.* 32: 274-283, 1951.
12. Oppenheimer, J. H., and Reister, W. H.: Influence of cortisone on leptomeningeal reaction induced by talc. *Proc. Soc. Exper. Biol. & Med.* 83: 844-847, 1953.

13. Feldman, S., and Behar, A. J.: Effect of intrathecal hydrocortisone on advanced adhesive arachnoiditis and cerebrospinal fluid pleocytosis; experimental study. *Neurology* 11: 251-256, 1961.
14. Samueloff, M., and Feldman, S.: Effect of cortisone acetate administered intracisternally in cats. *A.M.A. Arch. Neurol. & Psychiat.* 72: 599-604, 1954.
15. Ragan, C.; Howes, E. L.; Plotz, C. M.; Meyer, K., and Blunt, J. W.: Effect of cortisone on production of granulation tissue in rabbits. *Proc. Soc. Exper. Biol. & Med.* 72: 718-721, 1949.
16. Zachariae, L.: Hydrocortisone acetate applied intraperitoneally; inhibitory effect on adhesions produced by talc. *Acta endocrinol.* 16: 149-159, 1954.
17. Baker, B. L., and Whitaker, W. L.: Interference with wound healing by local action of adrenocortical steroids. *Endocrinology* 46: 544-551, 1950.
18. Spain, D. M.; Molomut, N., and Haber, A.: Biological studies on cortisone in mice. *Science* 112: 335-337, 1950.
19. Feldman, S.; Behar, A. J., and Samueloff, M.: Effect of cortisone and hydrocortisone on piaarachnoid adhesions; experimental study. *Arch. Neurol. & Psychiat.* 74: 681-688, 1955.
20. Pieper, S. J. L., and Fields, W. S.: Failure of amyotrophic lateral sclerosis to respond to intrathecal steroid and vitamin B<sub>12</sub> therapy. *Neurology* 9: 522-526, 1959.
21. Choremis, C.; Papadatos, C.; Gargoulas, A., and Drosos, C.: Intrathecal hydrocortisone in treatment of tuberculous meningitis. *J. Ped.* 50: 138-144, 1957.