

Cleveland Clinic Quarterly

Volume 24

OCTOBER 1957

No. 4

ILEAL VALVE POUCH FOR URINARY TRACT DIVERSION

Preliminary Report of Eight Cases

RUPERT B. TURNBULL, JR., M.D.,
Department of General Surgery

and

CHARLES C. HIGGINS, M.D.
Department of Urology

FOR many years surgeons have known that exstrophy of the bladder can be corrected by utilizing the rectum as a reservoir for the urine, and many types of surgical procedures have been advocated for transplanting the ureters into the rectosigmoid. In 1894, Maydl¹ recommended that the trigone of the bladder be implanted in the rectosigmoid, in the hope of minimizing the incidence of postoperative ureteral stenosis, stasis, and eventual pyelonephritis. However, until 1911, the operation was but infrequently advocated because the operative mortality and morbidity were extremely high. In 1911, Coffey² advocated the trough principle of implanting the ureters into the bowel; his technic (the Coffey I technic) has been widely used and has brought about a pronounced reduction in the operative mortality and morbidity.

Within the last few years, the Coffey I technic has been modified by performing a mucosa-to-mucosa anastomosis between the ureter and the rectosigmoid, in the hope of minimizing the incidence of stenosis at the site of implantation. Unfortunately, despite the meticulous care with which the anastomosis is made,

one potentially formidable complication may ensue, namely, ureteral obstruction. If the obstruction is slight and the patient has no renal infection, he may live a comparatively normal life for many years. Hyperchloremic acidosis, which may follow this surgical procedure, may be minimized or controlled by administering 10 per cent sodium citrate, the dosage being influenced by blood chemistry studies. But, only too often, as a review of published statistics reveals, ureteral obstruction and stasis cause pyelonephritis, and the patient subsequently dies from urosepsis and renal failure.

Recently the utilization of the isolated loop of ileum (Bricker³) as a reservoir for the urine has yielded gratifying results. Postoperatively hyperchloremic acidosis occurs less frequently, the incidence of ureteral obstruction appears to be reduced, and the incidence of pyelonephritis is minimal. The patient must wear a receptacle to collect the urine draining from the ileal pouch, or the ileal pouch may be catheterized at stated periods of time. This device causes very little discomfort and odor is avoided, yet many patients prefer if possible to avoid even this slight inconvenience.

The question, therefore, arose as to whether it would be feasible to combine the two operative procedures and eliminate the objectionable features of both: (1) To implant the ureters into an isolated ileal loop by a direct mucosa-to-mucosa technic, thereby minimizing the incidence of ureteral stenosis, hydro-ureter, hydronephrosis, and pyelonephritis with subsequent renal failure. (2) To implant the end of the isolated ileal loop into the rectosigmoid in order that the bowel may serve as a conduit for the urine. (3) To implant the free end of the ileum into the rectosigmoid in such a manner that stenosis will not ensue, and to provide a valvular mechanism for preventing reflux of gas and contents of the bowel into the isolated ileal loop.

It was proposed, therefore, that a Bricker's pouch³ (uretero-ileostomy) be constructed so that the distal end of the pouch could be fashioned into an ileostomy and thrust into the sigmoid colon wherein accurate mucosa-to-mucosa anastomosis could be carried out, a combination of a one-way valve to prevent reflux with a known satisfactory method of urinary stream diversion. Experimental construction of such a pouch in the dog was successful in that barium could not be forced from the colon through the valve into the pouch.

This preliminary report is based on the early observation of eight patients each of whom had an isolated uretero-ileal pouch made after the method described by Bricker,³ except that the ileostomy was placed *inside* the sigmoid colon to divert the urine internally and to act as a valve.

Technic

After examining the abdomen for other anomalies, we select an eight-inch segment of ileum and isolate it from the rest of the ileum about six inches proximal to the cecum. Next, the isolated segment is pulled posteriorly and the ileal continuity is restored above. The distal end of the isolated segment is freed

down into the depths of the mesentery to provide mobility, while the proximal end is freed to a lesser extent. A Babcock clamp is inserted into the distal end for a distance of two inches, the mucosa is gripped while the free end is pulled back, thus causing an intussusception for about two inches. The turned-over everted end of the ileum is sutured in position with five or six fine silk sutures so that a permanently everted ileostomy is constructed. Most of the fat of the everted ileostomy mesentery is trimmed so that it does not crowd or bulge the everted end. The entire isolated ileal segment is then turned counter-clockwise on its mesentery through 180 degrees so that the ileostomy rests on the left side of the pelvis while the other end rests on the right side. An incision is then made in the sigmoid colon three or four inches above the promontory of the sacrum, and the entire ileostomy is thrust in. Interrupted chromic catgut sutures are

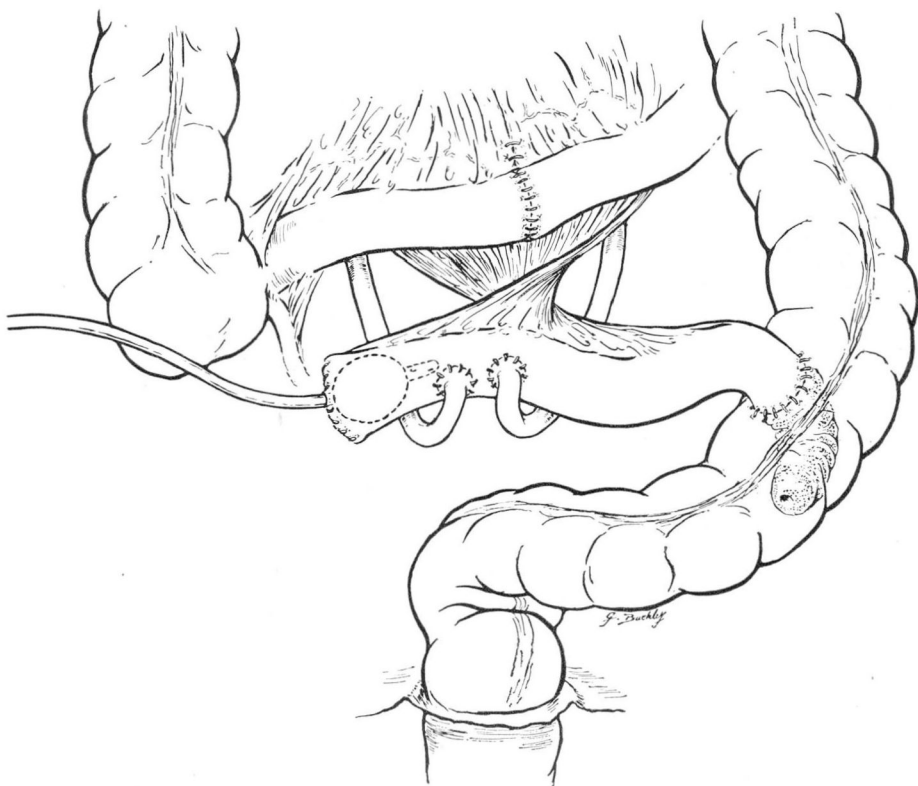


Fig. 1. Sketch showing the completed uretero-ileosigmoidostomy. The distal end of the valve pouch, with the turned-over everted end is in the sigmoid colon. The ureters are sutured to the ileal segment; the entire isolated ileal segment has been turned counter-clockwise through 180 degrees on its mesentery. The French No. 14 Foley catheter is in the antiperistaltic end of the pouch for temporary decompression.

placed between the turned-back end of the everted ileostomy and the wall of the colon around the colostomy, so that accurate mucosal approximation may be obtained. In addition, seromuscular sutures are placed.

The previously freed and divided ureters are now brought into the field in the region of the promontory of the sacrum, the left ureter having been drawn medially through the base of the mesentery of the sigmoid colon. Anastomosis between the ureters and the pouch (Fig. 1) is accomplished with a few fine chromic catgut sutures through the end of the ureter and through all layers of the ileum so that an accurate full-thickness and mucosa-to-mucosa anastomosis is obtained. Since the isolated ileal pouch and its various connections lie posterior and inferior to the rest of the small intestine, no particular obliteration of the various spaces seems to be necessary. A French No. 14 Foley catheter is inserted into the right side or antiperistaltic end of the pouch within an inch or two of the ureteral anastomoses, and the end of the pouch is closed with two layers of fine catgut. The catheter is drawn through the abdominal wall just above the inguinal ligament on the right side and is utilized as a retrograde (immediate) decompression apparatus for the pouch. The small intestine and the omentum are pulled down and the abdomen is closed.

Results

The valve pouch as described was constructed in the first patient on June 1, 1956; since then it has been constructed in eight patients. The indications and course for each were as follows.

(1) An infant boy, aged six months, with exstrophy of the bladder, had had bilateral ureterosigmoidal transplants followed by bilateral ureteral obstruction and pyelonephritis with intermittent uremia. A uretero-ileosigmoidostomy was performed and the convalescence was uncomplicated. Postoperative urograms and blood chemistry determinations showed little disturbance, with normal values for blood urea and a slight intermittent acidosis. The child remains well, although he has had two attacks of pyelonephritis, the last attack occurring eight months ago. The most recent urogram was made 12 months postoperatively and the degree of hydronephrosis and hydroureter was the same as that noted prior to surgery; there has been good renal drainage.

(2) A girl at the age of two years, because of exstrophy of the bladder, had the right and left ureters transplanted into the sigmoid colon. Two years later a valve pouch was constructed because of progressive and marked left hydronephrosis and decreased function in the right kidney with hydronephrosis. The hospital course and postoperative period was uneventful; so far (three-month follow-up) there has been no evidence of pyelonephritis.

(3) An infant boy, aged 9 months, in March 1957, because of exstrophy of the bladder and a rather marked prolapse of the rectum, underwent uretero-ileosigmoidostomy and construction of a valve pouch rather than transplantation of the ureters directly into the sigmoid colon. During the postoperative period a low-grade fever developed and it was thought that a mild urinary tract infection was in progress. However, this was easily controlled with antibiotics. A urogram was normal one month following the surgical procedure. Blood chemistry evaluations have revealed normal blood CO₂ content and urea concentration. Further studies are planned.

(4) A woman, aged 18 years, was observed with exstrophy of the bladder bilateral hydroureters, hydronephrosis, and renal failure. On September 22, 1947, at the age of seven years, she underwent bilateral cutaneous ureterostomy. In June 1957, a valve pouch was constructed so that she could be socially rehabilitated. One month following surgery, severe pyelonephritis developed and was treated effectively with antibiotic drugs; and the urogram revealed a moderate hydronephrosis and hydroureter but to a lesser degree. Blood chemistry studies revealed normal CO_2 and urea values.

(5) A boy, aged five years, had exstrophy of the bladder. A valve pouch was constructed primarily rather than ileosigmoidal transplants. The postoperative course was uneventful. Blood values for urea, CO_2 , chlorides, and sodium were normal. Follow-up roentgen studies are planned.

(6) An infant boy, aged 16 months, had exstrophy of the bladder. Two attempts were made to reconstruct the bladder; however, both times the bladder extruded through the closure. A valve pouch was constructed rather than ileosigmoidal transplants. A minimal postoperative fever was interpreted as being caused by a mild infection of the urinary tract and responded to antibiotic drugs. The child remains well after two months and has gained weight. Follow-up urogram and blood chemistry evaluations are planned.

(7) A boy, aged 13 years, had exstrophy of the bladder. Two previous attempts elsewhere to reconstruct the bladder failed. A valve pouch was constructed and the postoperative course was uneventful. Postoperative blood CO_2 , urea, sodium, and chloride values were normal. The urogram made on the tenth postoperative day revealed moderate hydronephrosis and hydroureter. Further postoperative studies are planned.

(8) An infant boy, aged 14 months, had bilateral ureterosigmoidal anastomosis performed at the age of eight months, resulting in ureteral obstruction with nonvisualization of the left and right hydroureter, hydronephrosis and pyelonephritis, and intermittent uremia with hypertension. Bilateral cutaneous ureterostomy was performed as a preliminary procedure and two weeks later a valve pouch was constructed. Blood urea values dropped rapidly from 60 to 16 mg. per 100 ml. and by the tenth day the blood pressure was normal. The blood chemistry values for urea, CO_2 , and chlorides have remained normal. There has been no evidence of pyelonephritis. Follow-up studies are planned.

Discussion

Because of the short follow-up time no definite conclusions can be reached as to whether this type of urinary tract diversion will continue to function satisfactorily. Except for the first patient in whom the pouch was constructed, the follow-up period with blood chemistry studies and roentgen examinations of the urinary tract is insufficient or of too short a duration. However, the 15-month course of the first patient is encouraging.

Mechanically, the pouch seems to be effective. Gas or feces have not been observed to reflux through the catheter placed in the pouch at the time of surgery, and the urine is ejected completely into the sigmoid colon through the intrasigmoid ileostomy. Colon roentgenograms taken after barium enema and rectal air insufflation have failed to reveal any reflux into the pouch. Cine-radiographic films show a competent valve.

Conclusions

An ileal valve pouch for internal diversion of the urinary tract through a uretero-ileosigmoidostomy has been constructed in eight patients. Conclusions as to its ultimate effectiveness cannot be stated at this time, but to date the end-in-side ileosigmoidal anastomosis has prevented gross reflux of gas and feces into the isolated ileal segment. Roentgen studies of the urinary tract, together with frequent blood chemistry evaluations have been made in one half of the cases and have indicated good function. In the event of late complications or failure of the pouch to function as proposed, the distal end may be retrieved from the sigmoid colon and brought out on the surface of the skin as an ileostomy, thus converting to the known Bricker's³ pouch.

References

1. Maydl, K.: Ueber die Radikaltherapie der Blasenektomie. *Wien. med. Wchnschr.* **44**: 1113, 1169, 1209, 1256, 1297, 1894.
2. Coffey, R. C.: Physiologic implantation of severed ureter or common bile-duct into intestine. *J.A.M.A.* **61**: 397-403, 1911.
3. Bricker, E. M.: Substitution for urinary bladder by use of isolated ileal segments. *S. Clin. North America* **36**: 1117-1130, Aug. 1956.