

# LENS IN ANTERIOR CHAMBER OF THE EYE: SURGICAL REMOVAL

ROBERT L. ALEXANDER, M.D. and ROSCOE J. KENNEDY, M.D.

Department of Ophthalmology

**I**MMEDIATE surgical intervention is mandatory in patients with the lens located in the anterior chamber of the eye because of the frequent complications of glaucoma and secondary iritis. Yet, because of the rare occurrence of this condition, many surgeons are not prepared to perform the required operation.

During a five year period at the Cleveland Clinic, five cases were seen with lens dislocated in the anterior chamber, four were operated. The fifth was not operated because the eye was blind and the lens partially absorbed. Those patients with a lens dislocated behind the iris diaphragm are not included since this type of posterior lens dislocation requires a different surgical approach.

McDonald<sup>1</sup> in a report of 94 cases of all types of dislocated lens seen at Wills' Eye Hospital during a five year period found only three instances of dislocation in the anterior chamber, the remainder presumably being dislocated into the vitreous.

The following case reports are representative of those patients seen at the Clinic with this condition.

## CASE REPORTS

**Case 1.** This 42 year old woman is illustrative of those patients with traumatic dislocation of the lens into the anterior chamber. Two months prior to examination she had bumped her head on a kitchen cabinet door. The right eye had been slightly painful following the accident but the pain slowly subsided. Two weeks before examination, the eye suddenly became painful and red. She obtained no relief from home remedies.

Positive physical findings were confined to the right eye, the upper lid of which was slightly edematous. The intra-ocular tension of the eye was 70 mm. Hg. Schiotz. The conjunctiva showed superficial and ciliary injection. The cornea showed bedewing throughout. The anterior chamber was filled with the partially opaque lens that touched the cornea. The base edge of the iris was visible. No fundus view could be obtained.

**Case 2.** This 64 year old woman is illustrative of those who experience no pain although the lens is in the anterior chamber. At examination the patient complained of blurring vision in the right eye and occasional double vision. The symptoms had been present for two years. There was no history of trauma. The eyes had been neither painful nor red. The positive physical findings were confined to the right eye. Vision in the right eye was hand movement at 1½ M., the tension ranged from 24 to 27 mm. Hg. Schiotz. The conjunctiva and cornea were clear. In the anterior chamber lay a partially calcified lens (fig. 1a). Part of the fundus could be viewed behind the lens and it showed an inactive choroiditis.

This case is of particular interest because it is possible that this patient had a lens in the anterior chamber for two years and yet did not develop glaucoma. In addition, the cornea remained unchanged with the lens resting against its posterior surface.

Three other cases were seen: one in a four year old boy with the lens previously dislocated behind the iris who had a spontaneous luxation of the lens into the anterior chamber of the left eye; one in an 18 year old man who had Marfan's syndrome, followed for ten years, who had a spontaneous luxation into the anterior chamber of the left eye; one in a 75 year old woman who did not have a previously known dislocated lens but developed a spontaneous dislocation of the lens into the left anterior chamber.

## PRINCIPAL SURGICAL PROCEDURES

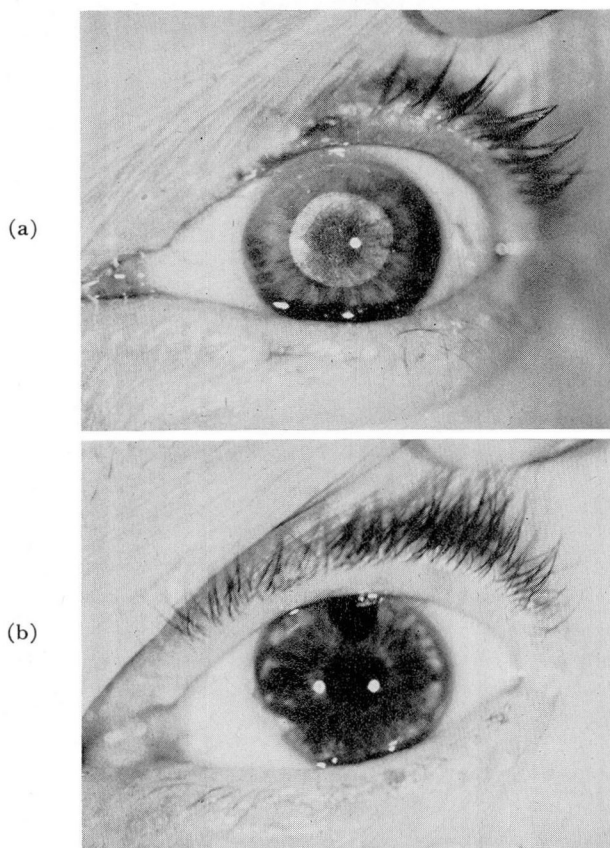
In the surgical removal of a lens four considerations are immediate and important: (1) prevention of loss of lens into posterior chamber; (2) prevention of a loss of vitreous; (3) prevention of entrance of vitreous into anterior chamber; and (4) prevention of future complications in the eye.

A successful technic consists essentially of the following:

1. Use of a strong miotic, such as di-isopropyl fluorophosphate, that produces a pin-point pupil and brings the iris down behind the lens.
2. Use of a preplaced suture at the corneoscleral junction.
3. Careful opening of the chamber as follows:
  - a. Make a small incision at 12 o'clock with a von Graefe knife in such a manner that the blade does not come near the lens. A keratome must never be used because of the danger of its penetrating the lens as it enters the chamber.
  - b. Enlarge the wound with scissors. This opening must be large enough to allow the lens to be delivered without distortion.
4. Use of a Verhoeff type or Arruga type of cataract forceps to grasp the nearest edge of the capsule lightly and gently pull it forward. No counter pressure at 6 on the limbus will be needed, as the lens is free in the chamber and needs only slight traction to guide it out through the wound.
5. By drawing the suture taut behind the lens as it is delivered, the lens is prevented from slipping back into the anterior chamber.
6. Careful inspection of the anterior chamber for evidence of vitreous herniation through the pupil after the lens is delivered.
7. Performance of a large peripheral iridectomy leaving the sphincter border intact. An iridectomy of this type is chosen to prevent the development of glaucoma or iris prolapse.
8. The rest of the procedure and hospital course is the routine followed for any intracapsular cataract surgery.

The completed operation appears as illustrated in figure 1b.

Kirby<sup>2</sup> in his brief discussion of the luxation of the lens into the anterior chamber stated that the lens "may be withdrawn by traction with suitable



**Fig. 1.** (Case 2) (a) Partially calcified lens in anterior chamber. (b) One year after surgery.

forceps, suction cup, or with a loop.” The forceps is all that is usually indicated, for if a suction cup is introduced it takes so much room in the anterior chamber that the lens is forced backward against the iris endangering the location of the dislocated lens. In this way the lens might be forced back through the pupil and into the vitreous cavity. The suction cup might be applied to the posterior surface of the lens to force the lens against the cornea, and the suction cup acts as a loop. The loop could be used as suggested by Kirby but here enters the danger that it will engage the free iris border and pass into the posterior chamber. In this series, forceps has been found adequate for it has provided guidance to the lens in removing it from the chamber and the slight traction necessary for extraction. Since the lens is lying free in the anterior chamber, it needs little help to deliver itself. The forceps permits a lens extraction with minimal possible trauma to the tissue, one of the first considerations of the ophthalmic surgeon.

Duke-Elder<sup>3</sup> said that in these cases “miotics are to be avoided, indeed,

eserine may precipitate a glaucomatous attack." This is contrary to our experience for we have successfully employed strong miotics to produce a small pupil. This caused the iris to act as a diaphragm holding the lens in the anterior chamber until entrance could be effected and the misplaced lens delivered. For this reason case 1 was chosen to illustrate that in the presence of glaucoma, a miotic could be used until the lens was delivered. The patient's postoperative course was not affected. In no patient did the miotic cause glaucoma but in patients where glaucoma existed it did not relieve the disease. Conversely, atropine may dilate the pupil to such an extent that the lens is permitted to luxate into the posterior chamber or vitreous.

The patients must be carefully followed for evidence of continued or secondary glaucoma. Case 1 was given  $\frac{1}{4}$  per cent eserine daily for the two weeks immediately following her discharge from the hospital. It was then discontinued and has not been resumed for the past five years. Case 2 had no elevation of intra-ocular tension for three years after operation.

## SUMMARY

The important steps in the care of patients with the lens dislocated in the anterior chamber of the eye are:

1. Operate and remove the lens as soon as miotics have reduced the pupil size.
2. Remove the lens in capsule.
3. Perform a large peripheral iridectomy.
4. Insist upon a close follow-up for years after the operation.

## References

1. McDonald, P. Robb and Purnell, J. E.: The dislocated lens. Transactions of the Section of Ophthalmology of the A.M.A. at the Ninety-Ninth Annual Session, San Francisco, June 26-30, 1950, A.M.A., Chicago, Illinois, pp. 56-74.
2. Kirby, D. B.: Development of system of intracapsular cataract extraction. *Am. J. Ophth.* 27:124-136 (Feb.) 1944.
3. Duke-Elder, Stewart: Text-Book of Ophthalmology, vol. 3, St. Louis, C. V. Mosby Co., 1947, pp. 3308-3309.