

ATLAS-AXIS DISLOCATION FOLLOWING CERVICAL ADENITIS

ROBERT D. MERCER, M.D.
Department of Pediatrics

ROTARY dislocation of the atlas on the axis in association with infections about the head and neck and without known trauma is a syndrome which is seldom described. The rarity of the lesion is more apparent than real and is related to a general lack of familiarity with this syndrome on the part of the physicians. The condition was described as early as 1908.¹ The diagnosis is easily established and treatment is simple.

Anatomically, there is a forward rotary dislocation of the atlas on the axis. The articular facet on one side or the other of the atlas slips forward and downward on its opposing member on the axis and locks into position. The motion is a rotary one on the dens and requires relaxation of the various ligaments supporting the atlanto-axial articulation. There is no apparent fracture in the dens or tearing of the transverse ligament.

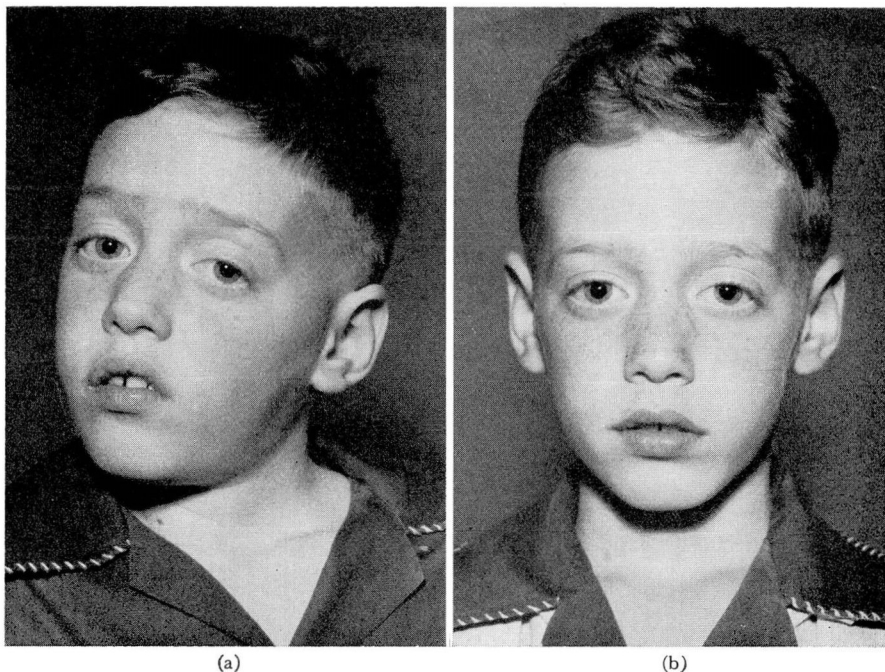

FIG. 1. (a) Patient on admission. Torticollis with chin toward right shoulder. (b) Patient subsequent to head traction. Complete recovery.

Clinically, this syndrome is most often found in children of either sex between the ages of 5 and 12.² In our experience, it is most frequently seen following painful cervical adenitis. However, it has also been described following acute rheumatic fever, scarlet fever, mastoiditis, tonsillitis, tonsillectomy and nasopharyngitis.^{3,4,5} The child apparently holds his head to one side to relieve the pain of a cervical adenitis and, after a variable period of time, he is unable to straighten it. When the syndrome develops following such an episode, the presenting problem is one of painful torticollis. Frequently all signs of the initial adenitis have disappeared.

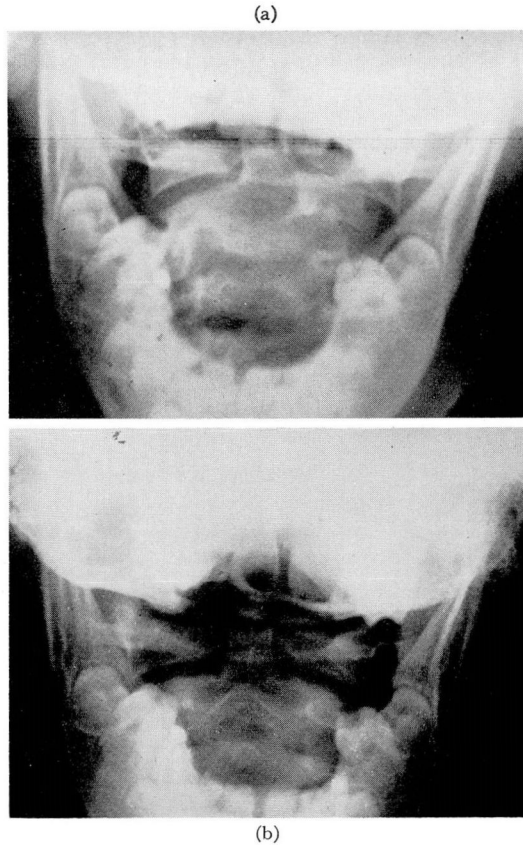


FIG. 2. (a) Roentgenogram taken through open mouth. Note asymmetry of transverse process of atlas and left lateral mass of atlas dislocated anteriorly and downward. (b) Roentgenogram after 4 days of head traction.

On examination, the head is seen to be in the position of classical torticollis. The chin is drawn in and turned toward the side opposite the dislocation. The head is forward with the occiput tipped toward the side of the dislocation. The patient often supports his head with his hands. On palpation, there may be

some tenderness at the base of the occiput. The spinous process of the axis may be displaced laterally to the midline away from the side of the dislocation. There is usually no spasm of the sterno-cleido-mastoid muscles. There is some limitation in opening the mouth, and the size of the nasopharynx may appear to be reduced. On palpation of the pharynx just above the posterior border of the soft palate an unusual prominence can be felt which is the displaced lateral mass of the atlas. There is considerable limitation of rotation of the head. Attempted rotation is painful and can be accomplished only by rotating the lower cervical vertebrae and the upper trunk. Abnormal neurologic signs resulting from pressure on the cord by the dens are rare but have been described.²

The diagnosis can be established definitely by roentgenograms of the cervical spine. A lateral view will demonstrate forward dislocation of the lateral mass of the atlas. The best views, however, are obtained through the open mouth. Evident asymmetry of the lateral processes of the atlas and the axis may be observed. There is also narrowing of the joint space between the atlas and the axis in the side of the dislocation.

The most satisfactory treatment of nontraumatic dislocation of the atlas on the axis is by head traction. Reduction by manipulation under anesthesia is not advised. The patient is placed on his back with head in a slightly hyperextended position. The use of a mattress shorter than the bed facilitates hyperextension of the head. Traction is applied through a head halter running over a pulley at the head of the bed with appropriate weights attached. Countertraction is obtained by elevating the head of the bed. Traction is maintained until good reduction can be observed by repeated roentgenograms. This may require from a few days to a few weeks. When good reduction has been obtained, the head is maintained in position with a Taylor collar for 1 or 2 months. Recurrences are rare.

The exact pathogenesis of this lesion is unknown. Various theories have been proposed such as metastatic effusion into the joint spaces,¹ hyperemia and decalcification of the ligamentous attachments,^{6,7} spasm and contraction of the prevertebral muscles,⁴ or a combination of all of these factors.⁸ The following sequence of events probably occurs:

1. Pain in the region of the upper neck causes voluntary splinting in the position of torticollis.
2. The ligamentous structures are weakened by decalcification of their bony attachments as a result of hyperemia accompanying infection. The vascularity of growing bones may explain the prevalence of this syndrome in the younger age groups.
3. Effusion into the joint spaces may be an added factor in weakening the ligaments.
4. Forward displacement occurs since the weight of the head is normally forward of its center of gravity³ and the normal inclination of the lateral articular facets is downward, outward and forward.
5. The displaced atlas is locked into position by spasm and contraction of the prevertebral muscles.

Report of a Case

A 7 year old white boy was first seen at the Cleveland Clinic on April 24, 1952, complaining of a "twisted neck." Six weeks previously, he had experienced a sore throat and painful cervical lymph glands. He was treated over a period of 2 to 3 weeks with penicillin and a sulfonamide by a pediatrician and seen in consultation by an otolaryngologist. The cervical adenitis had responded to treatment but torticollis had appeared and had persisted.

On examination, the child was observed to be holding his head in the position of torticollis (fig. 1a); the chin was toward the right shoulder and he was supporting his head with his hands. The cervical lymph glands were not tender. Rotary motion of the head was impossible without rotation of the upper trunk. Slight tenderness was noted below the occiput. The pharynx was not palpated. No abnormal neurologic signs were present and the remainder of the physical examination was normal. Routine examination of the blood and urine showed no abnormalities.

A dislocation of the atlas on the axis was suspected and appropriate x-rays were obtained. Severe asymmetry was evident in the joint spaces between the atlas and the axis. The joint space was narrower on the left than on the right. The left lateral mass of the atlas was seen to be dislocated anteriorly with regard to the axis (fig. 2a).

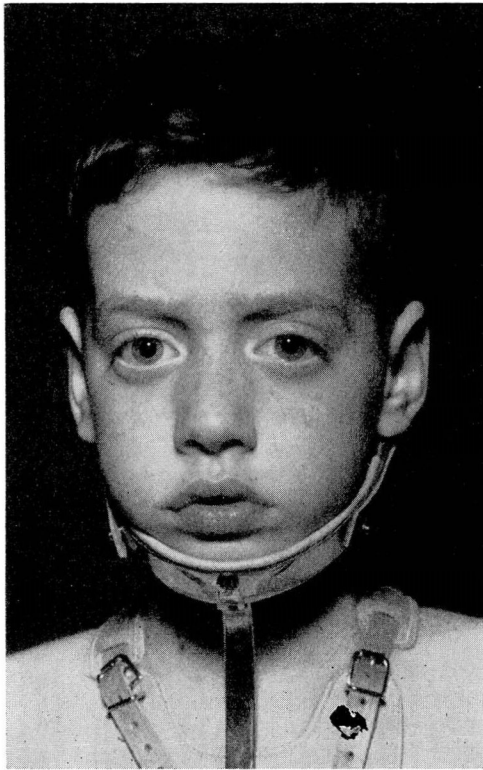

FIG. 3. Taylor brace supporting the head following reduction of dislocation.

Traction was applied by means of a head halter with an 8 pound weight. Complete reduction was demonstrated in 4 days (fig. 2b). Traction was maintained for 10 days and then replaced with a Thomas collar (fig. 3). At the end of 6 weeks, this was removed and the child has remained well (fig. 1b).

Summary

The syndrome of nontraumatic dislocation of the atlas on the axis is described. This condition occurs following infections about the upper neck and it is thought to be more common than generally realized. The diagnosis is easily established when considered, and treatment is by simple head traction followed by support of the head over a period of a few months.

Acknowledgment: This patient was under the orthopedic supervision of Dr. A. W. Humphries of the Cleveland Clinic to whom we offer our sincere thanks.

References

1. Wittek, A.: Ein Fall von Distensionsluxation im Atlanto-epistropheal-Gelenke. Munchen. med. Wchnschr. 55:1836, 1908.
2. Wilson, M. J., Michele, A. A. and Jacobson, E. W.: Spontaneous dislocation of the atlanto-axial articulation, including report of case with quadriplegia. J. Bone & Joint Surg. 22:698-707 (July) 1940.
3. Berkheiser, E. J. and Seidler, F.: Nontraumatic dislocations of the atlanto-axial joint. J.A.M.A. 96:517 (Feb. 14) 1931.
4. DesFosses, P.: Un cas de maladie de Grisel; torticollis naso-pharyngien par subluxation de l'atlas. Presse med. 38:1179 (Aug. 30) 1930.
5. Evans, W. A., Jr.: Pathologic dislocations at atlanto-axial joint: unusual complication of rheumatic fever. Radiology 37:347-350 (Sept.) 1941.
6. Greig, D. M.: Clinical Observations on the Surgical Pathology of Bone. Oliver & Boyd, 1931.
7. Hanflig, S. S. and Schlosberg, C.: Nontraumatic dislocation of atlanto-axial joint. New England. J. Med. 223:713-716 (Oct. 31) 1940.
8. Hess, J. H., Brownstein, I. P. and Abelson, S. M.: Atlanto-axial dislocations unassociated with trauma and secondary to inflammatory foci in the neck. Am. J. Dis. Child. 49:1137-1147 (May) 1935.