

# TUMORS OF THE PAROTID GLAND

ROBIN ANDERSON, M.D.

Department of Plastic Surgery

**T**UMORS of the parotid gland are of particular interest for several reasons: first, despite years of intensive study since Virchow's first description of the parotid mixed tumor in 1863, both their origin and pathologic classification remain subjects for speculation; secondly, the results of treatment, especially of malignant lesions, have been most discouraging; and finally, the treatment of even the most benign parotid neoplasm is complicated by its intimate relationship with the facial nerve and the threat of disfiguring facial paralysis. Recent contributions by Bailey,<sup>1</sup> Brown,<sup>2</sup> and Kirklin et al<sup>3</sup> have contributed materially to the clarification of the problems and the establishment of sound, definite surgical therapy.

Anatomically, the parotid gland may be described as a dumb-bell shaped organ, with a large, superficial portion lying outside the mandible connected by a slender isthmus to smaller deep portion. McCormack et al<sup>4</sup> have described a natural cleavage plane between these two lobes in which the facial nerve is found. The facial nerve leaves the skull via the stylomastoid foramen, and courses forward to enter the gland at its posterior margin, dividing almost immediately into two trunks which pass around the isthmus. Careful dissections of the nerve<sup>4</sup> have shown some anastomosis between these two trunks around the isthmus in approximately three-quarters of the dissections. This would explain the lower than expected incidence of facial paralysis when individual nerve filaments are divided within the gland. A tongue of gland tissue extending forward along the parotid duct, often termed the accessory parotid gland, is of significance since the removal of a tumor in this portion endangers the duct as well as the superior filaments of the facial nerve.

## Pathology

A simple classification of parotid tumors is shown in table 1. The percentages given are those of Brown et al<sup>2</sup> in their series of 149 tumors.

Two-thirds of all parotid tumors fall into the category of benign mixed tumors (fig. 1). Two cell types are found: first, well differentiated epithelial cells with dark nuclei, arranged in sheets or cords; and secondly, connective tissue cells in spindle or stellate arrangement, with a characteristic intercellular mucinous material, often resembling cartilage. While a typical section shows these histologic features, it is not unusual to see tumors in which one element predominates to the exclusion of the other. A section without mucinous connective tissue, and consisting entirely of sheets of epithelial cells is easily mistaken for carcinoma.

There are two current theories as to the origin of parotid gland mixed

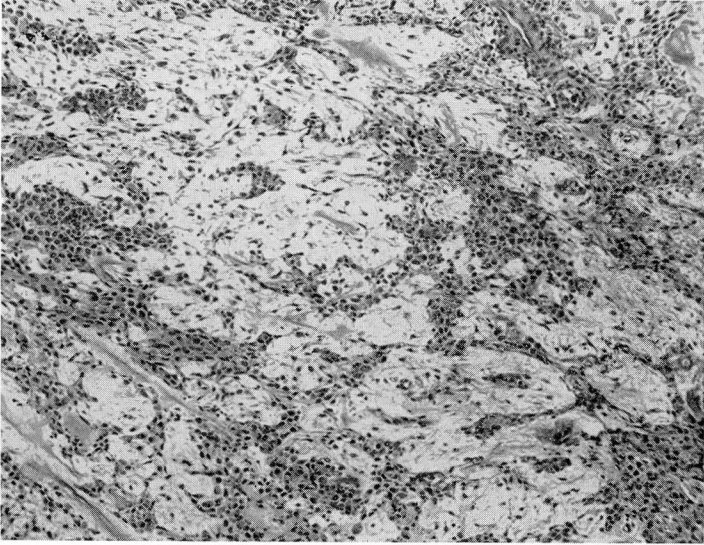


FIG. 1. Typical mixed tumor showing clumps of epithelial cells and mucinous connective tissue (x70).

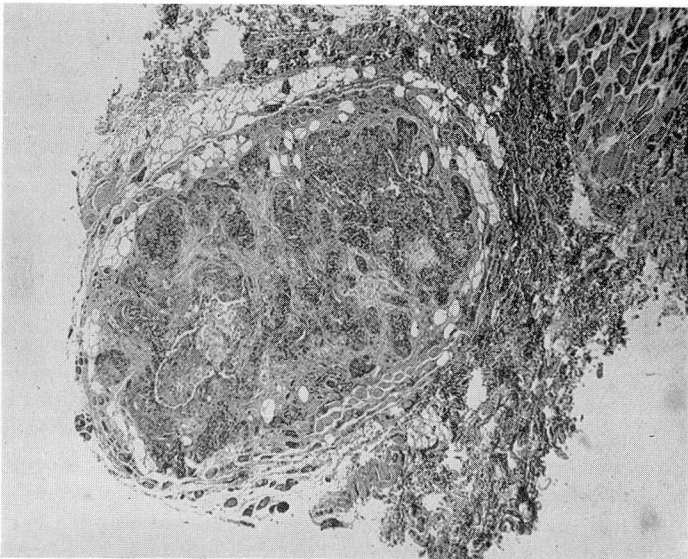


FIG. 2. Malignant mixed tumor showing fat and muscle invasion well outside main tumor (x50).

tumors. Halpert<sup>5</sup> considers them to be anlage tumors, derived from nests of embryonal ectoderm. Willis,<sup>6</sup> in describing microscopic sections in which mixed tumor and normal glandular tissue blend into each other without any visible junction, feels strongly that the tumor is of salivary gland origin. Conclusive evidence on either side is still lacking.

The most common malignancies are the carcinomas, which fall into five groups. The malignant mixed tumor (fig. 2) is characterized by the presence of malignant epithelial cells with mitotic figures superimposed on the mucinous matrix. Invasion through and beyond the fibrous capsule of the tumor is common.

Cylindromatous carcinoma (fig. 3) is composed of sheets or groups of round, regular epithelial cells arranged around hyaline masses. While nerve sheath

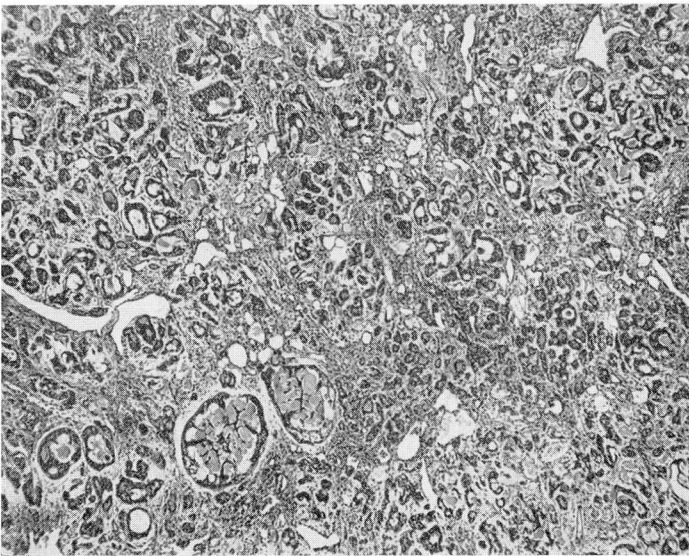


FIG. 3. Cylindromatous carcinoma showing groups of dark staining cells and hyaline masses (x50).

invasion and extension generally accompany this variety of carcinoma, there is often a latent period during which the tumor is relatively benign and curable by simple excision before rapid growth, invasion and metastases occur.

Adenocarcinomas of the parotid (fig. 4) may vary from well differentiated tumors with acini of obvious glandular origin, to anaplastic lesions in which the correct diagnosis is made only with difficulty. Squamous carcinomas are similarly variable, with microscopic pictures ranging from those with typical epithelial pearls to others showing little differentiation. Occasionally, areas of adeno or squamous carcinoma are found within an otherwise unremarkable mixed tumor. Furthermore, adeno and squamous elements may be encountered in the same lesion, with considerable variation in the amounts and degrees of

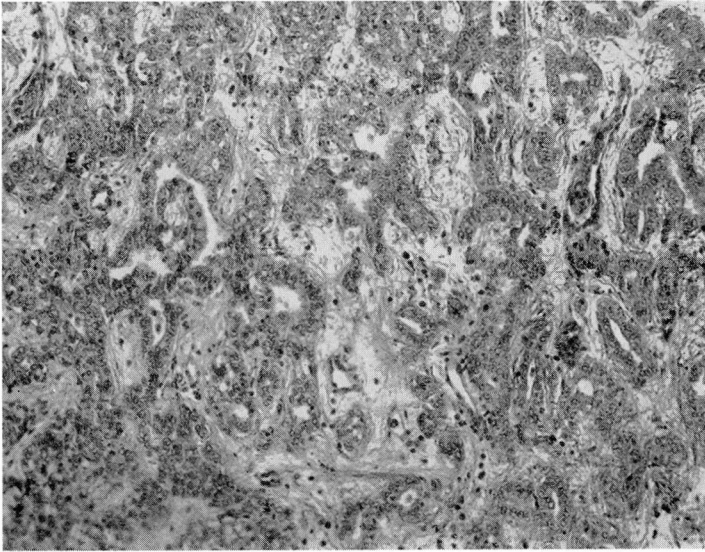


FIG. 4. Adenocarcinoma with moderate differentiation (x70).

differentiation of the components. A rather unusual member of this group is the "mucoepidermoid carcinoma" described by Stewart, Foote and Becker,<sup>7</sup> consisting of mucus-producing glandular epithelium, groups of cells of squamous type, and areas of pooled mucus (fig. 5).

Less than 5 per cent of all the parotid tumors fall into the category described first by Warthin<sup>8</sup> in 1929, and known as papillary cystadenoma lymphomatosum. The epithelial portion is papillary with prominent cystic spaces. Lymphocytic material is present, scattered irregularly throughout the lesion.

The miscellaneous group of tumors includes typical angiomas of either blood vessel or lymphatic origin, the latter sometimes being found as cystic hygroma with spaces containing typical watery material. Lipomas are rare, but come to operation from time to time with the clinical signs of mixed tumor or papillary cystadenoma lymphomatosum. Benign adenomas are not clinically distinguishable from other benign tumors, and can be diagnosed only after examination of the surgical specimen.

### Diagnosis

The patient with a benign mixed tumor usually presents a history of a painless lump in the parotid area, of several months' to many years' duration. It may vary considerably in size, sometimes growing unbelievably large without causing distress sufficient to make the patient seek treatment. Facial paralysis is never present. On examination one finds a firm, freely movable tumor, most commonly in the lower half of the gland.

The diagnosis of carcinoma is obvious if fixation of the mass, or facial

nerve paralysis, is present. Any rapid increase in size of the tumor should make one suspect a malignant lesion. This course is particularly characteristic of cylindromas, whose sudden change in size marks the start of its more malignant phase.

Papillary cystadenoma lymphomatosum (fig. 6) is characteristically soft and diffuse, with vague boundaries, and sometimes bilateral. Unfortunately, other soft tumors may present a similar picture, thus requiring further diagnostic procedures before specific therapy is undertaken.

While the biopsy is one of our soundest surgical fundamentals, its value in the diagnosis of parotid tumors is limited. However, it may be useful in the evaluation of malignant lesions, in order to plan definitive radical surgery prior to operation. In any case, since the entire biopsy field must be excised in continuity with the mass to eliminate the possibility of seeding tumor cells, any biopsy should be planned with care, and the incision placed in such position that it can be easily excised in the course of definitive surgery.

Frozen section is useful, but not necessarily conclusive, even in the hands of a most competent pathologist. If a frozen section is not unquestionably diagnostic, it is far better to utilize the primary excision of the tumor as a biopsy, following it, if necessary, with a second definitive operation when the permanent microscopic sections have been interpreted.

### Treatment

The treatment of choice for a tumor diagnosed as benign mixed tumor is early excision. Endotracheal anesthesia is used, care being taken to bring

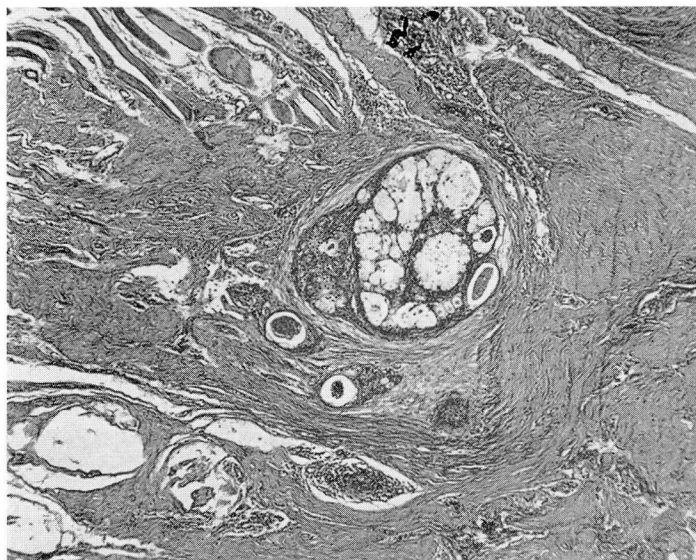


FIG. 5. Mucoepidermoid carcinoma. Note mucus-filled spaces within and outside the area of carcinoma (x50).

the airway out of the side of the mouth away from the operative field. The assistant assigned to watch the face thus has an unobstructed view of twitches resulting from facial nerve stimulation. The incision is designed to be cosmetically minimal yet provide wide exposure of the entire parotid area. It follows the anterior border of the ear, is carried back beneath the lobe, and is then extended down the neck in one of the skin creases. The lower limb of the incision may be lengthened or modified if necessary to open the entire neck for radical lymph node dissection (fig. 7).

It is not our policy to identify the main trunks of the facial nerve prior to approaching the tumor. However, in certain cases it may be useful for orientation to identify some segment of the nerve. This is most simply done by picking up its inframandibular branch at the inferior border of the gland,

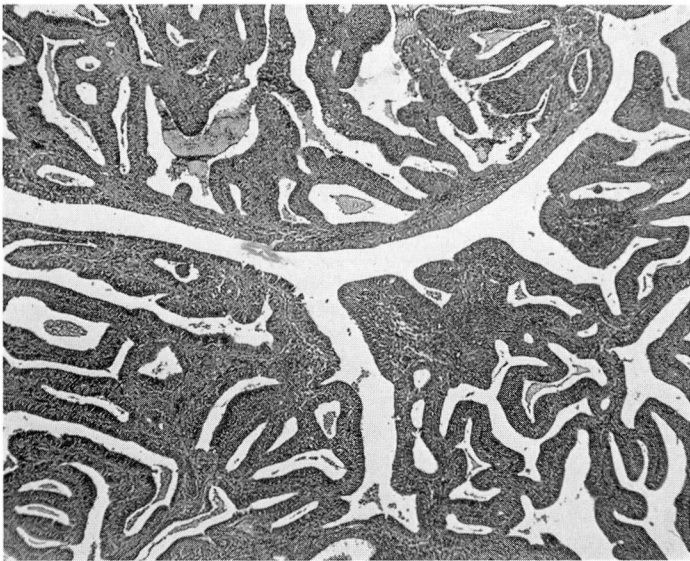


Fig. 6. Papillary cystadenoma lymphomatosum. Warthin's tumor.

where it courses downward a few millimeters anterior to the posterior facial vein. This may be followed backward without difficulty until the main nerve trunk is encountered.<sup>9</sup>

Dissection of the lesion is then carried out by carefully dividing overlying and surrounding soft tissue, while the face is watched for twitches. The attempt is made to leave a thin layer of gland tissue on the tumor; needless to say, this becomes extremely difficult as individual nerve filaments are met lying immediately on the capsule of the tumor. If the lesion is presumed benign, every effort is made to save facial nerve at the risk of leaving behind a few adherent cells. In actual practice, the incidence of recurrence under these circumstances is very low. Dissection is continued around the entire mass, using small scissors

and a fine-tipped hemostat to spread adjacent tissue. Any tissue which must be cut is first stimulated with the hemostat while the face is watched, to avoid dividing an included nerve filament. Bleeding is controlled with fine white silk ties and the operative wound irrigated gently with warm saline solution.

A small rubber band or narrow Penrose drain is placed into the parotid bed and brought out behind the ear. The defect is closed with catgut in the subcutaneous layers, and fine silk in the skin. A voluminous, carefully applied head dressing using mechanic's waste provides adequate pressure to prevent the collection of saliva and blood in the wound.

The drain is removed in 2 or 3 days. Pressure dressing must be continued until the skin flap is well attached to its bed (figs. 8 and 9).

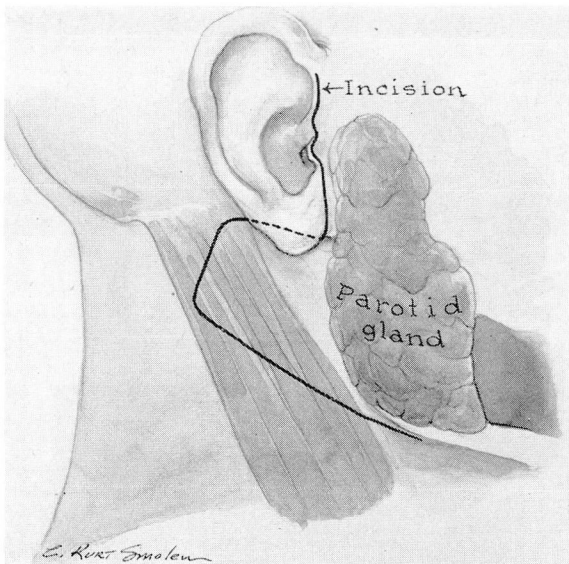


FIG. 7. Incision is designed to provide wide exposure of entire parotid area yet produce minimum cosmetic deformity.

In the case of carcinoma, the facial nerve must usually be sacrificed in the course of radical excision of the tumor. Furthermore, removal in continuity of the regional neck nodes is advisable in most cases. Certain of these malignant lesions are radiosensitive and will respond to massive doses of x-ray or interstitial radium. However, results with radiation are still inconstant and unpredictable, and radical surgery remains our best approach to the problem.

It should be emphasized to the patient who is about to lose his facial nerve that facial paralysis is not an incredible catastrophe. Excellent methods are available to repair the cosmetic deformity, using loops of fascia lata anchored to the temporalis fascia to support the corner of the mouth, upper lip and lower eyelid. It is essential that fear of facial paralysis not be allowed to stand in the way of adequate treatment of cancer.

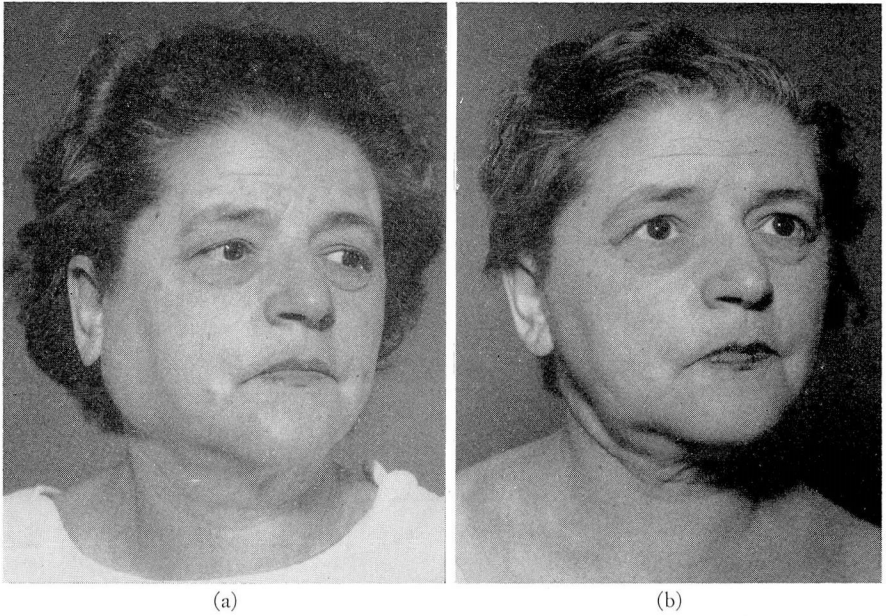


FIG. 8. (a) Patient with typical mixed tumor. Tumor is freely movable, low in parotid area, superficial, and has not involved facial nerve. (b) Same patient following excision of tumor.

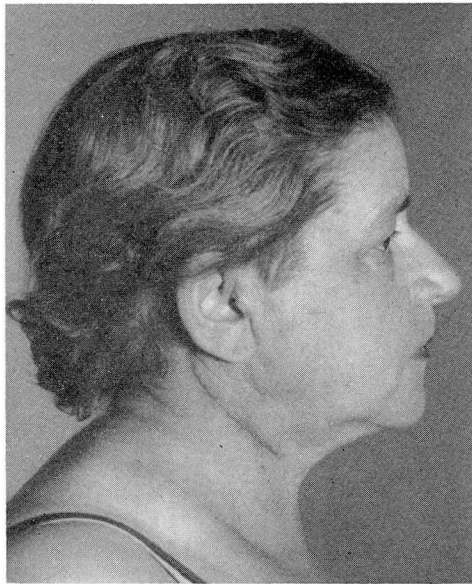

FIG. 9. Lateral view of patient in figure 8 showing scar 2 weeks after operation.

Papillary cystadenomas, if small, may be easily excised. If large and diffuse, they are best treated with small doses of x-ray, with satisfactory results.

### Results

One should expect a recurrence rate of under 5 per cent following careful excision of mixed tumors with preservation of the nerve. In the same cases, the incidence of complete facial paralysis should be zero. Occasional partial palsies may be noted in the immediate postoperative period, as the result of stretching or dividing small nerve filaments. Almost all of these are transient, however, and will disappear within a few months, leaving little or no deformity.

The results following radical surgery for carcinoma are relatively poor. While approximately half of the patients will be alive 5 years after surgery, the percentage of cases free of disease will be considerably less. It is to be hoped that early diagnosis plus more widespread use of the principle of resection in continuity of the primary cancer and its regional lymph nodes will improve the prognosis in these individuals.

Table 1

1. Benign mixed tumor (66.7 per cent)
2. Carcinoma (22.6 per cent)
  - a. Malignant mixed tumor
  - b. Cyndromatous carcinoma
  - c. Adenocarcinoma
  - d. Squamous cell carcinoma
  - e. Mucoepidermoid carcinoma
3. Papillary cystadenoma lymphomatosum (3.4 per cent)
4. Miscellaneous (7.3 per cent)
  - a. Angioma
  - b. Lipoma
  - c. Adenoma

### Summary

1. A pathologic classification of tumors of the parotid gland has been presented.
2. The diagnosis and treatment of these tumors have been discussed and the expected results summarized.

### References

1. Bailey, H.: Treatment of tumors of parotid gland, with special reference to total parotidectomy. *Brit. J. Surg.* **28**:337 (Jan.) 1941.
2. Brown, J. B., McDowell, F. and Fryer, M. P.: Direct operative removal of benign mixed tumors of anlage origin in parotid region. *Surg., Gynec. and Obst.* **90**:257 (March) 1950.

3. Kirklin, J. W., McDonald, J. R., Harrington, S. W. and New, G. B.: Parotid tumors; histopathology, clinical behavior, and end results. *Surg., Gynec. and Obst.* **92**:721 (June) 1951.
4. McCormack, L. J., Cauldwell, E. W. and Anson, B. J.: Surgical anatomy of facial nerve with special reference to parotid gland. *Surg., Gynec. and Obst.* **80**:620 (June) 1945.
5. Halpert, B.: Salivary gland tumors, adamantinomas and craniopharyngiomas; anlage tumors. *Cancer Research* **6**:504 (Sept.) 1946.
6. Willis, R. A.: *Pathology of Tumors*. St. Louis, C. V. Mosby Co., 1948.
7. Stewart, F. W., Foote, F. W. and Becker, W. F.: Muco-epidermoid tumors of salivary glands. *Ann. Surg.* **122**:820 (Nov.) 1945.
8. Warthin, A. S.: Papillary cystadenoma lymphomatosum; rare teratoid of parotid region. *Cancer Research* **13**:116 (July) 1929.
9. Byars, L. T.: (In press).